

# Role of MR Imaging in Diagnosis of Knee Intra and Peri-Articular Masses

Asmaa Y. Elsaid, Rania F. Abo Elfotoh, Hamada M. Khater

Department of Radiology,  
Faculty of Medicine; Benha  
University. Egypt.

**Correspondence to:** Rania  
F. Abo Elfotoh, Department of  
Ophthalmology Faculty of  
Medicine; Benha University.  
Egypt.

**Email:**

raniamada1212@gmail.com

**Received:** 7 November 2024

**Accepted:** 30 November 2024

## Abstract

**Background:** Intra-articular and peri-articular knee masses encompass a variety of non-infectious, infectious, vascular, neoplastic, and miscellaneous lesions. Magnetic resonance imaging (MRI) is a non-invasive gold standard for evaluating knee lesions, offering high-resolution visualization of soft tissues and bone structures. **Aim of the work:** This study aims to evaluate the role of MRI in evaluation of knee intra and peri-articular masses. **Subjects and methods:** A total of 50 patients (mean age:  $37.1 \pm 17.7$  years; 64% males) presenting with knee swelling, pain, or limited movement were referred for MRI evaluation. Standard MRI protocols, including sagittal, coronal, and axial views, were used. Diagnosis was confirmed via pathology and arthroscopy. **Result:** MRI diagnosed 46 out of 50 cases, with an overall sensitivity of 92%. Sensitivity varied by lesion type: non-infectious lesions (94.7%), infectious (75%), vascular (50%), neoplastic (80%), and miscellaneous (95%). MRI accurately diagnosed all cases of synovial osteochondromatosis and lipoma arborescens but misclassified some cases, such as TB arthritis and synovial hemangioma. **Conclusion:** MRI is highly sensitive for diagnosing knee intra- and peri-articular masses, particularly non-infectious and miscellaneous lesions. However, caution is warranted when diagnosing certain infectious and vascular lesions, where accuracy is lower.

**Keywords:** MR Imaging; Knee Intra Masses; Peri-Articular Masses.

## Introduction:

Intra-articular and peri-articular knee masses can be classified as non-infectious synovial proliferative processes (lipoma arborescence, synovial osteochondromatosis, pigmented villonodular synovitis, rheumatoid arthritis), infectious

granulomatous diseases (tuberculous arthritis, coccidioidomycosis arthritis), deposition diseases (gout, amyloid arthropathy), vascular malformations (synovial hemangioma, arteriovenous malformations), malignancies (synovial chondrosarcoma, synovial sarcoma,

synovial metastases), and miscellaneous (cyclops lesion) <sup>(1)</sup>.

Knowledge of articular anatomy aids the radiologist in localizing masses to joint space. The diagnostic approach of these lesions must be performed systematically. First, the lesion must be precisely located, and then the anatomical structure involved must be determined. Finally, clinical background that includes the age of the patient, frequency of the disease and, if any associated signs as well as MRI characteristics must be analyzed <sup>(2)</sup>.

Tumors and tumor-like lesions of the knee are mostly conditions. Because the synovial membrane covers a large part of the knee. Tumors and tumor-like lesions of the knee are mostly synovial <sup>(3)</sup>. Articular and peri-articular tumors represent one of the most common manifestations of a wide variety of neoplastic (both benign and malignant) and non-neoplastic lesions. The differential diagnosis is wide and the clinical diagnosis is complicated because most lesions present as chronic monoarthritis or with non-specific laboratory findings. Many of the diseases causing intra-articular masses have specific imaging characteristics, especially on magnetic resonance images, and knowledge of the characteristics will allow for more confident diagnosis <sup>(4)</sup>.

Conventional radiographic image analysis is the first step in the diagnostic work-up, and in most cases with knee problems. Radiography is still considered as the easiest and most cost-effective radiological modality for

diagnosing and follow-up of knee pathology as osteoarthritis <sup>(5)</sup>.

Magnetic resonance imaging (MRI) is recognized as the gold standard in characterizing lesions around the knee because of its ability to affords high-resolution visualization of the soft tissue structures (menisci, ligaments, cartilage, etc) and identify associated intra-articular knee pathology and bone marrow changes <sup>(6)</sup>.

Magnetic resonance imaging (MRI), with its multiplanar capabilities and excellent soft-tissue contrast, has established itself as the leading modality for noninvasive evaluation of the musculoskeletal system. It is regarded as the top imaging and diagnostic tool for the knee joint because of its ability to evaluate a wide range of anatomy and pathology varying from ligamentous injuries to articular cartilage lesion <sup>(7)</sup>.

Complete assessment of the knee requires that images be obtained in the sagittal, coronal and axial planes. T2-weighted images using either fast spin echo techniques with fat saturation or short time inversion recovery (STIR) imaging are typically performed in all 3 imaging planes. The T2-weighted pulse sequences have been referred to as the "pathology" sequences and are best suited for detecting injuries of the muscles, tendons, ligaments, articular cartilage and depiction of cystic lesions around knee and their origin. They also clearly depict marrow abnormalities such as edema or contusion <sup>(8)</sup>.

The aim of the study is to evaluate the role of MRI in evaluation of knee intra and peri-articular masses.

### **Patients and methods:**

**Study design:** cross sectional study .

**Study Period:** from the start of November 2023 to the end of October 2024.

**Study setting:** Radiology Department at Al Bank El-Ahly Hospital or Nile Scan Center for evaluation.

**Study population:** 50 patients who were presented with knee swelling, pain, or limitation of movement. Informed written consent was obtained from all patients, who were fully briefed on the purpose of the study and assigned a confidential code number. The study was approved by the Research Ethics Committee, Faculty of Medicine, Benha University, Approval was also obtained from the Institutional Review Board (IRB) before the study began. In the case of children included in the study, written consent was obtained from their first-degree relatives. The study was further approved by the local Research Ethics Committee (Benha Faculty of Medicine Research Ethics Committee, approval number: M.S. 32.9.2032.

**Inclusion criteria** were patients with knee pain, swelling or limitation of movement.

**Exclusion criteria** where contraindications to MRI include pacemaker, claustrophobia, metal prosthesis, aneurysmal clips, history of

allergic reaction to iodinated contrast agent, and renal insufficiency if contrast study is indicated.

### **Methods:**

All studied cases were subjected to the following: Detailed history taking, including [Personal history; name, age, gender, past medical history, past surgical history, and history of sensitivity to drugs. Full clinical examination: General examination including [Vital signs (Blood pressure, Temperature, Heart rate, Respiratory rate), signs of (Pallor, Cyanosis, Jaundice, and Lymph node enlargement)]. Local examination: [Inspection: Skin, for scar or sinuses, swellings, muscle atrophy and shape and symmetry. Palpation: Determination of the point, of maximum tenderness and assessment of movements (active, and passive)]. Routine laboratory investigations [Complete blood count (CBC), Erythrocyte sedimentation rate, C-reactive protein, Liver and kidney functions, and PT, PTT and INR]. Radiological investigation: [MRI Technique]

### **MRI Acquisition**

The MRI sequences included sagittal proton density fat-saturated turbo spin echo (TR/TE, 2500/18 ms) and sagittal and coronal T2-weighted (4000/85 ms) fat-saturated turbo spin-echo; coronal T1-weighted (400/13 ms) spin-echo and axial proton density fat-saturated turbo spin echo (2880/17 ms). The section thickness was 4 mm with an intersection gap of 0.4 mm; field of

view was  $150 \times 150$  mm and matrix 512 in all sequences.

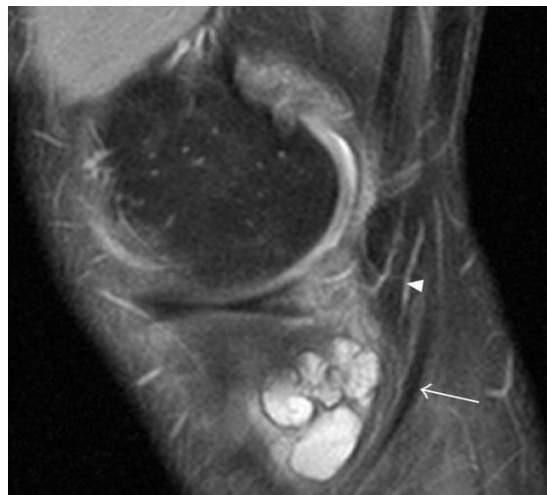### MRI Assessment

The same experienced musculoskeletal radiologist (NE) evaluated each of the MRI examinations. The presence of fluid accumulations of the following bursae and synovial recesses were evaluated: semimembranosus-gastrocnemius (Popliteal cyst—**Figure 1**), medial and lateral sub gastrocnemius, prepatellar, superficial, and deep infrapatellar, medial (MCL), and lateral (LCL) collateral ligament, biceps femoris, iliotibial, anserine, and semimembranosus-gracilis bursitides and Hoffa's fat pad recesses (**Figure 2**). Other cyst-like lesions included meniscal cysts, ganglion cysts of the cruciate ligaments, and extracapsular synovial cysts.

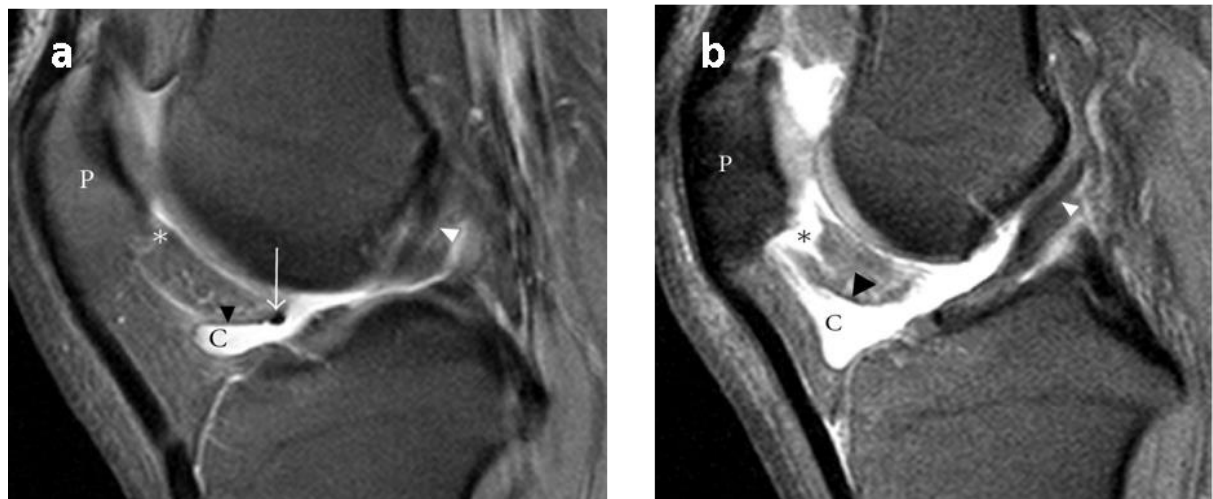
Two types of fluid collections along the popliteus tendon (PT) were

distinguished: cystic lesions originating from the proximal tibiofibular joint and the PT recesses. Insertional cysts were assessed at the cruciate and collateral ligaments. The presence or absence (0 = none, 1 = present) of cystic lesions was registered and the length of fluid collections in the PT recess was measured in mm from the upper demarcation line of the proximal tibiofibular joint and distally.

Knee joint effusion was registered (0 = none, 1 = present) as the presence of a localized fluid collection in the intercondylar area, in the medial or lateral recess, or as a generalized fluid collection that distended the suprapatellar recess. Abnormalities in the MR signal intensities predicting meniscal tears were classified in grades 1–3 and radiographic knee OA were classified using a modified Ahlbäck scale of joint space narrowing (JSN).



**Figure 1:** Pes anserine bursitis. Sagittal proton density fat-saturated image of the medial aspect of the left knee in a 47-year-old male floor layer. Arrow, semitendinosus tendon; arrowhead, semimembranosus tendon.



**Figure 2:** Fluid filled synovial clefts of Hoffa's fat pad in the knees of 2 floor layers. In these sagittal proton density fat-saturated images of the right knee in a 43-year-old male floor layers with mild (a) and a 50-year-old male floor layer with moderate (b) Effusion of the inferior, horizontal Hoffa's cleft there is a communication with the superior cleft (\*) along the ligamentum mucosum (black arrowhead). Arrow, anterior transverse ligament; white arrowhead, anterior cruciate ligament; P, patella.

### Data management and statistical analysis: -

The collected data were statistically presented and analyzed using the Statistical Package for Social Science (SPSS), version 20.0 for Windows (IBM SPSS Inc, Chicago, IL, USA). Categorical data were expressed as number and percentage, continuous data were expressed as mean and standard deviation. Suitable tests of significance were used. The accepted level of significance in this study was 0.05

### Results

This study was carried on 50 patients who complaining of knee swelling, pain or limitation of movement. The mean age of the group was  $37.1 \pm 17.7$  years with males (64%) more common than females (36%).

#### Table 1

The causes of intra and peri-articular lesions of the knee in our study were classified to non-infectious synovial proliferative processes, infectious causes, vascular causes, neoplastic causes either malignant or benign and miscellaneous causes and the most common causes were non-infectious and miscellaneous. In our study, the non-infectious knee lesions included PVNS, synovial osteochondromatosis, lipoma arborescens and rheumatoid arthritis. The infectious lesions included TB, septic arthritis and Brodie's abscess. The vascular lesions were synovial hemangioma and venous malformation. The malignant lesions included paraosteal osteosarcoma, lymphoma and metastasis. The benign tumors were osteochondroma, enchondroma and giant cell tumor. The miscellaneous include hemoarthrosis, backer cyst, cyclops, transient synovitis, ganglion and bursae.

venous malformation cases but for synovial hemangioma, MRI diagnosed it as PVNS. Thus, MRI sensitivity in diagnosis of vascular knee lesions in our study was 50%.

**Table 2**

Regarding to pathology and arthroscopy, MRI could diagnose 46 of 50 cases. So, MRI sensitivity in diagnosis of knee lesions in our study was 92%. MRI could diagnose 4 cases of 5 cases of PVNS and missed one case which was diagnosed as synovitis. Also, MRI could diagnose one case of two rheumatoid arthritis cases and the second case MRI diagnosed it as septic arthritis. MRI could diagnose all cases of synovial osteochondromatosis and lipoma arborescence.

So, MRI sensitivity in diagnosis of non-infectious knee lesions in our study was 94.7%. In infectious causes, MRI could diagnose it all except TB arthritis which was diagnosed as rheumatoid arthritis. Therefore, in our study, MRI sensitivity in diagnosis of infectious knee lesions was 75 %. In vascular causes, MRI could diagnose

**Table 3**

In neoplastic causes, MRI diagnosed all benign cases but for malignant cases, it diagnosed paraosteal osteosarcoma but for lymphoma, MRI gave DD of sarcoma versus lymphoma versus metastasis. For that, MRI sensitivity in diagnosis of neoplastic knee lesions in our study was 80 %. In miscellaneous causes, MRI diagnosed all cases (cyclops, ganglion, bursae, hemoarthrosis, backer cyst and transient synovitis) except one case of cyclops and one case of transient synovitis which were missed on MRI. Accordingly, MRI sensitivity in diagnosis of miscellaneous knee lesions in our study was 95. **Table 4**

**Table 1:** Demographic data of the studied patients

Item	Frequency(no=●)	Percentage
<b>Gender</b>		
- Males	32	<b>64</b>
- Females	18	<b>36</b>
<b>Age (yrs)</b>		
- Mean ± SD	<b>37.1±17.7</b>	
- Min- max	<b>4-67</b>	

**Table 2:** Knee lesions distribution and Categorization among the studied patients by MRI

<b>Knee lesions distribution</b>	<b>Frequency(no=50)</b>	<b>Percentage</b>
<b>Diagnosis</b>		
- Noninfectious	19	38
- Infection	4	9
- Vascular	2	3
- Neoplastic	5	9
- Miscellaneous	20	41
<b>Categorization of different knee lesions</b>		
<b>Non-infectious (No=19)</b>		
- PVNS	5	26.3
- Synovial osteochondromatosis	7	36.8
- Lipoma arborescens	6	31.6
- Rheumatoid arthritis	1	5.3
<b>Infectious diseases (no=4)</b>		
- T.B	0	0
- Septic arthritis	2	50
- Brodie's abscess	2	50
<b>Vascular (no=2)</b>		
- Hemangioma	1	50
- Venous malformation	1	50
<b>Neoplastic (no=5)</b>		
<b>Malignant tumors (no=2)</b>		
- Paraosteal osteosarcoma	0	0
- Mxyoid synovial liposarcoma	1	20
- Lymphoma	1	20
<b>Benign tumors (no=3)</b>		
- Fibrous dysplasia	0	0
- Chondroblastoma	1	20
- Osteoid osteoma	1	20
- Paget's disease	1	20
<b>Miscellaneous (no=20)</b>		
- Cyclops	4	20
- Bursal lesions & ganglion cysts	11	55
- Hemoarthrosis	2	10
- Morel Lavelle	1	5
- Transient synovitis	2	10

**Table 3:** MRI in relation to pathology and arthroscopy in diagnosis of knee lesions, non-infectious knee lesions, infectious knee lesions and vascular knee lesions.

<b>Diagnosis of knee lesions</b>	<b>Number</b>	<b>Percentage</b>
<b>MRI</b>	46	<b>92</b>
<b>Pathology and arthroscopy</b>	50	<b>100</b>
<b>Diagnosis of non- infectious knee lesions</b>		
<b>MRI</b>	18	<b>94.7</b>
<b>Pathology and arthroscopy</b>	19	<b>100</b>
<b>Diagnosis of infectious knee lesions</b>		
<b>MRI</b>	3	<b>75</b>
<b>Pathology and arthroscopy</b>	4	<b>100</b>
<b>Diagnosis of vascular knee lesions</b>		
<b>MRI</b>	1	<b>50</b>
<b>Pathology and arthroscopy</b>	2	<b>100</b>

**Table 4:** MRI in relation to pathology and arthroscopy in diagnosis of knee lesions neoplastic knee lesions and miscellaneous knee lesions

<b>Diagnosis of knee lesions</b>	<b>Number</b>	<b>Percentage</b>
<b>Diagnosis of neoplastic knee lesions</b>		
<b>MRI</b>	4	<b>80</b>
<b>Pathology and arthroscopy</b>	5	<b>100</b>
<b>Diagnosis of miscellaneous knee lesions</b>		
<b>MRI</b>	19	<b>95</b>
<b>Pathology and arthroscopy</b>	20	<b>100</b>

## Discussion

This study included 50 patients; the mean age of the group was  $37.1 \pm 17.7$  years with males (64%) more common than females (36%).

In concordance with Yadav & Kachewar <sup>(9)</sup> who aimed to evaluate how MRI can evaluate painful knee, their study conducted 50 consecutive patients who were referred for MRI



evaluation of painful knee were included in this study, specific findings that explained the cause of pain were compiled. They reported that 50 patients, and 18 were females (36%) and 32 were males (64%), the mean age was  $37.1 \pm 17.7$  years<sup>(9)</sup>.

Regarding to Knee lesions distribution among the studied patients by MRI, our results showed that the causes of intra and peri-articular lesions of the knee in our study were classified to non-infectious synovial proliferative processes, infectious causes, vascular causes, neoplastic causes either malignant or benign and miscellaneous causes and the most common causes were non-infectious and miscellaneous.

Categorization of different knee lesions by MRI in the studied patients, our results showed that the non-infectious knee lesions included PVNS, synovial osteochondromatosis, lipoma arborescens and rheumatoid arthritis. The infectious lesions included TB, septic arthritis and Brodie's abscess. The vascular lesions were synovial hemangioma and venous malformation. The malignant lesions included paraosteal osteosarcoma and metastasis. The benign tumors were osteochondroma, enchondroma, giant cell tumour. The miscellaneous included hemoarthrosis, Baker cyst, cyclops, transient synovitis, ganglion and bursae.

In agreement with Nadim & Samet<sup>(10)</sup> who aimed to assess MRI in relation to pathology and arthroscopy in diagnosis of noninfectious knee lesions, they showed that MRI was diagnosed in

MRI was diagnosed all cases of synovitis<sup>(10)</sup>.

Regarding to pathology and arthroscopy in diagnosis of knee lesions, MRI was diagnosed in 46 of 50 cases. So, MRI sensitivity in diagnosis of knee lesions in our study was 92%.

In agreement with our results, Mohey & Hassan<sup>(4)</sup> who aimed to correlate the results of MRI with arthroscopy in characterization of different varieties of intra-articular synovial masses and mass-like lesions. They showed that the concordance of MRI in relation to the gold standard (arthroscopy) was 91.7% sensitivity<sup>(4)</sup>.

In agreement with Figueroa & colleagues<sup>(11)</sup> who reported that MRI showed a sensitivity of 45% for detecting chondral lesions, with a specificity of 100%, having its best accuracy with patellar defects and was also correlated with the grade of the lesion according to International Cartilage Repair Society (ICRS) classification<sup>(11)</sup>.

The relatively low sensitivity exhibited by MRI in this study can be attributed to different causes for example was used 1.5-Tesla MRI machine, higher strength fields (3-Tesla) can increase MRI accuracy on detecting knee chondral lesions. Newer, more-specific MRI sequences and the use of contrast fluid can also improve the diagnostic accuracy of this test by Eckstein and co-workers<sup>(12)</sup>.

Regarding to MRI in relation to pathology and arthroscopy in diagnosis of non-infectious knee lesions. MRI

could diagnose 4 cases of 5 cases of PVNS and missed one case which was diagnosed as synovitis. Also, MRI could diagnose one case of two rheumatoid arthritis cases and the second case MRI diagnosed it as septic arthritis. MRI could diagnose all cases of synovial osteochondromatosis and lipoma arborescence. So, MRI sensitivity in diagnosis of non-infectious knee lesions in our study was 94.7%.

In the same line Dhanda & researchers<sup>(13)</sup> demonstrated that PVNL was localized or diffuse. When the entire synovium of the joint was affected and there was a major villous component, the condition was referred to as diffuse pigmented villonodular synovitis. Presence of a discrete intra-articular mass was called localized pigmented villonodular synovitis. On MRI, the lesion was hypointense on T1-weighted (T1W) and hyperintense on T2-weighted (T2W) images and demonstrates multilobulation and marked heterogeneity (creating the “triple sign”) with haemorrhage, fluid levels and septa (creating the “bowl of grapes” sign)<sup>(13)</sup>.

Also, agreed with Dhanda & researchers<sup>(13)</sup> who aimed to equip the reader with a pragmatic approach to imaging of patients presenting with suspected tumor-like swelling in and around joints. They reported that PVNL can be localized or diffuse. When the entire synovium of the joint is affected and there is a major villous component, the condition is referred to as diffuse pigmented villonodular synovitis. Presence of a discrete intra-

articular mass is called localized pigmented villonodular synovitis<sup>(13)</sup>.

Concerning to MRI in relation to pathology and arthroscopy in diagnosis of infectious knee lesions. In infectious causes, MRI could diagnose it all except TB arthritis which was diagnosed as rheumatoid arthritis. Therefore, in our study, MRI sensitivity in diagnosis of infectious knee lesions was 90%.

In supporting with our results Evenski and colleagues<sup>(14)</sup>, study MRI in diagnosing in the same line with positive predictive value, negative predictive value and diagnostic accuracy of MRI in detecting medial meniscus pathologies were 92.6%<sup>(14)</sup>.

Also, agreed with Voss & co-workers<sup>(15)</sup> showed that infection rate is between 0.1 and 1.8%, in infectious causes, MRI was diagnosed with it all except TB arthritis. MRI sensitivity in diagnosis of infectious knee lesions was 79%<sup>(15)</sup>.

Regarding to MRI in relation to pathology and arthroscopy in diagnosis of vascular knee lesions, our results revealed that in vascular causes, MRI could diagnose venous malformation cases but for synovial hemangioma, MRI diagnosed it as PVNS. Thus, MRI sensitivity in diagnosis of vascular knee lesions in our study was 80%.

In accordance with our results Pourbagher & colleagues<sup>(16)</sup> showed that the MRI sensitivity in vascular knee lesions was 79%. MRI is the most valuable means of diagnosing deep soft-tissue haemangiomas<sup>(16)</sup>.

As well, agreed with Gaetke-Udager & other researchers <sup>(17)</sup> who aimed to evaluate knee MRI for presumed musculoskeletal disease can have unexpected vascular findings or pathology in the imaged field. Some vascular processes are limb threatening and affect treatment planning and patient outcome. They showed that MRI was diagnosed venous malformation cases, incidental vascular findings on knee MRI can have major clinical implications. Variant anatomy can place patients at increased risk of injury during common surgical procedures such as knee arthroscopy and knee arthroplasty. Vascular pathology can include trauma, aneurysm, thrombosis, vascular malformation, and neoplasm <sup>(17)</sup>.

Concerning to MRI in relation to pathology and arthroscopy in diagnosis of neoplastic knee lesions, our results showed that in neoplastic causes, MRI diagnosed all benign cases but for malignant cases, it diagnosed paraosteal osteosarcoma but for lymphoma, MRI gave DD of sarcoma versus lymphoma versus metastasis. For that, MRI sensitivity in diagnosis of neoplastic knee lesions in our study was 100%.

Supporting our results is Dhanda & co-workers <sup>(13)</sup> who aimed to evaluate Intra-articular and peri-articular tumours, equip the reader with a pragmatic approach to imaging of patients presenting with suspected tumour-like swelling in and around joints, they showed that the sensitivity for MRI in neoplastic knee lesions was 88.2% <sup>(13)</sup>.

In accordance with our results are Woltsche and co-workers <sup>(18)</sup> who aimed to assess prevalence and characteristics of benign cartilaginous tumors of the knee joint as identified on MRI scans, they reported that MRI diagnosed all benign cases patients. MRI scans of either knee joint, a benign cartilaginous lesion was detected incidentally. In 17 of these patients, two lesions in the same knee were found. In additional 4 patients, a cartilaginous lesion was found both in the left and right knee, amounting to 672 tumors in total <sup>(18)</sup>.

Regarding to MRI in relation to pathology and arthroscopy in diagnosis of miscellaneous knee lesions, our results revealed that in miscellaneous causes, MRI diagnosed all cases (cyclops, ganglion, bursae, hemoarthrosis, Morel Lavelle and transient synovitis) except one case of cyclops and one case of transient synovitis which were missed on MRI. Accordingly, MRI sensitivity in diagnosis of miscellaneous knee lesions in our study was 95%.

In agreement with us is Maheshwari and colleagues' <sup>(19)</sup> study which used Magnetic resonance imaging (MRI) for recognized as the imaging modality of choice for the assessment of chronic internal derangements of the knee, they showed that MRI diagnosed all cases cyclops and ganglion <sup>(19)</sup>.

Basha and the colleagues <sup>(20)</sup> who aimed to diagnostic accuracy of MRI as a fast-imaging technique in assessment of patients with anterior knee pain (AKP), agreed with us. They

showed that MRI reported 11 different findings of possible causes of AKP or related to it, MRI sensitivity in diagnosis of knee lesion was good <sup>(20)</sup>.

This study has some limitations as the relatively small sample size, which may limit the generalizability of the findings. Additionally, MRI misclassified certain infectious and vascular lesions, highlighting the need for further research with advanced imaging techniques to improve diagnostic accuracy in these areas.

## Conclusion

MRI proved to be a valuable tool for diagnosing knee intra- and peri-articular masses, demonstrating high sensitivity, particularly in non-infectious and miscellaneous lesions. However, its diagnostic accuracy was lower for certain infectious and vascular lesions, emphasizing the importance of integrating clinical context and alternative diagnostic methods.

## References

1. **Aghdam YH, Moradi A, Großterlinden LG, Jafari MS, Heverhagen JT, Daneshvar K.** Accuracy of magnetic resonance imaging in assessing knee cartilage changes over time in patients with osteoarthritis: A systematic review. *North Clin Istanbul*. 2022;9:414-8.
2. **Chien A, Weaver JS, Kinne E, Omar I.** Magnetic resonance imaging of the knee. *Pol J Radiol*. 2020;85:e509-e31.
3. **Larbi A, Viala P, Cyteval C, Snene F, Greffier J, Faruch M, et al.** Imaging of tumors and tumor-like lesions of the knee. *Diagn Interv Imaging*. 2016;97:767-77.
4. **Mohey N, Hassan TA.** Feasibility of MRI in diagnosis and characterization of intra-articular synovial masses and mass-like lesions. *EJRN*. 2020;51:19.
5. **Roemer FW, Eckstein F, Hayashi D, Guermazi A.** The role of imaging in osteoarthritis. *Best Pract Res Clin Rheumatol*. 2014;28:31-60.
6. **Singh S, Bray TJP, Hall-Craggs MA.** Quantifying bone structure, micro-architecture, and pathophysiology with MRI. *Clin Radiol*. 2018;73:221-30.
7. **Gulani V, Calamante F, Shellock FG, Kanal E, Reeder SB.** Gadolinium deposition in the brain: summary of evidence and recommendations. *Lancet Neurol*. 2017;16:564-70.
8. **Wick MC, Kastlunger M, Weiss RJ.** Clinical imaging assessments of knee osteoarthritis in the elderly: a mini-review. *Gerontology*. 2014;60:386-94.
9. **Yadav, R., & Kachewar, S. G.** Role of MRI in evaluation of painful knee. *International Journal of Medical Research & Health Sciences*, 2014; 3(1), 84-87.
10. **Nadim B, Samet JD.** Pediatric solid intra-articular masses of the knee: prevalence, imaging features and etiologies. *Pediatr Radiol*. 2021;51:1412-20.
11. **Figuerola D, Calvo R, Vaisman A, Carrasco MA, Moraga C, Delgado I.** Knee chondral lesions: incidence and correlation between arthroscopic and magnetic resonance findings. *Arthroscopy*. 2007;23:312-5.
12. **Eckstein F, Charles HC, Buck RJ, Kraus VB, Remmers AE, Hudelmaier M, et al.** Accuracy and precision of quantitative assessment of cartilage morphology by magnetic resonance imaging at 3.0T. *Arthritis Rheum*. 2005;52:3132-6.
13. **Dhanda S, Quek ST, Bathla G, Jagmohan P.** Intra-articular and Peri-

- articular Tumours and Tumour Mimics- What a Clinician and Onco-imaging Radiologist Should Know. *Malays J Med Sci.* 2014;21:4-19.
14. **Evenski AJ, Stensby JD, Rosas S, Emory CL.** Diagnostic imaging and management of common intra-articular and peri-articular soft tissue tumors and tumorlike conditions of the knee. *J Knee Surg.* 2019;32(04):322–30.
  15. **Voss A, Pfeifer CG, Kerschbaum M, Rupp M, Angele P, Alt V.** Post-operative septic arthritis after arthroscopy: modern diagnostic and therapeutic concepts. *Knee Surg Sports Traumatol Arthrosc.* 2021;29:3149-58.
  16. **Pourbagher A, Pourbagher MA, Karan B, Ozkoc G.** MRI manifestations of soft-tissue haemangiomas and accompanying reactive bone changes. *Br J Radiol.* 2011;84:1100-8.
  17. **Gaetke-Udager K, Fessell DP, Liu PS, Morag Y, Brigido MK, Yablon C, et al.** Knee MRI: Vascular Pathology. *AJR Am J Roentgenol.* 2015;205:142-9.
  18. **Woltsche JN, Smolle MA, Szolar D, Bergovec M, Leithner A.** Prevalence and characteristics of benign cartilaginous tumours of the knee joint as identified on MRI scans. *Cancer Imaging.* 2023;23:50.
  19. **Maheshwari M, Yadav PK, Jain S, Batham IK, Gupta A, Swaika S.** Imaging of Knee Joint Pathologies: A Comparative Study of Ultrasound and Magnetic Resonance Imaging. *J Med Sci.* 2022;8(3):2228.
  20. **Basha MAA, Eldib DB, Aly SA, Azmy TM, Mahmoud NEM, Ghandour TM, et al.** Diagnostic accuracy of ultrasonography in the assessment of anterior knee pain. *Insights Imaging.* 2020;11:107.

**To cite this article:** Asmaa Y. Elsaid, Rania F. Abo Elfotoh, Hamada M. Khater. Role of MR Imaging in Diagnosis of Knee Intra and Peri-Articular Masses. *BMFJ* 2025;42(6):64-76.