

Magnetic Resonance Cholangiopancreatography: Diagnostic Role in Evaluating Pancreaticobiliary Abnormalities

Medhat M. Refaat^a, Manal A. ElRefaei^b, Mohammad A. Moustafa^a

Abstract:

Background: Accurate methods of detecting pancreaticobiliary diseases for planning an effective management reveal a real need for less invasive and highly sensitive diagnostic procedure. **Aim:** highlighting the MRCP role in evaluating pancreaticobiliary abnormalities. **Methods:** The present study included sixty participants; a study group (42 symptomatic patients) and a control group (18 normal volunteers)- investigated with MRCP at Al-Ahrar teaching hospital, Sharkia, from June 2022 to April 2023. **Results:** We detected 90.48% of the symptomatic patients having peripheral bile tracts dilatation, where 88.1%, 90.48 and 78.57% had RHD, LHD and CHD dilatation respectively; with 73.81% had CBD dilatation. 33.33% had cholelithiasis whereas 19% showed cholecystitis, 30.95% had CBD stones with 7.14% had inserted CBD stents due to biliary stones whereas 38.1% of patients had neoplastic entities. In comparison to ERCP as a gold standard, MRCP- as regards the diagnosis of biliary stones- shows 100% sensitivity, 94.74% specificity, 92.31% PPV, 100% NPV with an overall diagnostic accuracy of 96.77%. Whereas, MRCP gave for the diagnosis of benign biliary strictures 85.71% sensitivity, 100% specificity, 100% PPV, 94.74% NPV with an overall accuracy of 96%. **Conclusion:** MRCP is a noninvasive diagnostic tool with a pivotal diagnostic role of pancreaticobiliary disorders.

Key words: MRCP, CBD, GB.

Abbreviations: MRCP: Magnetic resonance cholangiopancreatography, MRI: Magnetic resonance, DWI: Diffusion weighted imaging, SI: signal intensity, T1WI: T1 weighted image, T2WI: T2 weighted image, GB: gall bladder, CBD: common bile duct, CHD: common hepatic duct, RHD: right hepatic duct, LHD: left hepatic duct, IHBRD: intrahepatic biliary radicles dilatation, PD: pancreatic duct.

^a Radiodiagnosis Department,
Faculty of Medicine Benha
University, Egypt.

^b Radiodiagnosis Department,
Al Ahrar teaching hospital,
Egypt.

Corresponding to:
Dr. Mohammad A. Moustafa.
Radiodiagnosis Department,
Faculty of Medicine Benha
University, Egypt.
Email: dr.mazezo@gmail.com

Received:

Accepted:

Introduction

Non-invasive techniques such as ultrasound and CT scan are widely used in preliminary investigations of pancreaticobiliary diseases- though easily available and less expensive- have limitations in term of sensitivity such as low sensitivity of USG for detecting common duct calculi ⁽¹⁾.

Magnetic resonance imaging (MRI) with the use of Magnetic resonance cholangiopancreatography (MRCP)- has become widely accepted as the most accurate, non-invasive method for assessment of the biliary system and also of the pancreatic gland and duct in one examination ^(2,3).

MRCP is applied to minimize the need for the invasive ERCP to intervention therapeutic needs only, like; sphincterotomy, biopsy, ductal stones extraction, stenting and stricture dilatation. It had a proven high sensitivity and specificity in the evaluation of various conditions of the pancreaticobiliary ductal system, e.g. diagnosis congenital anomalies of the biliary or pancreatic ducts like; pancreatic divisum, post-surgical complications like; choledocholithiasis, different patterns of biliary strictures, chronic pancreatitis, paraduodenal pancreatitis, biliary tree trauma and tumors ⁽⁴⁾.

This study aimed at highlighting the role of Magnetic resonance cholangiopancreatography (MRCP) in evaluation of biliary and pancreatic ductal abnormalities for better management of the patients.

Patients and methods

-MoHP No. :0018122017

-Certificate No. :1017

-Study No.: Ms.1.6.2019

-REC Decision No. :782

Patients:

This case control study was conducted on sixty (60) participants including two groups; a study group of forty-two (42) patients who had symptoms related to

pancreaticobiliary pathologies and eighteen (18) healthy adult volunteers with no history of current or past symptoms as a control group. The case group included 25 males and 17 females whose ages ranged from 32 to 84 years (a mean age of 59.69 ± 13.17 years), on the other hand the age of the control group ranged from 23 to 55 with mean age (42.4 ± 11.8) and a male to female ratio (1:1). All patients were referred to the MRI unit – Radiology department from Hepatology unit at AlAhrar teaching hospital, Zagazig, Sharkia governorate – Ministry of health, from June 2022 to April 2023.

MRCP Protocol:

- MRI was done on Philips Achivia 1.5 Tesla MRI machine using body coil.

- Examination was performed after the patient had fasted for 6-8 hours to promote gall bladder filling.

- First, conventional upper abdominal MRI examination was done, including axial T1WI, T2 WI and STIR and coronal T2 WI sequences, before MRCP protocols.

- Thin slab sequence (3D-MRCP HR; TR:1204 ms; TE:650 ms; flip angle: 90 degrees; FOV: 260; 1mm thick straight 3D coronal sections at 0.8-mm interval).

- All of the sequences were recorded during a single breath hold to promote gallbladder filling.

-The observations made on MRCP/MRI were biliary channels, their asymmetrical/symmetrical dilatation, pancreatic duct, calculus, stricture's site, margins (regular/irregular), tapering (abrupt/gradual), length of stricture (long/short), Gall Bladder, lymph nodes, metastasis.

- Upper abdominal DWI was done by single-shot echo-planar imaging sequence (TR4200, TE83, FOV440, NEX2, matrix 144×192 , slice thickness 6 mm) with $b=0$, $b=400$, $b=800$ s/ mm^2 values using MRI superconducting unit (Philips Achieva).

Imaging evaluation:

-Images revision was performed in conjunction with detailed clinical and

operative patients' history background as well as reports of other imaging studies, biliary laboratory findings and biliary interventional procedures.

- Radiological interpretation of the images was done using a commercial workstation (view forum workstation, Phillips Dicom).
- The MRCP findings were correlated with the results of ERCP technique; when done; and was considered the gold standard reference in those cases.
- ERCP wasn't mandatory in all cases in the study, (e.g., patient refusal, conservative management or no role of ERCP), and in such cases the MRCP findings were correlated either with clinical/laboratory data, ultrasound findings, CT/MRI classic findings or histopathology.
- The final diagnosis was established based on all the findings, then the sensitivity, specificity, positive and negative predictive values of the analyzed data-were measured using commercially available PC-based software package.

The statistical methods

Statistical analysis was done by SPSS version 28 (IBM Co., Armonk, NY, USA). Quantitative parametric data were presented as mean, standard deviation (SD) and range. Quantitative non-parametric data were presented as the median and interquartile range (IQR).

Qualitative variables were presented as frequency and percentage (%).

P value.....

Results

As shown in Table (1) most patients (90.48%) had peripheral bile tracts dilatation, 88.1%, 90.48 and 78.57% respectively had RHD, LHD and CHD dilatation. Three out of 42 patients had increased bile tracts wall thickening (1 in RHD and 2 in LHD).

As shown in Table (2), MRCP examination revealed that 73.81% of the studied patients had dilated CBD with a median diameter of 10 mm and 2.38% had thickened CBD wall. CBD stones were detected in 30.95% of patients with a median size of 9.5 mm (16.67% were located at the distal duct and 7.14% at the proximal duct). Meniscus sign was detected in 11.9% of patients and stents were detected in 7.14%.

As shown in Table (3-A), MRCP was able to detect benign biliary stricture in 21.43% of the studied patients (14.29 % involved the CBD, 11.9% was in distal CBD, 2.38% was in middle CBD). It was located in CHD, RHD and LHD, each with 2.38%. Regarding stricture shape, the detected pattern was regular smooth tapered short segment.

Table 1: IHBRD evaluation of the studied patients by MRCP.

IHBRD Evaluation Items	N	%
Peripheral bile tracts dilatation	38	90.48
RHD dilatation	37	88.1
LHD dilatation	38	90.48
CHD dilatation	33	78.57
Increased bile tracts wall thickening	3	7.14
RHD	1	2.38
LHD	2	4.76

CHD: common hepatic duct, RHD: right hepatic duct, LHD: left hepatic duct, IHBRD: intrahepatic biliary radicles dilatation.

Table 2: CBD evaluation of the studied patients by MRCP.

CBD Evaluation Items	N	%
Dilatation	31	73.81
Diameter (mm)	Median	IQR
	10	7 - 14
Wall thickness		
Normal	41	97.62
Thickened	1	2.38
Stone	13	30.95
Stone size (mm)	Median	IQR
	9.5	7.5 – 14.5
Stone location		
Proximal	3	7.14
Middle	1	2.38
Distal	7	16.67
Proximal and middle	1	2.38
Middle and distal	1	2.38
Meniscus sign		
Absent	8	19.05
Present	5	11.90
Stent	4	9.52
Stent complications	0	0

CBD: common bile duct , IQR : interquartile range

Table 3-A: Evaluation of benign biliary strictures diagnosed by MRCP.

Biliary Strictures Evaluation Items	N	%
Biliary stricture	9	21.43
Stricture site		
Distal CBD	5	11.9
Middle CBD	1	2.38
CHD	1	2.38
RHD	1	2.38
LHD	1	2.38
Stricture shape		
Short regular smooth tapered	9	21.43

CHD: common hepatic duct, RHD: right hepatic duct, LHD: left hepatic duct, IHBRD: intrahepatic biliary radicles dilatation.

As shown in Table (3-B), MRCP was able to detect malignant biliary stricture in 38.1% of the studied patients (21.43% was in distal CBD, 9.52% was in hepatic biliary confluence while it was located in Left hepatic lobe in 2.38%). There was external compression on the biliary tree in 4.76% of the patients with compression on the CHD & CBD in 2.38% for each. Regarding stricture shape, the most common patterns were abrupt obstruction of the distal CBD in 21.43% of patients

followed by obliterated hepatic ductal confluence 9.52%.

As shown in Table (4), the most common finding detected by MRCP was Choledocholithiasis in 30.95% of the studied patients followed by Cholelithiasis in 26.19% then cholecystitis, Cancer head of pancreas elicited by 16.67% of patients and CBD benign stricture was detected by 14.29%.

Table 3-B: Evaluation of malignant biliary strictures diagnosed by MRCP.

Biliary Strictures Evaluation Items	N	%
Biliary stricture	16	38.1
Stricture site		
Distal CBD	9	21.43
Hepatic biliary confluence	4	9.52
LHD	1	2.38
External compression on CHD	1	2.38
External compression on CBD	1	2.38
Stricture shape		
Abrupt obstruction of the distal CBD	9	21.43
Obliterated hepatic ductal confluence with hepatic mass	3	7.14
Obliterated hepatic ductal confluence with no obvious hepatic mass	1	2.38
Irregular thickening of LHD with hepatic focal lesions	1	2.38
Compression & obstruction of the CHD by metastatic hepatic hilar mass	1	2.38
Compression of the CBD by the large lesser sac mass	1	2.38

Table 4: MRCP diagnosis of the studied patients.

MRCP Diagnosis	N	%
Choledocholithiasis	13	30.95
Cholelithiasis	11	26.19
Cholecystitis	7	16.67
Cancer head of pancreas	7	16.67
CBD benign stricture	6	14.29
Cholangiocarcinoma	5	11.90
Cholangitis	3	7.14
Hepatic metastases	3	7.14
Post cholecystectomy biloma	3	7.14
CBD stent with no complications	3	7.14
Acute pancreatitis	2	4.76
periampullary carcinoma	2	4.76
Cystic duct stones	2	4.76
Choledochocele	1	2.38
Metastatic Porta hepatis mass with consequent biliary outflow obstruction	1	2.38
Large lesser sac mass with consequent biliary outflow obstruction	1	2.38

Discussion:

Our study included 60 participants, 42 symptomatic patients and 18 normal individuals- who were all investigated by MRI/MRCP. Included patients were categorized into 6 groups: Group I included the normal individuals, group II included gall bladder (GB) related abnormalities comprehending cholecystectomy cases, while group III included patients with CBD stones, with or without CBD stent that were inserted as a line of treatment. Coming to group IV, it

included patients with cholangitis, hepatic ducts stones and benign biliary stricture that were diagnosed by MRCP, while group V included patients with neoplastic entities diagnosed by MRCP and finally group VI included patients with acute pancreatitis. The patient who had more than one pathology- was shared on both groups not only one group.

The 42 symptomatic patients involved 25 males and 17 females whose ages range from 32 to 84 years and had symptoms of biliary and or pancreatic diseases. All

patients were investigated with MRI/MRCP to evaluate biliary tree and pancreatic abnormalities. In our study, we detected 90.48% of the symptomatic patients having peripheral bile tracts dilatation, where 88.1%, 90.48 and 78.57% had RHD, LHD and CHD dilatation respectively; with 73.81% had CBD dilatation.

Gall bladder related abnormalities (Group II) presented in 19 of the 42 patients including 8 cholecystectomy patients. The gall bladder (GB) related abnormalities included cholelithiasis (including cystic duct stones) and cholecystitis. Fourteen patients showed GB stones (including 2 patients with cystic duct stones) whose ages range from 38years to 80 years representing 33.33% of the symptomatic patients whereas 8 patients showed cholecystitis representing about 19% of the studied patients.

There was no significant gender predilection of patients with gall bladder stones in our study, as amongst the 14 patients with GB stones there were 7 males and 7 females with cholelithiasis. This doesn't totally match with what was mentioned Knab et al.,⁽⁵⁾ and Cianci and Restini.,⁽⁶⁾ who stated that female gender is a risk factor for GB stones formation. In our study, this would be a reflection of the studied group not to the actual disease prevalence itself.

In our study, MRCP was obviously useful in the evaluation of post-cholecystectomy complications as delineation of the location of iatrogenic biliary tree injury, evaluation of biomass and the inserted pigtail catheters. Our findings were in keep with what was stated by Khalid et al.,⁽⁷⁾ and Sureka and Mukund.,⁽⁸⁾ and Barbier et al.,⁽⁹⁾.

The current study included 8 patients with cholecystectomy in whom we evaluated the possible postcholecystectomy dilatation of CBD. We excluded two patients with postcholecystectomy choledocholithiasis as the presence of CBD stones can itself cause CBD dilatation that could definitely

interfere with the evaluation of CBD diameter in postcholecystectomy patients. In our study, there was no notable dilatation in CBD diameter after 1 month of cholecystectomy regardless the age of the patient, whereas after more than 1 year there was dilatation of the CBD caliber that could reach 10 mm. In our study, all patients in this subgroup were in the 6th to 7th decade of age. This coped with what was mentioned by Park et al.,⁽¹⁰⁾ that a CBD dilatation within 10 mm in gallbladder resected patients can be regarded as normal physiological change. The results also kept up with what was stated by Pallaneandee et al.,⁽¹¹⁾ that this post-cholecystectomy dilatation can be attributed to compensatory adaptation of the CBD in the absence of the gallbladder. In our study, biliary stones weren't only detected in GB but also in CBD and hepatic ducts (group III patients). MRCP detected CBD stones in 30.95% of the symptomatic patients of the study with 7.14% of them had inserted CBD stents as a line of treatment of biliary stones. Meniscus sign was detected in 11.90 % of the symptomatic patients representing 38.46% of patients with choledocholithiasis and all were detected at the distal CBD. Meniscus sign of the CBD was defined by Siva P. et al.,⁽¹²⁾ as a sharp cutoff of a dilated CBD at the ampulla, often with a well marginated "meniscus" configuration, that can hint at the presence of an impacted CBD stone. In the present study, the MRCP findings of patients with choledocholithiasis were correlated with ERCP intervention of the same patients. In comparison to ERCP as a gold standard, MRCP as regards the diagnosis of biliary stones shows 100% sensitivity, 94.74% specificity, 92.31% PPV, 100% NPV with an overall diagnostic accuracy of 96.77%. Our findings keep with what was mentioned by Cetiner-Alpay et al.,⁽¹³⁾ that with ERCP as the gold standard, the sensitivity, specificity, PPV, NPV and accuracy of MRCP for diagnosis of choledocholithiasis

were 100%, 94.7%, 95.4%, 100% and 97.5%, respectively. However, Ali et al.,⁽¹⁴⁾ found the sensitivity, specificity, PPV and NPV for MRCP were 89.3%, 78.1%, 64% and 94.3%, respectively, for choledocholithiasis.

The variation in the MRCP results of diagnosing the CBD stones compared to the ERCP can be attributed to the variation in the MRCP protocol itself. One more explanation was mentioned by Christina et al., 2023⁽¹⁵⁾ who stated that when additional pre- ERCP imaging was performed (EUS/MRCP), the chance of CBD sludge or stones during ERCP increased. Timing is of importance, and it was revealed that a delay of more than two days between diagnostic imaging (EUS/MRCP) and ERCP reduces the chance of a positive ERCP. Additional imaging by EUS or MRCP should be repeated if the time interval exceeds 2 days.

In the current study, we detected biliary stones not only in GB or CBD but also in hepatic ducts (Group IV patients). Hepatic ducts stones were detected in 7.14% of symptomatic patients. As per Sakpal et al.,⁽¹⁶⁾ hepatolithiasis is defined as the presence of biliary stones in the bile ducts proximal to the confluence of the right and left hepatic ducts, irrespective of the co-existence of biliary stones in the common bile duct (CBD) and/or gallbladder. Kim et al.,⁽¹⁷⁾ stated that MRCP is a more effective diagnostic method for the evaluation of intrahepatic stones than ERCP that compared with common bile duct stones is neither an effective treatment method nor an accurate diagnostic modality for intrahepatic stones. The present study showed that 14.29 % of the symptomatic patients of the study had benign CBD strictures (Group IV patients) diagnosed by MRCP. All stricture involved short segment of the CBD that appeared regular, symmetric with smooth tapered margins with no complete obstruction of the CBD. No restriction was detected in DWI of the strictures. Our findings of the benign CBD strictures kept

with what was mentioned by Shanbhogue et al.,⁽¹⁸⁾ and Shabanikia et al.,⁽¹⁹⁾. In comparison to ERCP as a gold standard, MRCP gave for the diagnosis of benign biliary strictures 85.71% sensitivity, 100% specificity, 100% PPV, 94.74 NPV with an overall accuracy of 96%. Our results kept with Cetiner-Alpay et al.,⁽¹³⁾ who stated that with ERCP as the gold standard, the sensitivity, specificity, PPV, NPV and accuracy of MRCP for diagnosis of benign biliary strictures were 93.7%, 100%, 100%, 99%, and 99%, respectively. Ali et al.,⁽¹⁴⁾ reported the sensitivity, specificity, PPV and NPV were 37.5%, 94%, 37.5% and 94% respectively. They attributed the substantially low sensitivity of their study - compared to the international data - to the small number of patients (8.7%) who definitely had strictures. Another possible explanation for this may be the different MRCP protocols used for the detection of biliary diseases.

We reviewed the published literature to assess the MRCP criteria of differentiating malignant from biliary strictures. As per Nirhale et al.,⁽¹⁾, Shabanikia et al.,⁽¹⁹⁾, Wang et al.,⁽²⁰⁾, Suthar et al.,⁽²¹⁾ irregular, long, asymmetric, or abrupt narrowing of the biliary and/or pancreatic duct were considered as malignant features. Besides, a narrow segment accompanied by solid mass, vascular and/or organ invasion, distal pancreatic parenchymal atrophy, distant metastases, lymph nodes infiltration or areas of low signal intensity in the pancreatic head on T1-weighted unenhanced images were considered as malignant stricture. The appearance of the “double duct sign”, which includes the dilation of the common bile duct and main pancreatic duct, is classically seen with cancer head of pancreas. Furthermore, Rabie et al.,⁽²²⁾, Abd Elwhab et al.,⁽²³⁾, Lee et al.,⁽²⁴⁾ and Cetiner-Alpay et al.,⁽¹³⁾ emphasized that combined use of DWI with MRCP was of better capability of detection of abnormal lesions and the differentiation of malignant from benign tumor-like lesions

in the biliopancreatic tract and can be used as a reasonable alternative technique for the assessment of the pancreaticobiliary tract in the setting of a contraindication to contrast agents such as renal insufficiency or contrast allergy .

In our study, we detected 38.1% of the symptomatic patients to have neoplastic entities (Group V patient). We depended upon the above-mentioned criteria in the

reviewed literature as a reference in our MRI/MRCP diagnosis. Based on the MRI/MRCP criteria, 16.67 % they had cancer head of pancreas, 4.76 % had periampullary carcinoma, 11.9 % had cholangiocarcinoma and 4.76 % had biliary tract obstruction by external compression from extra-biliary masses.

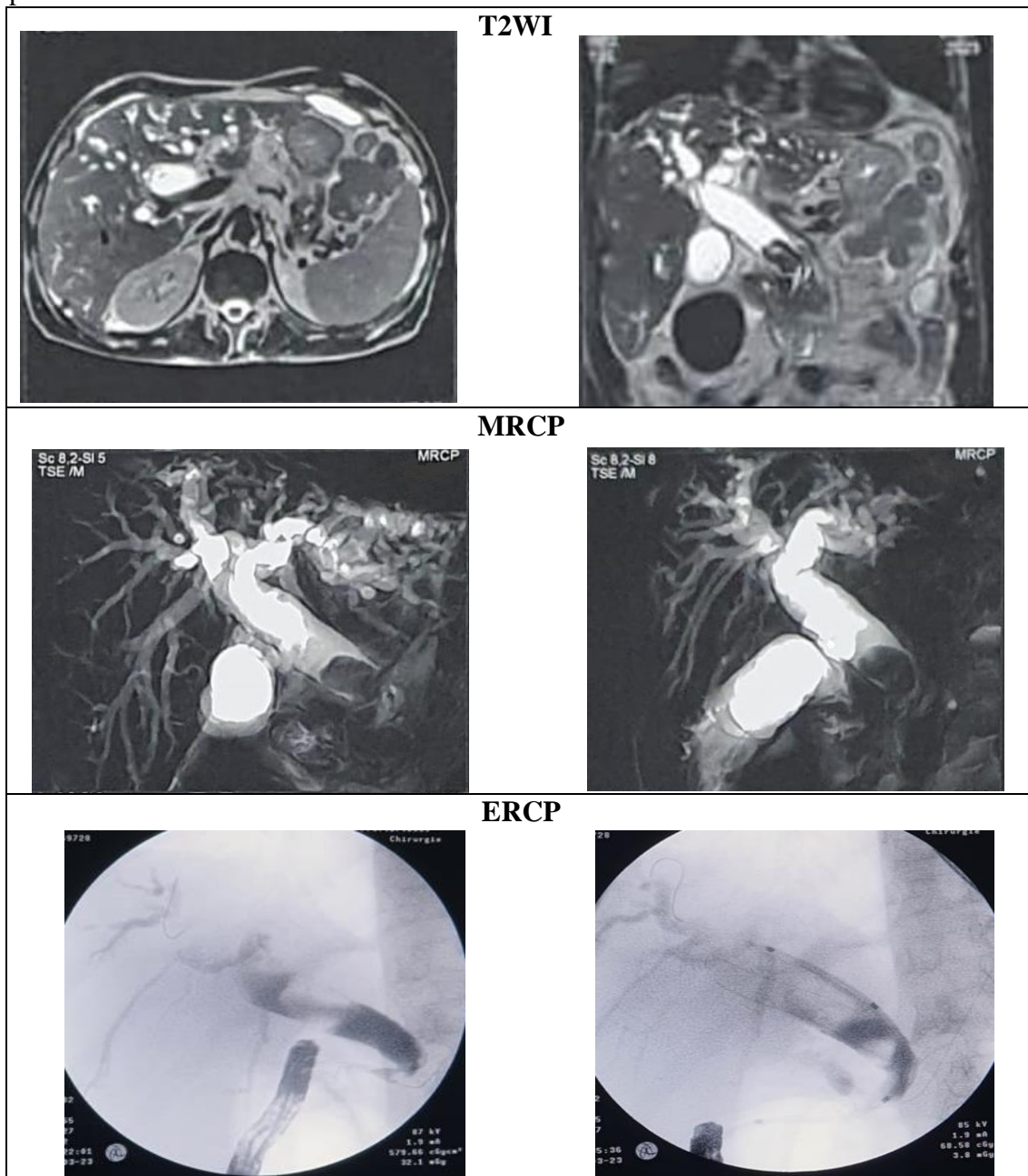


Figure1: 65 years old male patient with obstructive jaundice. MRCP shows moderate IHBRD involved both hepatic lobes with dilated CBD down till its distal part where a large filling defect of signal void is seen impacted. Pancreas showed normal signal with normal PD, as shown in figure. MRCP Diagnosis: Choledocholithiasis. ERCP shows dilated CBD with stones and deformed duodenal bulb.

The gender predilection and age of the patients who were diagnosed as cancer head of pancreas in our study kept with what was mentioned Hu et al.,⁽²⁵⁾. The detected imaging characteristics of the pancreatic head masses kept with the features mentioned by Nakaoka et al.,⁽²⁶⁾ Ahualli, 2007⁽²⁷⁾ and Agrawal and Vohra, 2017⁽²⁸⁾.

We detected 4.76 % of the symptomatic patients having periampullary soft tissue lesions. Our diagnosis based on the MRCP findings was periampullary carcinoma in both patients. Our findings kept with what was mentioned by Shabanikia et al., 2021⁽¹⁹⁾, Lee et al.,⁽²⁴⁾, Ahualli,⁽²⁷⁾ and Agrawal and Vohra,⁽²⁸⁾.

The present study showed that 11.9 % of the patients with symptoms of obstructive jaundice had biliary strictures with features kept with the malignant strictures stated in the abovementioned literatures. The gender predilection was 3 males: 2 females whose ages ranged from 54 years to 80 years. Our diagnosis kept with what was mentioned by Foster et al.,⁽³⁾, Engelbrecht et al.,⁽²⁹⁾, Seo et al.,⁽³⁰⁾ and Mahajan et al.,⁽³¹⁾.

In the present study, there was two more patients with large soft tissue masses causing external compression of the biliary outflow. The first patient had a large soft tissue lesser sac mass which hisopathological correlation revealed lymphoma. The other patient had large heterogenous soft tissue mass epicentered at the hepatic hilum inseparable from the pancreatic head that hisopathological correlation revealed metastatic right lung poorly differentiated carcinoma.

The last group of patients in our study was patients with acute pancreatitis (group VI). Our diagnosis of the first patient was acute interstitial edematous pancreatitis, yet acute necrotizing pancreatitis of the other patient. The detected findings kept with what was stated by Walkowska et al.,⁽³²⁾, Brizi et al.,⁽³³⁾ and Huan Sun et al.,⁽³⁴⁾ about the imaging features of the acute

pancreatitis. As per Sevensma et al.,⁽³⁵⁾ since MRCP is a relatively expensive study, it should be reserved for patients who will more likely benefit from it with acute gallstone pancreatitis benefited more from MRCP than patients with other causes of acute pancreatitis.

Limitations of the study:

Surgical/histopathological/ERCP correlation could not be performed in all cases as some cases of both benign and malignant pathologies- were treated conservatively. Moreover, not all pancreaticobiliary pathologies were included in the study e.g., chronic pancreatitis.

Conclusion:

MRCP is a noninvasive beneficial diagnostic tool that has a pivotal role in diagnosis pancreaticobiliary disorders. Regardless of its cost, availability and time-consuming factors, it can be used to guide the further step of management in patients with obstructive jaundice.

References:

1. Dakshayani S. Nirhale , Gaurav C. Kulkarni , Pravin Shingade , Shahaji Chavan, Tejas Sonawane and Mansi Dhende,: Role of magnetic resonance cholangiopancreatography in diagnosing pancreatobiliary pathologies: a prospective study . Int Surg J(2018).;5(6):2233-2237
2. Qiushi Wang , Jordan Swensson , Maoqing Hu, Maoqing Hu , Enming Cui , Temel Tirkes ,et al.;; Distribution and correlation of pancreatic gland size and duct diameters on MRCP in patients without evidence of pancreatic disease . Abdominal Radiology(2019) ; 44:967–975
3. Kelly Fábrega-Foster , Mounes Aliyari Ghasabeh , Timothy M. Pawlik and Ihab R. Kamel.;; Multimodality imaging of intrahepatic cholangiocarcinoma . HepatoBiliary Surg Nutr (2017); 6(2):67-78
4. Mahmoud Aghaa, Ahmed M. Abougabal and Hazem Abd- Ellatief: The breath-hold 2D MRCP and the respiratory-triggered 3D MRCP sequences, comparative study as regards the possible pitfalls . The Egyptian Journal of

- Radiology and Nuclear Medicine ; (2018) 49 : 614–623
5. Lawrence M. Knab, Anne-Marie Boller, David M. Mahvi : Cholecystitis . Surg Clin N Am : 94 : 455–470. [http://dx.doi.org/10.1016/j\(2014\).suc.2014.01.005](http://dx.doi.org/10.1016/j(2014).suc.2014.01.005)
 6. Pasquale Cianci and Enrico Restini: Management of cholelithiasis with choledocholithiasis: Endoscopic and surgical approaches. World J Gastroenterol : (2021) 28; 27(28): 4536-4554 DOI: 10.3748/wjg.v27.i28.4536 .
 7. Tahir R. Khalid , V. Javier Casillas , Berta M. Montalvo , R Centeno and J U Levi., : Using MR Cholangiopancreatography to Evaluate Iatrogenic Bile Duct Injury . AJR ; (2001) 177:1347–1352
 8. Binit Sureka and Amar Mukund: Review of imaging in post-laparoscopy cholecystectomy complications . Indian J Radiol Imaging (2017):27:470-81. DOI: 10.4103/ijri.IJRI_489_16
 9. L. Barbier , R. Souche, K. Slim and P Ah-Soune., : Long-term consequences of bile duct injury after cholecystectomy . Journal of Visceral Surgery (2014): 151: 269-279. <http://dx.doi.org/10.1016/j.jvisc Surg.2014.05.006>
 10. Seon Mee Park, Woo Seok Kim, Il-Hun Bae , Ji Hoon Kim, Dong Hee Ryu, Lee-Chan Jang, et al., : Common bile duct dilatation after cholecystectomy: a one-year prospective study . J Korean Surg Soc (2012): 83:97-101 .<http://dx.doi.org/10.4174/jkss.2012.83.2.97>
 11. N. K. Pallaneeandee, S. S. Govindan , and L. Z. Jun: Evaluation of the Common bile duct (CBD) Diameter After Laparoscopic Cholecystectomy (LC) and Laparoscopic Common Bile Duct Exploration (LCBDE): A Retrospective Study . Surg Laparosc Endosc Percutan Tech(2023) : 33: 62-68
 12. Siva P. Raman and Elliot K. Fishman :Abnormalities of the Distal Common Bile Duct and Ampulla: Diagnostic Approach and Differential Diagnosis Using Multiplanar Reformations and 3D Imaging . AJR (2014) : 203:17–28 DOI:10.2214/AJR.13.11288
 13. Cetiner-Alpay Z, Kulali F, Semiz-Oysu A , Yasar Bukte, Kamil Ozdil., : The role of magnetic resonance cholangiopancreatography and diffusion-weighted imaging for the differential diagnosis of obstructive biliary disorders . S Afr J Rad. (2017) 2017; 21(1), a1193. <https://doi.org/10.4102/sajr.v21i1.1193>
 14. Farman Ali, Naveed Aamir, Muhammad Kamran Hassan , Hashmat Ullah Khan and Dilaram Khan., : Comparison of MRCP and ERCP findings: A retrospective secondary data analysis . JPMA(2022) 72: 284; 2022. DOI: <https://doi.org/10.47391/JPMA.20-721>
 15. Christina J Sperna Weiland , Evelien C Verschoor , Alexander C Poen , Xavier J M N Smeets , Niels G Venneman , Abha Bhalla, et al., : Suspected common bile duct stones: reduction of unnecessary ERCP by pre-procedural imaging and timing of ERCP . Surgical Endoscopy (2023): 37:1194–1202 <https://doi.org/10.1007/s00464-022-09615-x>
 16. Sujit Vijay Sakpal , Nitin Babel and Ronald Scott Chamberlain : Surgical management of hepatolithiasis . HPB : (2009) 11: 194-202. DOI:10.1111/j.1477-2574.2009.00046.x
 17. Tae Kyoung Kim , Bong Soo Kim , Jung Hoon Kim , Hyun Kwon Ha, Pyo Nyun Kim, Ah Young Kim, et al., :Diagnosis of Intrahepatic Stones: Superiority of MR Cholangiopancreatography over Endoscopic Retrograde Cholangiopancreatography . AJR (2002): 179:429-434 .
 18. A. K. P. Shanbhogue , S. H. Tirumani , S. R. Prasad , Najla Fasih and Matthew McInnes., : Benign Biliary Strictures: A Current Comprehensive Clinical and Imaging Review. AJR : (2011) 197:W295–W306 DOI:10.2214/AJR.10.6002
 19. Niloufar Shabanikia, Atoosa Adibi and Shadi Ebrahimian: Diagnostic Accuracy of Magnetic Resonance Cholangiopancreatography to Detect Benign and Malignant Biliary Strictures . Adv Biomed Res. : (2021) 10: 38. doi: 10.4103/abr.abr_137_20
 20. Guang-xian Wang, Xiao-dong Ge, Dong Zhang , Hai-ling Chen, Qi-chuan Zhang and Li Wen.,: MRCP Combined With CT Promotes the Differentiation of Benign and Malignant Distal Bile Duct Strictures . Front. Oncol. : 11: 683869. doi(2021): 10.3389/fonc.2021.683869
 21. Meena Suthar , Sunita Purohit , Vivek Bhargav and Pradeep Goyal., : Role of MRCP in Differentiation of Benign and Malignant Causes of Biliary Obstruction . Journal of Clinical and Diagnostic Research (2015): Vol-9(11): 8-12 .DOI: 10.7860/JCDR/2015/14174.6771
 22. Shaimaa Rabie , Ahmed Mohallel , Samer Saad Bessa, Ahmed Hafez and Amr Magdy El-Abd., : The role of combined diffusion weighted imaging and magnetic resonance cholangiopancreatography in the differential diagnosis of obstructive biliary disorders . Egyptian Journal of Radiology and Nuclear Medicine (2021): 52:128
 23. Saeda Mohamed Abd Elwhab, Ahmed Okasha Mohamed, Mohamed Abd Elshafy Elsheimy , Ahmed Al sabaqy Abdulwareth and Esraa khalifa Hassan., : Role of MRCP and Diffusion Weighted Imaging in Diagnosis of Extrahepatic Biliary Stricture . The Egyptian Journal of

- Hospital Medicine : (2022) Vol. 88 : 3862-3867
24. Nam Kyung Lee, Suk Kim, Gwang Ha Kim , Dong Uk Kim, Hyung Il Seo, Tae Un Kim, et al., : Diffusion-weighted imaging of biliopancreatic disorders: Correlation with conventional magnetic resonance imaging . World J Gastroenterol (2012): 18(31): 4102-4117 .doi:10.3748/wjg.v18.i31.4102
 25. Jian-Xiong Hu, Cheng-Fei Zhao, Wen-Biao Chen, Qi-Cai Liu, Qu-Wen Li, Yan-Ya Lin, et al., : Pancreatic cancer: A review of epidemiology, trend, and risk factors . World J Gastroenterol : (2021) 27(27): 4298-4321 DOI: 10.3748/wjg.v27.i27.4298
 26. Kazunori Nakaoka , Eizaburo Ohno , Naoto Kawabe , Teiji Kuzuya, Kohei Funasaka, Yoshihito Nakagawa, et al., : Current Status of the Diagnosis of Early-Stage Pancreatic Ductal Adenocarcinoma . Diagnostics : (2023) 13: 215 <https://doi.org/10.3390/diagnostics13020215>
 27. Jorge Ahualli: The Double Duct Sign . Radiology : (2007) 244: 314–315 .Doi 10.1148/radiol.2441041978
 28. Shefali Agrawal and Sandeep Vohra: Simultaneous Courvoisier's and double duct signs . World J Gastrointest Endosc: (2017) 16 : 9(8): 425-427 . DOI: 10.4253/wjge.v9.i8.425
 29. Marc Rudi Engelbrecht , Seth S. Katz , Thomas M. Van Gulik , Johan S. Laméris, and Otto M. van Delden., : Imaging of Perihilar Cholangiocarcinoma . AJR (2015): 204:782–791.DOI:10.2214/AJR.14.12830
 30. Nieu Seon , Do Young Kim and Jin-Young Choi: Cross-Sectional Imaging of Intrahepatic Cholangiocarcinoma: Development, Growth, Spread, and Prognosis . AJR : (2017) 209:W64-W75 DOI:10.2214/AJR.16.16923
 31. Mangal S Mahajan, Srikanth Moorthy, Sreekumar P Karumathil , R Rajeshkannan, and Ramchandran Pothera., : Hilar cholangiocarcinoma: Cross sectional evaluation of disease spectrum . Indian Journal of Radiology and Imaging : (2015) 25 (2) : 184-192 .DOI:10.4103/0971-3026.155871
 32. Julia Walkowska , Nicol Zielinska , R. Shane Tubbs, Michał Podgórski, Justyna Dłubek-Ruxer and Łukasz Olewnik ., (2022): Diagnosis and Treatment of Acute Pancreatitis. Diagnostics : 12, 1974. <https://doi.org/10.3390/diagnostics12081974>
 33. Maria Gabriella Brizi , Federica Perillo , Federico Cannone , Laura Tuzza, and Riccardo Manfredi., : The role of imaging in acute pancreatitis . La radiologia medica (2021): 126:1017–102 .<https://doi.org/10.1007/s11547-021-01359-3>
 34. Huan Sun , Hou-Dong Zuo, Qiao Lin , Dan-Dan Yang, Ting Zhou, Meng-Yue Tang, et al., :MR imaging for acute pancreatitis: the current status of clinical application . Ann Transl Med : (2019) 7(12):2 .Doi: 10.21037/atm.2019.05
 35. Karlin Sevensma, Miranda Allen, Rebecca Harden and William Corser., : The Use of Magnetic Resonance Cholangiopancreatography (MRCP) in the Setting of Acute Pancreatitis: When is it Most Useful? . Spartan Med Res J. (2017): 2(1): 5963.Doi: 10.51894/001c.5963

To cite this article: Medhat M. Refaatb, Manal A. ElRefaei, Mohammad A. Moustafa. Magnetic Resonance Cholangiopancreatography: Diagnostic Role in Evaluating Pancreaticobiliary Abnormalities. BMFJ XXX, DOI: 10.21608/bmfj.2024.235953.1896.