

New Hysteroscopic View in Chronic Endometritis

Mohamed F. Elsherbeny, Mohamed I. Mohamed, Mariam M. Frazily,

Shreen N. Abo El Ezz

Abstract:

Background: Chronic endometritis (CE) reflects a chronic inflammatory state within endometrium. This study aimed to investigate the value of hysteroscope in diagnosing chronic endometritis and evaluate the prevalence of chronic endometritis in patients with recurrent implantation failure by hysteroscope and biopsy. **Methods:** This is a prospective interventional study that was performed at Benha University Hospital and at a private gynecology center during the period from June 2022 and December 2022. The study included 20 women undergoing hysteroscope indicated by common conditions such as chronic pelvic pain, recurrent implantation failure, and recurrent miscarriage during the study period. The study patients underwent office hysteroscope examination and histopathological examination. **Results:** There were statistically significant differences between patients with chronic endometritis and those without in the presence of diffuse endometrial hyperemia ($p=0.005$) and dilated vessels ($p=0.035$), with statistically higher scores in the group of chronic endometritis ($p=0.002$). The ROC revealed that a score cutoff value of > 2 was able to diagnose chronic endometritis with an excellent performance ($AUC=0.923$). It showed a sensitivity of 87.5% and a specificity of 85.7% ($p=0.002$). There was substantial agreement between the hysteroscopic diagnosis by the new scoring system and the histopathological diagnosis ($kappa=0.792$ and $p=0.002$). **Conclusion:** From the study findings, hysteroscopy is a recommended useful diagnostic tool in chronic endometritis screening in asymptomatic infertile women.

Keywords: New; Hysteroscopic View; Chronic Endometritis.

Obstetrics and Gynecology
Department, Faculty of
Medicine Benha University,
Egypt.

Corresponding to:
Dr. Mariam M. Frazily.
Obstetrics and Gynecology
Department, Faculty of Medicine
Benha University, Egypt.
Email: tomsgad95@gmail.com

Received:
Accepted:

Introduction

Chronic endometritis (CE) is defined as localized inflammation of the endometrial mucosa characterized by the presence of edema, increased stromal cell density, dissociated maturation between epithelial cells and stroma fibroblasts, as well as the presence of plasma cell infiltrate in the stroma. These changes at the level of endometrial microenvironment could affect endometrial receptivity⁽¹⁾.

The pathogenesis of CE may be the result of qualitative and quantitative alteration of endometrial microbiome. According to recent studies, the main species of bacteria involved in the development of CE are Enterococci, Streptococci, Staphylococci, Mycoplasma spp, Gardnerella vaginalis, Ureaplasma urealyticum, Chlamydia trachomatis and Neisseria gonorrhoeae⁽²⁾.

The clinical significance of CE has not traditionally been a concern in clinical practice because it is usually asymptomatic or presents only with subtle symptoms, such as abnormal uterine bleeding, pelvic pain, dyspareunia, and leucorrhea⁽³⁾.

This attitude has led to a lack of importance being given to chronic endometritis in the field of gynecology. However, reproductive medicine has begun to consider that its diagnosis could be essential as it has been closely related to unexplained infertility, repeated miscarriages or repeated implantation failure (RIF)⁽⁴⁾.

For over a century, intrauterine blind biopsy techniques were considered the gold standard procedure for the histopathological diagnosis of intrauterine diseases. The advent of hysteroscopy, which made it possible to directly visualize the uterine cavity, and the subsequent miniaturization of the instruments allowing its use in the office setting without anesthesia are considered game-changers⁽⁵⁾.

The main advantage of hysteroscopy is that biopsies can be taken at the same time with great safety, which improves the diagnostic accuracy. Also, its "see and

treat" potential provides higher patient satisfaction⁽⁶⁾.

Endometrial hysteroscopy can assess the inflammatory microenvironment in uterine cavity and alert to the diagnosis of CE. Microbiological cultures are used to identify the possible pathogens involved and to direct administration of the most appropriate antibiotic treatment⁽⁴⁾.

Histological examination of plasmacyte is considered the core criterion, but it is difficult to distinguish fibroblasts and mononuclear cells morphologically from plasmacytes using conventional hematoxylin-eosin (HE) staining⁽⁷⁾. Syndecan-1 (also known as CD138) immunohistochemistry (IHC) is more recommended, which can significantly increase the identification rate in routine histologic examination⁽⁸⁾.

Recently, a new CE prediction scoring system has been established by collecting clinical data and examining the possible effect of various parameters on CE.

This study aimed to investigate the value of hysteroscope in diagnosing chronic endometritis and evaluate the prevalence of chronic endometritis in patients with recurrent implantation failure by hysteroscope and biopsy.

Patients and methods

This prospective interventional study was performed at Benha University Hospital and a private gynecology center during the period from June 2022 and December 2022.

The study was done after being approved by the research ethics committee (Ms.15.5.2023), faculty of medicine, Benha University and informed consent was obtained from all participants included.

This study included 20 women undergoing hysteroscope indicated by common conditions such as chronic pelvic pain and recurrent implantation failure during the study period.

Inclusion criteria were women aged 20-40 years with chronic pelvic pain, or

unexplained infertility or recurrent pregnancy failure.

Exclusion criteria were Pregnant women, history of malignant tumor, uterine anomalies, endometrial atypical hyperplasia, or intrauterine adhesions, hematologic disorders, thrombocytopenia, other coagulation disorders, leukemia, aplastic anemia, uncontrolled hypertension, recent acute inflammation or on antibiotic treatment for acute inflammation, history of using oral contraceptive (during the last 2 months) or having IUCD inserted for a long time.

The study participants were subjected to full history taking including: a- Personal history: name, age, b- Obstetric history and gynecologic history, c- History of present illness: diabetes mellitus, hypertension, any chronic disease and drug allergy, d- Family history.

Clinical Examination: Full general and local examination

Office Hysteroscope Examination: All patients underwent hysteroscopy at the follicular stage of the menstrual cycle (3–7 days after menstruation). All patients included in this study underwent office hysteroscopy by the vaginoscopic approach technique. Vaginoscopic approach is a no touch, atraumatic technique (no use of speculum or tenaculum) with high levels of acceptance among patients. Hysteroscopy was performed using the rigid office hysteroscope (STORZ company, Germany), 30-degree offset lens, 2.9 mm scope with a 3.8 mm sheath, manual pump for saline distention media, light source (fiber optic light cable with straight conductor of 2.5 mm diameter and 180 cm length), a camera with focal length f70-f140 connected to a monitor. The patient is placed in the lithotomy position with the buttock slightly elevated.

Iodophor cotton was placed in the vaginal speculum to clean the cervix, and the uterine cavity was expanded by 0.9% saline. The cervical canal, uterine cavity, the cornua, and finally the fundus and the

left and the right front and rear walls were explored. Physicians examined the presence or absence of the following morphologic variables: hemorrhagic spots, focal hyperemia, diffusely endometrial hyperemia, dilated endometrial vessels, endometrial polypoid hyperplasia, endometrial polyps, micropolyps, or uterine cavity mucus.

Once completed, according to hysteroscopy results, the endometrium of the corresponding site of endometrial congestion was scraped with a sharp curette to improve the accuracy of biopsy and avoid unnecessary curettage. Endometrial biopsies were obtained, through a pipelle, and sent out to the Pathology Department of the Institution. All hysteroscopy examinations were performed by experienced physicians, and hysteroscopic images were evaluated by 2 experienced physicians.

Histopathological Examination: After hysteroscopy and endometrial biopsy, the sample was preserved in 10% formalin. H&E staining and CD138 immunohistochemistry were performed on all extracted patient endometrial tissues to determine CE diagnosis. A diagnosis was determined according to the results of H&E staining diagnostic criteria. The H&E staining diagnostic criteria for CE were based on typical plasma cells seen in the endometrial stroma, laterally biased nucleus, and deeply stained cytoplasm. At high magnification, the nucleus appeared as a wheel; no CE was diagnosed if none of the aforementioned criteria were met.

Chronic endometritis diagnostic scoring: In this study, we adopted the new CE prediction scoring system that has been established by collecting clinical data and examining the possible effect of various parameters on CE. These parameters included endometrial diffuse hyperemia, focal hyperemia, hemorrhagic spots, dilatational vessels, micropolyps, polyps, and history of repeat artificial insemination failure as predictors for CE. In this scoring system, endometrial diffuse hyperemia

was scored as 4, hemorrhagic spots were scored as 2, focal hyperemia was scored as 2, dilated endometrial vessels was scored as 2, micropolyps were scored as 1, polyps were scored as 1, and history of repeat artificial insemination failure were scored as 2. The obtained scores were summed together, and then the total score ranged from 0 to 14. A score >2 was defined as diagnostic of CE.

Statistical analysis

Statistical analysis was done by SPSS v26 (IBM Inc., Armonk, NY, USA). Quantitative variables were presented as mean and standard deviation (S.D.). Qualitative variables were presented as frequency and percentage (%). Evaluation of Diagnostic Performance was performed using diagnostic sensitivity, specificity, PPV and NPV. Receiver Operating Characteristic curve (ROC-curve) analysis were performed. The area under the curve (AUC) evaluates the overall test performance (where the area under the curve $>50\%$ denotes acceptable performance and area about 100% is the

best performance for the test). A two tailed p value < 0.05 was considered statistically significant.

Results

Patients' ages ranged from 22 to 40 years, with a mean of 32.1 ± 5.58 years, the mean gravida was 1.5 ± 1.1 and the mean para was 0.8 ± 0.77 (Table, 1).

Table 2 demonstrated that the most common indication for the hysteroscopic examination was infertility (35% primary, and 40% secondary); the most common finding was diffuse endometrial hyperemia (65%). Patients' total scores ranged from 0 to 11, with a mean of 4.2 ± 2.61 . Based on the final total score, 9 patients (45%) had chronic endometritis, and 11 patients (55%) had normal/had other abnormality.

Figure 1 showed that based on the histopathological diagnosis, 13 patients (65%) had chronic endometritis and 7 patients (35%) were normal. The most common type of chronic endometritis was chronic non-specific endometritis (35%).

Table 1: Patients demographic data.

| Study patients (n = 20) | | |
|-------------------------|-----------------|----|
| Age in years | | |
| Mean \pm S.D. | 32.1 ± 5.58 | |
| Median (IQR) | 31 (26-36) | |
| Min.-Max | 22-40 | |
| | N | % |
| Gravida | | |
| 0 | 4 | 20 |
| 1 | 6 | 30 |
| 2 | 7 | 35 |
| 3 | 2 | 10 |
| 4 | 1 | 5 |
| Mean \pm S.D. | 1.5 ± 1.1 | |
| Para | | |
| 0 | 8 | 40 |
| 1 | 8 | 40 |
| 2 | 4 | 20 |
| Mean \pm S.D. | 0.8 ± 0.77 | |

Table 2: Patients clinical data.

| | Study patients (n = 20) | |
|--|-------------------------|-------|
| | N | % |
| Indication of examination | | |
| Primary infertility | 7 | 35 |
| Secondary infertility | 8 | 40 |
| Recurrent abortion | 5 | 25 |
| Ultrasound findings | | |
| Normal | 15 | 100.0 |
| Hysteroscopic findings | | |
| Diffuse endometrial hyperemia | 13 | 65 |
| Polyp | 5 | 25 |
| Focal hyperemia | 3 | 15 |
| Dilated vessels | 3 | 15 |
| Micropolyp | 7 | 35 |
| Hemorrhagic spots | 2 | 10 |
| Additional findings | | |
| Cervical polyp | 3 | 15 |
| Tubal block | 2 | 10 |
| Indented uterus by Cesarean scar | 2 | 10 |
| Subarcuate uterus | 2 | 10 |
| Septate uterus | 1 | 5 |
| Total score | | |
| Mean ± S.D. | 4.2 ± 2.61 | |
| Median (IQR) | 4 (1.5-4.5) | |
| Min.-Max | 0-11 | |
| Patients' diagnosis based on the final score | | |
| Chronic endometritis (>2) | 9 | 45 |
| Normal/had other abnormality (≤2) | 11 | 55 |

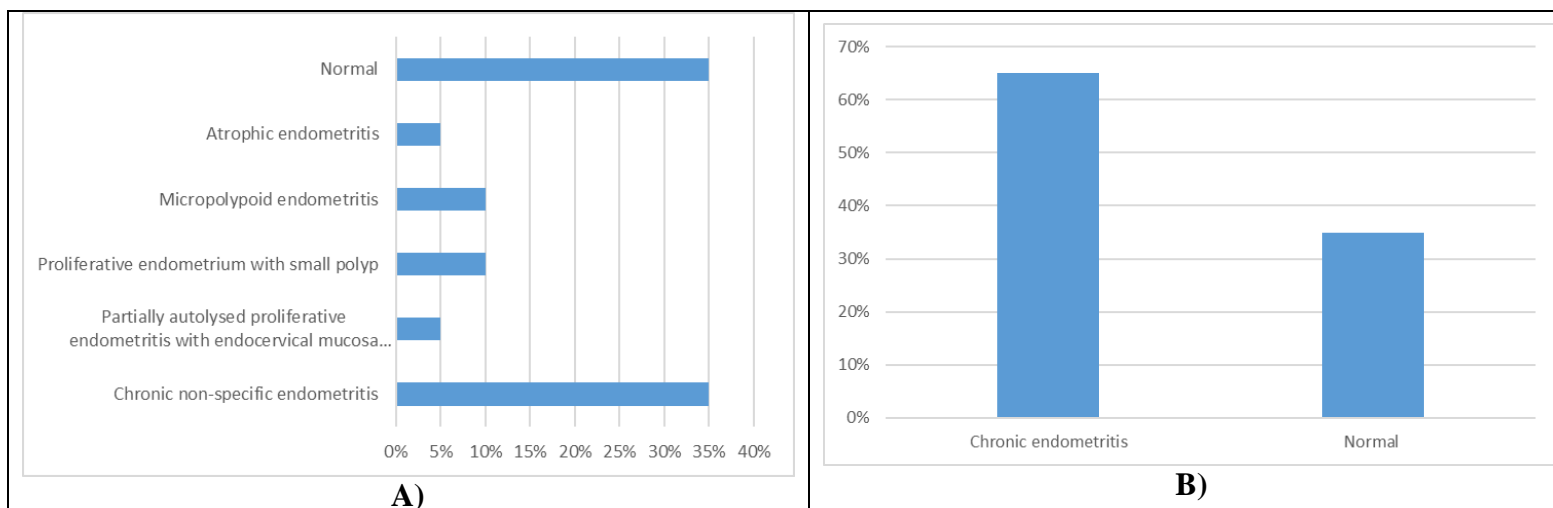


Figure 1: A) Histological type of chronic endometritis in the study patients and B) Histopathological diagnosis in the study patients.

Table 3 showed that no statistically significant difference was found between patients with and without chronic endometritis in the baseline demographic data ($p>0.05$).

Table 4 demonstrated statistically significant differences between patients

with and without chronic endometritis in the presence of diffuse endometrial hyperemia ($p=0.005$) and dilated vessels ($p=0.035$), with statistically higher scores in the group of chronic endometritis ($p=0.002$).

Table 3: Comparison between the patients in the baseline demographic data according to the histopathological diagnosis.

| | | Patients (n=20) | | | |
|--------------------------|---|-----------------|-----------------------------|-------------------|---------|
| | | Normal (n=7) | Chronic endometritis (n=13) | Test | p-value |
| Age (Mean ± S.D.) | | 33.13 ± 6.88 | 28.86 ± 4.56 | 1.39 ^a | 0.19 |
| | 0 | 2 (26.8) | 2 (15.4) | | |
| Gravida | 1 | 3 (42.9) | 3 (23.1) | | |
| N (%) | 2 | 1 (14.3) | 5 (38.5) | 3.15 ^b | 0.53 |
| | 3 | 1 (14.3) | 1 (7.7) | | |
| | 4 | 0 (0) | 1 (7.7) | | |
| Para | 0 | 2 (26.8) | 6 (46.2) | | |
| N (%) | 1 | 4 (57.1) | 4 (30.8) | 1.81 ^b | 0.41 |
| | 2 | 1 (14.3) | 3 (23.1) | | |

a: independent t-test; b: Chi square test; $p>0.05$ = statistical insignificant difference

Table 4: Comparison between the patients in the clinical hysteroscopic data according to the histopathological diagnosis.

| | | Patients (n=20) | | | |
|--|--|-----------------|-----------------------------|-------------------|---------|
| | | Normal (n=7) | Chronic endometritis (n=13) | Test | p-value |
| Indication of examination | | | | | |
| Primary infertility | | 1 (14.3) | 2 (15.4) | | |
| Secondary infertility | | 2 (26.8) | 4 (30.8) | | |
| AUB | | 3 (26.8) | 2 (15.4) | 5.63 ^a | 0.46 |
| Dyspareunia, recurrent vaginal infection | | 0 (0) | 2 (15.4) | | |
| Recurrent abortion | | 1 (14.3) | 3 (23.1) | | |
| Hysteroscopic findings | | | | | |
| Diffuse endometrial hyperemia | | 1 (14.3) | 12 (92.3) | 8.04 ^b | 0.005* |
| Polyp | | 3 (42.9) | 2 (15.4) | 0.54 ^b | 0.46 |
| Focal hyperemia | | 1 (14.3) | 2 (15.4) | 0.27 ^b | 0.61 |
| Dilated vessels | | 0 (0) | 3 (23.1) | 4.23 ^b | 0.035* |
| Micro polyp | | 2 (26.8) | 5 (38.5) | 0.6 ^b | 0.44 |
| Hemorrhagic spots | | 0 (0) | 2 (15.4) | 2.78 ^b | 0.095 |
| Additional findings | | | | | |
| Cervical polyp | | 0 (0) | 3 (23.1) | 1.32 ^b | 0.25 |
| Tubal block | | 1 (14.3) | 1 (7.7) | 0.01 ^b | 0.92 |
| Indented uterus by Cesarean scar | | 0 (0) | 2 (15.4) | 2.78 ^b | 0.095 |
| Subarcuate uterus | | 1 (14.3) | 1 (7.7) | 0.01 ^b | 0.92 |
| Septate uterus | | 0 (0) | 1 (12.5) | 1.32 ^b | 0.25 |
| Score: Median (IQR) | | 2 (1-2) | 4 (4.5-7.5) | 3.5 ^c | 0.002* |

a: independent t-test; b: Chi square test.

Figure 2 revealed that a score cutoff value of > 2 was able to diagnose chronic endometritis with an excellent performance (AUC=0.923). It showed a sensitivity of 87.5% and a specificity of 85.7% ($p=0.002$).

Table 5 shows that there was substantial agreement between the hysteroscopic diagnosis by the new scoring system and the histopathological diagnosis ($\kappa=0.792$ and $p=0.002$).

Table 5: Assessment of the agreement between the hysteroscopic diagnosis by the new scoring system and the histopathological diagnosis.

| Kappa value | p-value | Interpretation | Sensitivity | Specificity |
|-------------|---------|-----------------------|-------------|-------------|
| 0.792 | 0.002* | Substantial agreement | 92.3% | 72.4% |

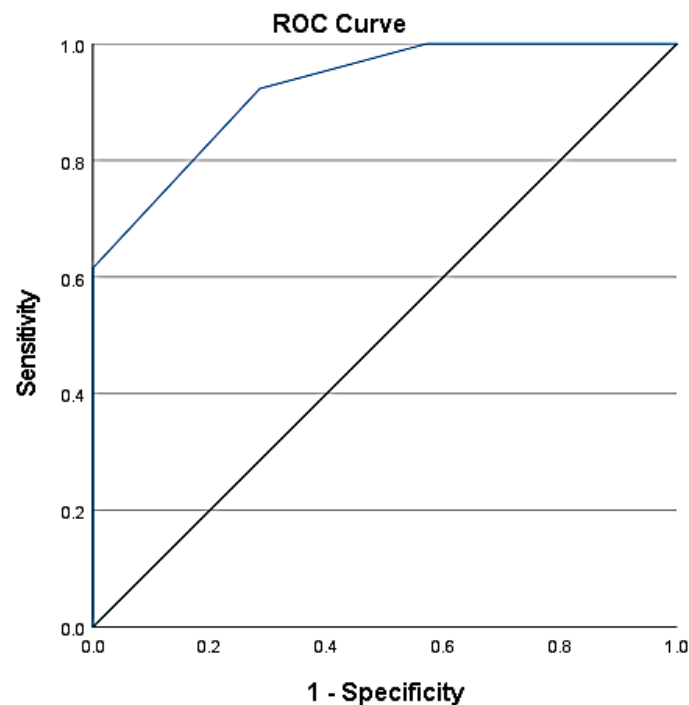


Figure 2: ROC Curve for the diagnostic performance of hysteroscopic scores in the diagnosis of chronic endometritis.

Discussion

In this study, the patients' ages ranged from 22 to 40 years, with a mean of 32.1 ± 5.58 years, with no statistically significant difference between patients with and without chronic endometritis according to age. This is in line with a previous study⁽⁹⁾, that evaluated the role of hysteroscopy in the diagnosis of chronic endometritis (CE) and found that the age of women included in the study ranged from 23-39

years with a mean of 31.8 ± 4.15 years. Also, they found no statistically significant variation in the age of women with CE. This result agreed also with another study⁽¹⁰⁾ on 256 patients. Patients were 23–40 years of age; the mean age was 31.9 ± 4.1 years and there was no statistically significant variation in the age of women with CE.

Recently, chronic endometritis (CE) was linked to embryonic transplantation failure

and infertility⁽¹¹⁾. In this study, the most common indication for the hysteroscopic examination in the current work was infertility. This is consistent with several previous studies that concluded a strong association between chronic endometritis and infertility^(12, 13). This link could be explained as chronic endometritis is a persistent inflammation of the uterine endometrial lining, which is associated with irregular uterine bleeding, and recurrent abortion. All of which would predispose to infertility.

As a minimally invasive examination method, hysteroscopy allows the direct visualization of the uterine cavity. Concerning hysteroscopic examination, the most common finding in this study was diffuse endometrial hyperemia. Statistically significant differences were found between patients with and without chronic endometritis in the presence of diffuse endometrial hyperemia and dilated vessels. Accordingly, an association between chronic endometritis and vascular changes was reported by^(14,15). In their experience, vascular modifications were sometimes associated with thrombi or fibrinoid degeneration of the vessel wall, suggesting a vasculopathy due to chronic endometritis.

In the current study, we adopted the new chronic endometritis prediction scoring system that has been established by collecting clinical and hysteroscopic data⁽¹⁶⁾. Each hysteroscopic finding was given a score, and the total scores were summed. A score >2 was defined as diagnostic of CE. The patients' total scores ranged from 0 to 11, with a mean of 4.2 ± 2.61 , with statistically higher scores in the group of pathologically proved chronic endometritis ($p=0.002$). A score cutoff value of > 2 was able to diagnose chronic endometritis with an excellent performance (AUC=0.923). It showed a sensitivity of 87.5% and a specificity of 85.7% ($p=0.002$). There was substantial agreement between the hysteroscopic diagnosis by the new scoring system and the histopathological

diagnosis ($\kappa=0.792$ and $p=0.002$). These findings ensure the excellent validity and reliability of hysteroscopic examination in the diagnosis of chronic endometritis. Similarly, previous studies have shown that hysteroscopy has a higher specificity for the diagnosis of endometritis^(10, 14). In the study of⁽⁹⁾, 84% of cases were diagnosed by hysteroscopy. Our findings are supported by the study of⁽¹⁶⁾ who reported that hysteroscopy had a high specificity and positive predictive value, implying that hysteroscopy has fewer false-positive results and a lower rate of misdiagnosis. They reported that hysteroscopic parameters including endometrial diffuse hyperemia, focal hyperemia, hemorrhagic spots, dilatational vessels, micro polyps, and polyps are predictors for chronic endometritis. They reported the same cutoff value that was found in the current work with high sensitivity and specificity.

Like all diagnostic methods, hysteroscopy has some disadvantages and limitations. In addition to being expensive and invasive, there can be complications, such as the risk of uterine perforation. The hysteroscopic experience of the physician can affect the accuracy of endometritis diagnosis.

The present study is limited by the relatively small sample size and non-follow-up after therapeutic intervention.

Conclusion

Hysteroscopy is a useful procedure with high diagnostic accuracy in patients with suspicious chronic endometritis. We adopted a new scoring system of hysteroscopic diagnostic criteria for chronic endometritis in women of reproductive age. This classification system could serve as "working formulation" and may help to standardize the terminology and diagnostic criteria for CE in clinical and research fields. From the study findings, hysteroscopy is a recommended useful diagnostic tool in

chronic endometritis screening in asymptomatic infertile women.

Sources of funding

This research did not receive any specific grant from funding agencies in the public, commercial, or not-for-profit sectors.

Author contribution

Authors contributed equally in the study.

Conflicts of interest

No conflicts of interest

References

1. Puente E, Alonso L, Laganà AS, Ghezzi F, Casarin J, Carugno J. Chronic Endometritis: Old Problem, Novel Insights and Future Challenges. *Int J Fertil Steril*. 2020;13:250-6.
2. Vitagliano A, Cialdella M, Cicinelli R, Santarsiero CM, Greco P, Buzzaccarini G, et al. Association between Endometrial Polyps and Chronic Endometritis: Is It Time for a Paradigm Shift in the Pathophysiology of Endometrial Polyps in Pre-Menopausal Women? Results of a Systematic Review and Meta-Analysis. *Diagnostics (Basel)*. 2021;11.
3. Kimura F, Takebayashi A, Ishida M, Nakamura A, Kitazawa J, Morimune A, et al. Review: Chronic endometritis and its effect on reproduction. *J Obstet Gynaecol Res*. 2019;45:951-60.
4. Espinós JJ, Fabregues F, Fontes J, García-Velasco JA, Llácer J, Requena A, et al. Impact of chronic endometritis in infertility: a SWOT analysis. *Reprod Biomed Online*. 2021;42:939-51.
5. Vitale SG, Riemma G, Alonso Pacheco L, Carugno J, Haimovich S, Tesarik J, et al. Hysteroscopic endometrial biopsy: from indications to instrumentation and techniques. A call to action. *Minim Invasive Ther Allied Technol*. 2021;30:251-62.
6. Abd-Elmageed AA-E, abdo a, el beheidy tm, Refaie aN. Office Hysteroscopy and Pipelle Endometrial Biopsy versus Dilation and Curettage in Diagnosis of Endometrial pathology in women with perimenopausal bleeding. *Zagazig University Medical Journal*. 2020;26:981-9.
7. Xu Y, Mei J, Diao L, Li Y, Ding L. Chronic endometritis and reproductive failure: Role of syndecan-1. *Am J Reprod Immunol*. 2020;84:e13255.
8. Song D, Li TC, Zhang Y, Feng X, Xia E, Huang X, et al. Correlation between hysteroscopy findings and chronic endometritis. *Fertil Steril*. 2019;111:772-9.
9. Abdelsamie AA, Bakry MS, Abou-Beih SS. Correlation between hysteroscopy finding and chronic Endometritis in Unexplained Primary Infertility. *Fayoum University Medical Journal*. 2022;10:40-50.
10. Cicinelli E, Matteo M, Tinelli R, Pinto V, Marinaccio M, Indraccolo U, et al. Chronic endometritis due to common bacteria is prevalent in women with recurrent miscarriage as confirmed by improved pregnancy outcome after antibiotic treatment. *Reprod Sci*. 2014;21:640-7.
11. Buzzaccarini G, Vitagliano A, Andrisani A, Santarsiero CM, Cicinelli R, Nardelli C, et al. Chronic endometritis and altered embryo implantation: a unified pathophysiological theory from a literature systematic review. *J Assist Reprod Genet*. 2020;37:2897-911.
12. Wang S, Li F, Zhang W, Sui X, Hao C. Investigation of the Relationship between Chronic Endometritis Manifestations under Hysteroscope and CD138 Expression. *Appl Bionics Biomech*. 2022;2022:8323017.
13. Vitagliano A, Laganà AS, De Ziegler D, Cicinelli R, Santarsiero CM, Buzzaccarini G, et al. Chronic Endometritis in Infertile Women: Impact of Untreated Disease, Plasma Cell Count and Antibiotic Therapy on IVF Outcome-A Systematic Review and Meta-Analysis. *Diagnostics (Basel)*. 2022;12.
14. Cicinelli E, Vitagliano A, Kumar A, Lasmar RB, Bettocchi S, Haimovich S. Unified diagnostic criteria for chronic endometritis at fluid hysteroscopy: proposal and reliability evaluation through an international randomized-controlled observer study. *Fertil Steril*. 2019;112:162-73.e2.
15. Carvalho FM, Aguiar FN, Tomioka R, de Oliveira RM, Frantz N, Ueno J. Functional endometrial polyps in infertile asymptomatic patients: a possible evolution of vascular changes secondary to endometritis. *Eur J Obstet Gynecol Reprod Biol*. 2013;170:152-6.
16. Liu H, Song J, Zhang F, Li J, Kong W, Lv S, et al. A New Hysteroscopic Scoring System for Diagnosing Chronic Endometritis. *J Minim Invasive Gynecol*. 2020;27:1127-32.

To cite this article: Mohamed F. Elsherbeny, Mohamed I. Mohamed, Mariam M. Frazily, Shreen N. Abo El Ezz. New Hysteroscopic View in Chronic Endometritis. *BMFJ XXX*, DOI: 10.21608/bmfj.2024.207156.1804.