

## Is Ultrasound Adding Values to Voiding Cystourethrogram in Pediatric Vesico Ureteric Reflux?

Hamada M. Khater, Asmaa A. Ali, Enas M. Sweed

Radiology Department, Faculty of Medicine Benha University, Egypt.

**Corresponding to:**

Dr. Asmaa A. Ali.  
Radiology Department, Faculty of Medicine Benha University, Egypt.

**Email:**

Asmaaalia48@gmail.com

**Received:** 18 November 2023

**Accepted:** 9 December 2023

**Abstract:**

**Background:** Renal injury is a severe consequence of vesicoureteral reflux (VUR). Although voiding cystoureterography (VCUG) is considered the gold standard procedure for diagnosis, it is too little concern invasive technique and has a significant radiation risk. It is recommended to use ultrasonography as a screening technique to determine whether VUR is present. The aim of this study was to estimate the appropriate role and indication for ultrasonography in the context of VUR disease and to compare the results with the gold standard, VCUG. **Methods and patients:** This cross-sectional study included 100 recurrent urinary tract infection (UTI) children who were referred to the radiology department, Benha University Hospital, and the pediatric hospital between January 2023 and September 2023. Every patient had a complete medical history and radiographic, as well as a radiological assessment that included an ultrasound and VCUG. **Results:** 78% of cases were identified by ultrasound, whereas 32% of patients with VUR in ascending VCUG were not identified by ultrasonography. Compared to low grade VUR, the percentage of high grade VUR patients with increased renal size, increased echogenicity, dilated ureters, thicker ureteral wall, prominent renal pelvis, and thicker pelvic wall was much higher. After evaluating ultrasound's diagnostic potential using receiver operating characteristic (ROC) curve, it was discovered that US had 100% specificity and 78.5% sensitivity for identifying VUR instances. **Conclusion,** ultrasound offer better evaluation renal size parenchymal thickness and scarring and degree of hydronephrosis and follow up with treatment. **Keywords:** Ultrasound, VCUG, VUR.

---

## Introduction

Vesicoureteral reflux is considered a serious health concern due to the increased risk of kidney damage in cases of high-grade vesicoureteral reflux. It has been observed that the general population has a prevalence of vesicoureteral reflux ranging from 0.4 to 2%. The majority of reflux cases are found after doing a preliminary screening for urinary tract infections <sup>(1)</sup>.

Due to incompetent valve mechanism, the ureterovesical junction (UVJ) permits urine to pass into the bladder and blocks retrograde flow towards the kidneys. Urine flows backward and toward the upper urinary tract when there are abnormalities in the UVJ, or the bladder's three-dimensional structure <sup>(2)</sup>.

To diagnose and grade VUR, a variety of imaging techniques are available, such as contrast-enhanced voiding urosonography, radionuclide cystography (RNC), and voiding cystourethrogram <sup>(3)</sup>.

Because it provides a comprehensive picture of the urinary tract from the kidney to the urethra, voiding cystoureterography is regarded as the gold standard. Catheterization and radiation exposure are the two most significant side effects of voiding cystoureterography. While less intrusive exams than voiding cystoureterography must be pursued, voiding cystoureterography is absolutely necessary to demonstrate the unquestionable backflow of urine from the bladder into the ureters and/or renal pelvises. Before surgery, urologists would rather examine the entire urinary tract, not just a portion of it <sup>(4)</sup>.

As a non-invasive, radiation-free screening method, US may be a great fit. Renal parenchymal thickness and kidney

diameters indicate chronic kidney disease, and US can show the typical calyceal and ureteral dilatation of vesicoureteral reflux. Additionally, it is useful in the differential diagnosis of ureteropelvic junction (UPJ) stenosis and bladder ureterocele <sup>(5)</sup>.

The purpose of this research was to estimate the appropriate function and additive value for using ultrasound (US) in the vesicoureteral reflux and to compare the results with the gold standard, VCUG.

---

## Patients and methods

This cross-sectional study included one hundred children with recurrent urinary tract infection who were referred to the radiology department, Benha University Hospital, and the pediatric hospital between January 2023 and September 2023.

Ethical approval code & number: MS.2-11-2022

Children having congenital or acquired urogenital malformations, children undergoing surgery for urinary tract pathology, and children lacking a simultaneous US and voiding cystoureterography examination are the exclusion criteria.

Each kid participant in the study had their parents or legal guardian provide their informed permission. Every patient had a complete medical history taken, as well as a radiological assessment that included an ultrasound and voiding cystoureterography.

Voiding cystoureterography was performed using a Philips Primary Diagnostics (Model AR/704310, India) reflux analyzer, two pediatric radiologists with experience in the field 15 and 10 years, evaluated reflux cases. Renal US was always performed prior to voiding

cystography, and the reader was blinded to the renal US findings when assessing the findings. Under umbrella of antibiotic, an 8-F soft plastic nonballoon catheter that is flexible was used to catheterize the bladder, and it was taped into place under aseptic condition.

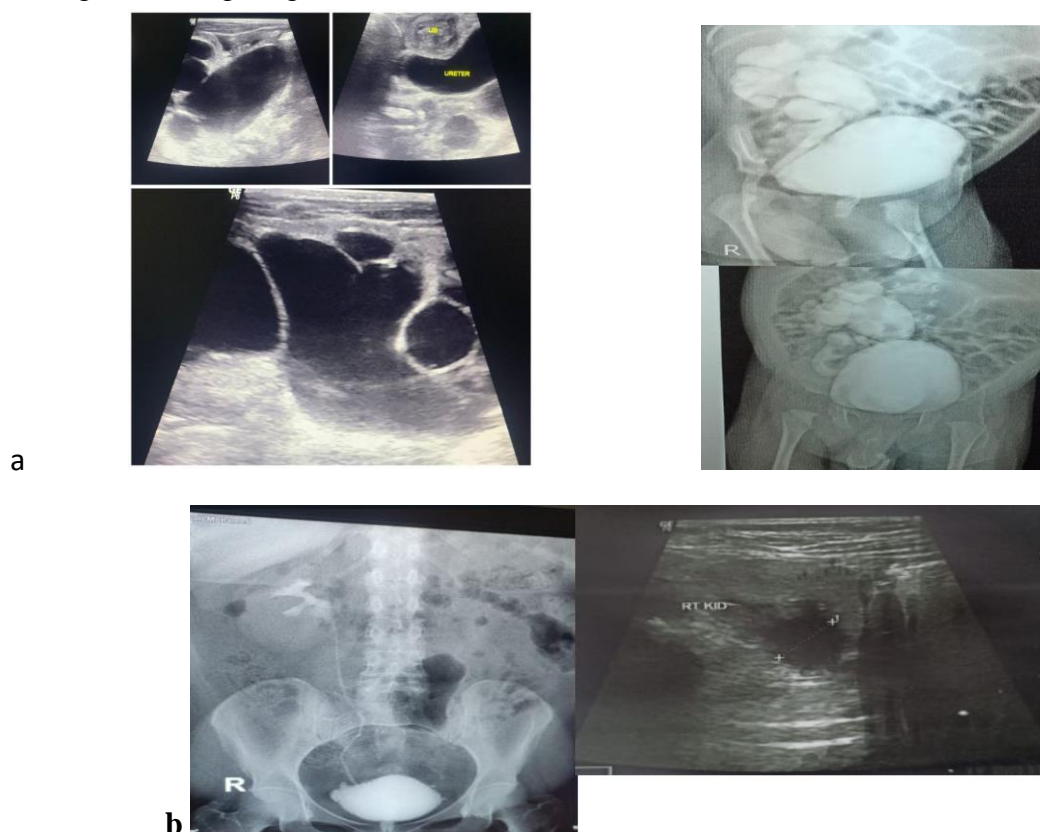
After that, the patient was subsequently placed in supine position ainoxilate sodium(Télébrix 12 Sodium, 120 mg of iodine per milliliter; Guerbet, Aulnaysous-Bois, France) instill the contrast according to the bladder capacity of the patient ,for children(age+2)x30 in ml

The contrast was then instilled by means of gravity from a height of no more than one meter above the fluoroscopy tabletop. with the patient in a supine position. Intermittent fluoroscopy was performed during the filling stage to detect VUR or

other abnormalities. A spot image of the filled bladder was normally obtained.

Young toddlers and newborns will void on their own when their bladders are full enough. The older kids were told to use the urinal when they felt full, with the boys using a left anterior oblique position over a urinal and the girls lying supine on a bedpan.

Before and during voiding, spot pictures of the bladder and urethra were taken, with the catheter either withdrawn or lost. To measure post voiding volume and reflux, a picture of the bladder and renal fossae was acquired after voiding. The children who were not toilet trained underwent three cycles of filling and voiding, while the patients from the continent underwent only one round (Figure 1).



**Figure 1: a-** VCUG showed Rt. VUR tortuous ureter sever dilatation of ureter and pelvicalyceal system hydronephrosis with loss of fornix and papillary impression. US showed Rt. hydronephrosis dilated pelvicalyrcal system dilated ureter decrease parenchymal thickness, **b-** VCUG showed Rt, grade 3 VUR with mild to moderete dilatation of pelvicalyceal system and US showed mild hydronephrosis dilated renal pelvis.

The International Reflux Study Classification <sup>(6)</sup> assigned a VUR classification of 0 to 5. The voiding cystoureterography results were classified as follows: Grade 0, no reflux. Grade II: normal fornices in the ureter, pelvis, and calyces; Grade I: just dilation of the ureters; Grade IV: mild dilatation of the renal pelvis and calyces together with significant ureter dilatation and/or tortuosity; In Grade III, there is no or very little blunting of the fornices, mild to moderate renal pelvic dilatation, and mild to moderate ureter dilatation and/or tortuosity; Gross dilatation and tortuosity of the ureter, gross dilatation of the renal pelvis, and vanishing papillary impressions in most of the calyces are all evident in Grade V.

The same pediatric radiologist did US on every patient. Renal US was carried out with Logic 6 apparatus (Ge, USA) using convex probe 5 MHZ and Linear probe 10-12 MHZ for better resolution. All US examinations were conducted by the pediatric radiologists employing sector, linear high-resolution transducers. The renal US examination took ten minutes or more, more if the youngster required to be calmed down beforehand. While the children who were not toilet trained were

bottle fed shortly before and during the examination to fill their bladders, the toilet-trained children were instructed to come with a full bladder.

The patients were either supine or prone when they were scanned for; renal size for age and/or the maximum difference in length between the two kidneys was less than 1 cm, ureteral hypoechogenicity at

any of its diameter, ureteric dilatation was evident. On transverse mid-kidney US images, pelvic measures were taken at the broadest part of each renal pelvis. The pelvic measurement was initially examined as a continuous measure before being dichotomized using the 5 mm threshold that was previously used to determine pelvic dilatation.

As previously stated, ureteral and/or pelvic dilatation was defined as the presence of urinary tract dilatation if the pelvic diameter was higher than or equal to 5 mm and/or the ureter was visible at renal US. Additionally, we used the difference in echogenicity between the kidney cortex and the medulla to evaluate abnormal corticomedullary differentiation, and it was scored as a binary variable.

Children who do not have pediatric radiologists perform their US tests or whose US reports are incomplete were not included in the study.

The Statistical Package for Social Science v26 (IBM Inc., Armonk, NY, USA) was used to gather and input data into the computer (Released 2012). Voiding cystoureterography as a reference method was used to assess the diagnostic ability of US. When the likelihood of mistake is less than 5% (P value  $\leq 0.05$ ), the results are deemed significant.

---

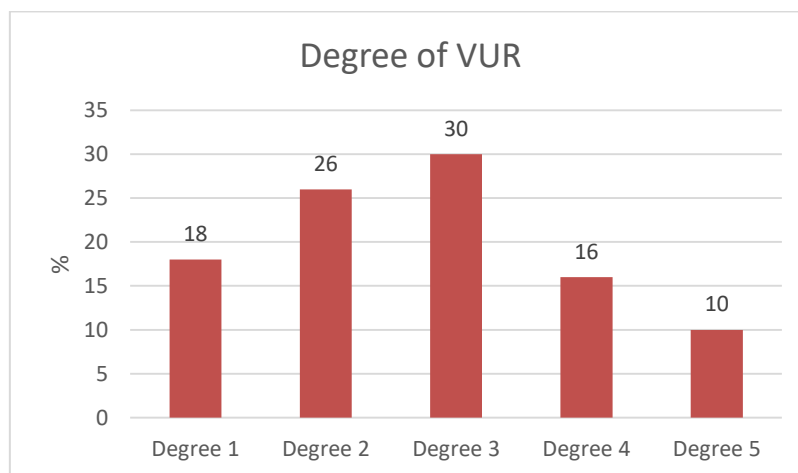
## Results:

In terms of demographic information, Table 1 shows that 46% of patients were male and 54% were female, with an average age of  $37.9 \pm 33.4$  months.

According to the voiding cystoureterography vesicoureteral reflux grading system, the majority of patients had VUR degrees 3 (30%), 2 (26%), 4 (16%), 1 (18%), and 5 (10%) (Figure 2).

**Table 1:** Information about the included patients' demographics

Demographic data		All patients (N = 100)	
		N	%
Gender	Male	46	46
	Female	54	54
Age (month)	Mean ± SD	37.9±33.4	



**Figure 2:** Bar chart showing VUR degree among patients.

After allocating the study patients according to US findings, we discovered that 14%, 10%, 44%, 58%, 58%, 52%, and 46% of the included patients had enhanced renal size, increased echogenicity, dilated ureters, ureteral wall thickening, prominent renal pelvis, and pelvic wall thickening, respectively (Figure 3).

When comparing the results of the VCUG and US tests for the patients under study, it was found that aberrant results were found in 44.4%, 61.5%, 93.3%, 100%, and 100% of the cases in grades I, II, III, IV, and V, respectively (Figure 4).

After evaluating the correlations between high-Grade vesicoureteral reflux and US Criteria, it was discovered that VUR Grade  $\geq 3$  had significantly higher values of

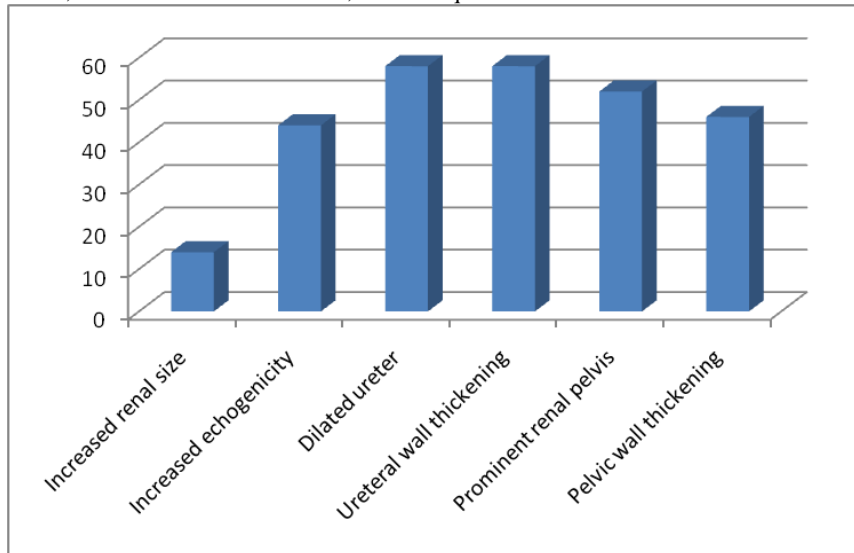
enhanced size of the kidney, enhanced echogenicity, dilated ureter, ureteral wall thickening, prominent renal pelvis, and pelvic wall thickening than VUR Grade  $< 3$  (Table 2).

When US was evaluated for its capacity to discriminate, it discovered that for VUR instances, US had a sensitivity of 78.5%, a specificity of 100%, and an overall accuracy of 80% (Table 3) (Figure 5). Additionally, degree I, degree II, degree III, degree IV, and degree V ultrasonography results indicated sensitivity of 44.4%, 61.5%, 93.3%, 100%, and 100%, respectively, for identifying various vesicoureteral reflux grades (Table 4).

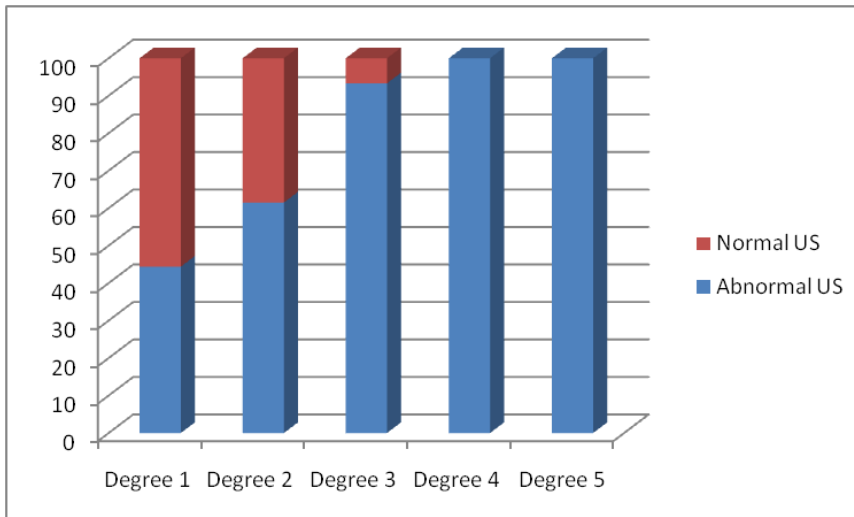
**Table 2:** Connections between US Criteria and High-Grade VUR.

Criterion	VUR Grade $\geq 3$ (No=44)	VUR Grade $\geq 3$ (No.= 56)	X <sup>2</sup>	P-value
Increased renal size (mm)	2 (4.5%)	12 (21.4 %)	5.8	0.016*
Increased echogenicity (mm)	4 (9.1%)	40 (75.0%)	38.9	0.00*
Dilated ureter (mm)	24 (44.5%)	50 (89.3%)	26.5	0.00*
Ureteral wall thickening (mm)	24 (44.5%)	48 (85.7%)	26.5	0.00*
Prominent renal pelvis(mm)	14(31.8%)	38 (67.9%)	12.8	0.00*
Pelvic wall thickening (mm)	14 (31.8%)	32 (57.1 %)	6.4	0.012*

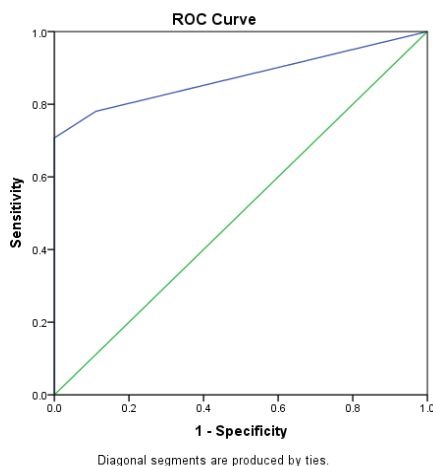
\*: significant difference, **VUR:** Vesicoureteral reflux, X<sup>2</sup>: Chi square



**Figure 3:** Renal US Criteria among the studied population.



**Figure 4:** Renal ultrasonography categorized according to vesicoureteral reflux (VUR) degree.



**Figure 5:** ROC of US for prediction of VUR

**Table 3:** Validity of ultrasonography in differentiating cases of VUR.

Score	AUC	p-value	Sensitivity (%)	Specificity (%)	95% CI	PPV (%)	NPV (%)
US	0.874	0.001*	78.5	100	0.78-0.97	78	88.9

AUC: Area under curve, CI: Confidence interval, NPV: Negative predictive value. , PPV: Positive predictive value, US: Ultrasound.

**Table 4:** The sensitivity of ultrasound for diagnosing different VUR grades.

Sensitivity of VUR on Ultrasonography	
Degree 1	44.4%
Degree 2	61.5%
Degree 3	93.3%
Degree 4	100%
Degree 5	100%

VUR: vesicoureteral reflux.

### Discussion:

Conventional diagnostic techniques such as voiding cystoureterography are not appropriate for screening due to their significant radiation risk (7).

As a non-invasive, radiation-free screening method, US may be a great fit. Nevertheless, numerous studies have indicated that its sensitivity is insufficient to provide a conclusive diagnosis on its own (8). In addition to kidney diameters and renal parenchymal thickness that indicate chronic, irreversible renal impairment, US has the ability to show

calyceal and ureteral dilatation, which are hallmarks of vesicoureteral reflux. Also, it is useful in the differential diagnosis of ureteropelvic junction stenosis and bladder ureterocele (5).

According to the current survey, the percentages of males and females were 46% and 54%, respectively. According to a prior study, males made up 34.3% of the instances, while females made up 65.7% of the patients. The writers demonstrated that females have a greater frequency of illness. According to available data, incidence rises in girls beyond boys after the first few months of life. This alteration

suggests that the pathophysiology of vesicoureteral reflux is complex, as while it is a congenital condition in infants, it can also be acquired, especially in females, most likely as a result of bladder dysfunction <sup>(9)</sup>.

Increased renal size, increased echogenicity, dilated ureter, ureteral wall thickening, prominent renal pelvis, and pelvic wall thickening were all significantly higher in vesicoureteral reflux more than and equal to Grade 3 than in VUR less than Grade 3, according to an assessment of the relationships between High-Grade vesicoureteral reflux and renal US Criteria.

According to a prior study, 30 out of 40 children (75%) had structural abnormalities that were diagnosed, and US was abnormal in 120 patients (41%). Out of 14 kids with reflux ranging from grade IV to V, 12 (86%), had abnormal US results. In most cases, VUR grade III was overlooked. As a result, the US found fewer cases, despite the fact that this method is very accessible, noninvasive, and radiation-free <sup>(10)</sup>.

According to a different study, vesicoureteral reflux on voiding cystoureterography is not predicted by ultrasonography findings. Additionally, some kids with higher grade vesicoureteral reflux by voiding cystoureterography — including some with grade III and two with grade IV reflux—were not picked up by renal ultrasonography. Accordingly, it is proposed that, in the absence of renal ultrasonography abnormalities, a voiding cystoureterography is required to rule out vesicoureteral reflux <sup>(11)</sup>.

Another study that found a substantial improvement in sensitivity between grade III and grade IV or grade V vesicoureteral reflux (47% vs. 76% and 47% vs. 91%),

suggests that ultrasonography would be a valuable diagnostic tool for predicting grade IV or grade V vesicoureteral reflux. Another helpful diagnostic method for screening is ultrasound. Consequently, although though it might not be a very effective diagnostic tool for predicting vesicoureteral reflux when multiple reflux grades are assessed simultaneously (categories of I–V, II, and III), ultrasonography is a good diagnostic test for predicting grade IV and V vesicoureteral reflux <sup>(12)</sup>.

The current study found a substantial difference in the percentage of dilated ureters, increased renal size, higher echogenicity, and thicker ureteral wall, conspicuous renal pelvis, and pelvic wall thickening between high grade vesicoureteral reflux and low-grade vesicoureteral reflux.

According to a prior study, ureteral dilatation has a high specificity to reduce the number of needless cystographic operations performed and a high sensitivity to ensure that few children with high-grade vesicoureteral reflux would be missed. In most cases, there was very little danger of kidney injury when children with high-grade vesicoureteral reflux who were given the wrong diagnosis had cystography at the time of their second urinary tract infection because this criterion's sensitivity was less than 100% <sup>(13)</sup>.

A prior study retrospectively evaluated the renal ultrasound and voiding cystoureterography results of 162 children under 5 years old who had their first episode of urinary tract infection in order to investigate the dilatation of the collecting system on renal ultrasonography in predicting VUR in children with urinary tract infection or other urinary tract issues.



According to their claims, ultrasound had a sensitivity and specificity of just 40% and 76%, respectively, in predicting vesicoureteral reflux <sup>(11)</sup>.

It is unknown from previous research why renal ultrasonography results are not sensitive enough to identify VUR in kids experiencing their first urinary tract infection episode. While dilatation of the renal pelvis in that study shown limited sensitivity in identifying VUR, it also demonstrated excellent specificity and a large odds ratio of indicators for severe reflux, suggesting that VUR had nevertheless played a role in the dilatation of the pelvis to some extent. According to several accounts, VUR is a dynamic and sporadic condition, which makes routine renal ultrasonography insensitive for detecting reflux. It's also possible that certain children's low-grade VUR was overlooked by ultrasound investigations <sup>(14)</sup>.

Our goal in evaluating the renal US's diagnostic accuracy was not to prove that the test could completely replace cystography with 100% sensitivity and high specificity, but rather to suggest an evidence-based approach that fell somewhere between a wait-and-see approach and systematic cystography <sup>(15)</sup>.

In the current investigation, we discovered that US had 100% specificity and 78.5% sensitivity for differentiating VUR. According to a different investigation, the negative predictive value and sensitivity of the US for reflux were discovered to be, respectively, 86.18% and 79.45% <sup>(16)</sup>. The literature reports a wide range of sensitivity and negative predictive value for US, ranging from 16–40% for VUR to 25–86% for sensitivity <sup>(17)</sup>.

The current study's analysis of ultrasonography's sensitivity for

diagnosing vesicoureteral reflux showed that, for grade I, II, III, IV and V, the corresponding percentages of accuracy for US were 44.4%, 61.5%, 93.3%, 100%, and 100%, respectively.

According to one study, the sensitivity of US for reflux was 63% <sup>(10)</sup>, while other study found that the sensitivity was 42% and 86% for high- and low-grade reflux, respectively. In our study group, 98 kidneys had high grade reflux; only 6 (6.1%) of these kidneys were not pathogenic in the US <sup>(18)</sup>.

This demonstrates how the US can serve as a reference for the voiding cystoureterography exam. Compared to our numbers, the number of patients with high grade reflux in earlier trials was very small <sup>(11,12)</sup>.

Another study highlighted the potential for a delay in diagnosing grade 4-5 reflux with a normal US, indicating that the US should not be used as a vesicoureteral reflux screening tool <sup>(18)</sup>.

In line with earlier studies that assert that US's low sensitivity and negative predictive value preclude its use as a stand-alone screening tool for vesicoureteral reflux. Our results were more clearly described than those seen in the literature <sup>(17,19)</sup>.

Previous authors explained that the study's good diagnostic ability was due to a number of factors, including the fact that all US examinations were conducted by the same pediatric radiologist, detailed descriptions of kidney size, parenchymal features, bladder and ureter status, and exclusion of non-detailed US examinations <sup>(16)</sup>.

---

## Conclusion:

Ultrasound offer better evaluation renal size parenchymal thickness and scaring

and degree of hydronephrosis and follow up with treatment. So, a skilled radiologist's ultrasound examination would serve as a reference for the voiding cystoureterography indication in the vesicoureteral reflux diagnostic. Thus, it is possible to spare certain kids from needless radiation exposure.

**Conflict of interest:**

None of the contributors declared any conflict of interest.

---

**References:**

1. Chang JW, Liu CS, Tsai HL. Vesicoureteral Reflux in Children with Urinary Tract Infections in the Inpatient Setting in Taiwan. *Clin Epidemiol.* 2022; 14:299-307. doi: 10.2147/CLEP.S346645.
2. Tokhmafshan F, Brophy PD, Gbadegesin RA, Gupta IR. Vesicoureteral reflux and the extracellular matrix connection. *Pediatr Nephrol.* 2017; 32(4):565-576. doi: 10.1007/s00467-016-3386-5.
3. Cajigas-Loyola S, Chow J, Hayatghaibi S, Iyer R, Kwon J, Rubesova E, et al. Imaging of Vesicoureteral Reflux: AJR Expert Panel Narrative Review. *AJR. American journal of roentgenology.* 2023. doi: https://doi.org/10.2214/AJR.23.29741
4. Johnin K, Kobayashi K, Tsuru T, Yoshida T, Kageyama S, Kawauchi A. Pediatric voiding cystourethrography: An essential examination for urologists but a terrible experience for children. *Int J Urol.* 2019; 26(2):160-171. doi: 10.1111/iju.13881.
5. Adibi A, Gheysari A, Azhir A, Merikhi A, Khami S, Tayari N. Value of sonography in the diagnosis of mild, moderate and severe vesicoureteral reflux in children. *Saudi J Kidney Dis Transpl.* 2013; 24(2):297-302. doi: 10.4103/1319-2442.109582.
6. Lebowitz RL, Olbing H, Parkkulainen KV, Smellie JM, Tamminen-Möbius TE. International system of radiographic grading of vesicoureteric reflux. *International Reflux Study in Children. Pediatr Radiol.* 1985;15(2):105-9. doi: 10.1007/BF02388714.
7. Fallah MM, Falahati M, Mohammadi A, Alizadeh M, Mladkova-Suchy N, Ghasemi-Rad M. Comparative study of color Doppler voiding urosonography without contrast enhancement and direct radionuclide voiding cystography for diagnosis of vesicoureteric reflux in children. *J Ultrasound Med.* 2012; 31(1):55-61. doi: 10.7863/jum.2012.31.1.55.
8. Shaikh N, Spingarn RB, Hum SW. Dimercaptosuccinic acid scan or ultrasound in screening for vesicoureteral reflux among children with urinary tract infections. *Cochrane Database Syst Rev.* 2016; 7(7):CD010657. doi: 10.1002/14651858.CD010657.pub2.
9. Teixeira CB, Cançado MA, Carvalhaes JT. Primary vesicoureteral reflux: conservative therapy or surgical intervention. *J Bras Nefrol.* 2014;36(1):10-7. Portuguese. doi: 10.5935/0101-2800.20140004.
10. Preda I, Jodal U, Sixt R, Stokland E, Hansson S. Value of ultrasound in evaluation of infants with first urinary tract infection. *J Urol.* 2010; 183(5):1984-8. doi: 10.1016/j.juro.2010.01.032.
11. Mahant S, Friedman J, MacArthur C. Renal ultrasound findings and vesicoureteral reflux in children hospitalised with urinary tract infection. *Arch Dis Child.* 2002; 86(6):419-20. doi: 10.1136/adc.86.6.419.
12. Kovanlikaya A, Kazam J, Dunning A, Poppas D, Johnson V, Medina C et al. The role of ultrasonography in predicting vesicoureteral reflux. *Urology.* 2014; 84(5):1205-10. doi: 10.1016/j.urology.2014.06.057.
13. Leroy S, Vantalou S, Larakeb A, Ducou-Le-Pointe H, Bensman A. Vesicoureteral reflux in children with urinary tract infection: comparison of diagnostic accuracy of renal US criteria. *Radiology.* 2010; 255(3):890-8. doi: 10.1148/radiol.10091359.
14. Tsai YC, Hsu CY, Lin GJ, Wang CJ, Cheng CH, Huang YH, et al. Vesicoureteral reflux in hospitalized children with urinary tract infection: the clinical value of pelvic ectasia on renal ultrasound, inflammatory responses and demographic data. *Chang Gung Med J.* 2004; 27(6):436-42. PMID: 15455544.
15. Coulthard MG. NICE on childhood UTI: Nasty processes produce nasty guidelines. *BMJ.* 2007; 335(7618):463; author reply 463-4. doi: 10.1136/bmj.39325.436667.3A.
16. Dogan GM, Sığircı A, Elmas AT, Tabel Y. The role of ultrasound in the diagnosis of vesicoureteral reflux disease. *J Surg Med.*

- 2022;6(1):102-105. DOI: 10.28982/josam.1023251
17. Massanyi EZ, Preece J, Gupta A, Lin SM, Wang MH. Utility of screening ultrasound after first febrile UTI among patients with clinically significant vesicoureteral reflux. *Urology*. 2013; 82(4):905-9. doi: 10.1016/j.urology.2013.04.026.
18. Suson KD, Mathews R. Evaluation of children with urinary tract infection--impact of the 2011 AAP guidelines on the diagnosis of vesicoureteral reflux using a historical series. *J Pediatr Urol*. 2014; 10(1):182-5. doi: 10.1016/j.jpuro.2013.07.025.
19. Nelson CP, Johnson EK, Logvinenko T, Chow JS. Ultrasound as a screening test for genitourinary anomalies in children with UTI. *Pediatrics*. 2014; 133(3):e394-403. doi: 10.1542/peds.2013-2109.

**To cite this article:** Hamada M. Khater, Asmaa A. Ali, Enas M. Sweed. Is Ultrasound Adding Values to Voiding Cystourethrogram in Pediatric Vesico Ureteric Reflux? *BMFJ* 2024;41(7):48-58.