

Comparing Ultrasonography with True Fast Imaging with Steady State Precession MRI Images in Assessment of Femoro-Trochlear Cartilage in Anterior Knee Pain

Hamada M. khater, Asmaa M. Azab, Sherif A. Abd Elsattar

Abstract:

Background: Knee pain is a common complaint among individuals, and accurate diagnosis of the underlying pathology is essential for appropriate management. Ultrasonography has emerged as a promising imaging modality for evaluating knee pathologies due to its accessibility, cost-effectiveness, and real-time imaging capabilities. This study aimed to compare ultrasonography with true fast imaging with steady state precession MRI images in assessment of femoro-trochlear cartilage in anterior knee pain. **Methods:** This cross-sectional observational study included patients with anterior knee pain. Complete history taking, general clinical examination, and NPRS assessment- were performed. Ultrasonography of the affected knee joint was conducted using a linear probe (7-12 MHz Logiq P5). Subsequently, true fast imaging with steady state precession MRI images of the same patients- was analyzed. **Results:** The study included patients with a mean age of 34.85 years, with 57.7% being females. Ultrasonography and MRI findings were categorized based on severity and associated features. Positive and negative predictive values, as well as sensitivity and specificity- were calculated for each finding. The results demonstrated significant agreement between ultrasonography and MRI findings, with notable sensitivity and specificity values for most categories. **Conclusion:** The study revealed that ultrasonography and MRI exhibit distinct strengths in detecting femoro-trochlear cartilage abnormalities. Ultrasonography demonstrated high positive predictive values in most findings, while MRI exhibited excellent specificity. Sensitivity varied between the two modalities for different cartilage grades. Both techniques demonstrated overall agreement in identifying cartilage structural changes, albeit with varying diagnostic performance in specific grades.

Keywords: Ultrasonography, True Fast Imaging, MRI; Femoro-trochlear Cartilage, Anterior Knee Pain.

Radiology Department, Faculty of Medicine Benha University, Egypt.

Corresponding to:

Dr. Asmaa M. Azab.

Radiology Department, Faculty of Medicine Benha University, Egypt.

Email: asmaamaher847@gmail.com

Received:

Accepted:

Introduction

Articular cartilage is a unique and multifaceted tissue, well adapted to bearing compressive loads and significant shear forces throughout a synovial joint's range of motion ⁽¹⁾.

Description of the lesion is based on accurate notation of the location (MFC, LFC), size (i.e., surface area), shape (circular, rectangular) and description of the walls (contained, partially contained or opened) ⁽²⁾.

High resolution ultrasound proved to be a reliable and valid radiological tool for evaluation of femoral cartilage thickness. Articular cartilage appears in ultrasound as homogeneously anechoic structure with sharp interface with bone ⁽³⁾.

MRI, with its excellent soft-tissue contrast, is the best imaging technique currently available for the assessment of articular cartilage. Imaging regions of cartilage damage has the potential to provide morphologic information, such as fissuring and the presence of partial- or full-thickness cartilage defects ⁽⁴⁾.

2D MRI sequences such as Turbo Spin Echo (TSE) methods provide excellent signal-to-noise, good contrast between tissues in the knee articular cartilage and high in-plane spatial resolution. However, those sequences suffer from some limitations. First, because of using a slice thickness of about 3mm, they suffer from partial-volume artifacts. Second, the difficulty to evaluate oblique and small structures because cartilage is a thin layer with a complex surrounding anatomical structure such as ligaments and tendons which are oriented oblique and difficult to assess with 2D sequences ⁽⁵⁾.

3D high-resolution imaging is suggested to be an alternative of 2D imaging, since it provides isotropic or nearly isotropic 3D imaging which can be reconstructed in any desired orientation with contiguous thin slices in order to reduce partial volume artifact effects. The use of multi-channel extremity coils at higher field strengths

provides higher signal and contrast to Noise ratio, which allow acquiring isotropic images at short scanning time. In addition, using auto-Align technique, this type of sequence allows good reproducibility especially in case of follow-up treatment after an injury or cartilage repair or when a reproducible location is required ⁽⁶⁾.

True fast imaging with steady state precession (TRUFISP) MRI, in Siemens Healthcare- is an efficient, high-signal method for obtaining 3D MR images. With recent advances in MR gradient hardware, TRUFISP sequence can be used without being affected by banding or off-resonance artifacts that were previously a problem with this method. However, banding artifacts due to off-resonance are still an issue as TR increases or at 3 T. Hence, TR is usually kept below 10 milliseconds with these techniques, which limits overall image resolution. Multiple-acquisition TRUFISP can be used to achieve higher resolution at the cost of additional scanning time ⁽⁷⁾.

Several studies have shown the utility of the TRUFISP sequence for imaging articular cartilage. Because of the bright synovial fluid and 3D nature of the acquisition, TRUFISP may also be useful for imaging internal derangements of other structures including ligaments and menisci ⁽⁸⁾.

The purpose of this study was to compare ultrasonography with true fast imaging with steady state precession MRI images, in assessment of femoro-trochlear cartilage in anterior knee pain.

Patients and methods

This cross-sectional observational study included 52 patients with anterior knee pain who were admitted to the Radiology Department at Benha University Hospitals from July 2022 to July 2023, meeting the inclusion criteria and consenting to participate.

The study was approved by the Research Ethic Committee of Benha Faculty of

Medicine. Research ethics committee: Ms.6.6.2022. Informed consents were taken from all participants or their parents before the start of the study.

Inclusion criteria were patients with anterior knee pain, regardless of sex, aged above 12 years old.

Exclusion criteria were absolute criteria such as the presence of a pacemaker, cochlear implants, intraocular metallic foreign body, or aneurysmal clips. Relative exclusion criteria included shell injury or metallic foreign body away from vital organs and major vessels, especially after 6 months post-injury, claustrophobia, pregnancy, and uncontrollable movement. All participants underwent the following assessments:

- I) Detailed history taking, including documenting the onset, course, duration, and relation of the disease to stress. History of trauma, systemic diseases (e.g., liver diseases, diabetes mellitus, hyperlipidemia, or hypertension), drug intake, previous hospital admission, and family history of a similar condition -were also recorded.
- II) Full clinical examination, including vital signs such as pulse, blood pressure, capillary filling time, respiratory rate, and temperature.
- III) Numerical Pain Rate Scale (NPRS) to evaluate the severity of pain, categorized as; slight pain (NPRS 0-3), moderate pain (NPRS 4-6), and severe pain (NPRS 7-10).
- IV) Routine laboratory investigations, including complete blood count, random blood sugar, kidney function tests, and liver function tests.
- V) Radiological investigations were performed as follows: a) Ultrasonography of the affected knee joint using linear probes (7-12 MHz Logiq P5). Measurements were taken from various knee locations, including the right lateral condyle (RLC), right intercondylar area (RIA), right medial condyle (RMC), left medial condyle

(LMC), left intercondylar area (LIA), and left lateral condyle (LLC). b) Subsequently, TRUFI MRI images of the same patients were analyzed by the same interpreters. Chondral lesions were classified according to the Outer bridge classification ⁽⁹⁾. c) Finally, the findings from ultrasonography and TRUFISP MRI images were compared.

Statistical analysis

The collected data was revised, coded, and tabulated using the Statistical Package for Social Science (IBM Corp. Released 2017. IBM SPSS Statistics for Windows, Version 25.0. Armonk, NY: IBM Corp.). Descriptive statistics were applied to the data, including the calculation of means and standard deviations for numerical data, as well as frequencies and percentages for non-numerical data. The normality of data distribution was assessed using the Shapiro-Wilk test. Analytical statistics were conducted to examine the relationships between variables. The Chi-Square test was used to analyze the relationship between two qualitative variables, while Kappa agreement was employed to assess the agreement between two qualitative variables in terms of true positives, false positives, true negatives, and false negatives. The receiver operating characteristic (ROC Curve)- was utilized to evaluate the sensitivity and specificity of quantitative diagnostic measures. The optimum cut-off point was determined by maximizing the area under the curve (AUC) value. An AUC value greater than 0.9 indicates high accuracy, 0.7-0.9 suggests moderate accuracy, 0.5-0.7 represents low accuracy, and 0.5 indicates a chance result. A two tailed P value < 0.05 was considered statistically significant.

Results

The current study carried on 52 subjects suffering from anterior knee pain. Their mean age was 34.85 years. Females represented 57.7% while males were

42.3%. Mean BMI of the studied subjects was 31.18 kg/m², Table 1.

According to knee pain side, 60% complained from left sided knee pain and 40% complained of right sided pain. Numerical Pain Rate Scale (NPRS) was calculated to assess the severity of knee pain and it was mild in 36.5% of the studied cases, moderate in 46.2% and severe in 17.3%. Mean NPRS scale was 4.54 for the studied cases, Table 2.

Table 1. Demographic data of the studied cases

Variable	Total cases	n=52
Age (years), M±SD	34.85±13.99	
Gender n (%)	Female	30(57.7%)
	Male	22(42.3%)
BMI kg/m ² , M±SD	31.18±4.86	

Table 2. Anterior knee pain assessment in studied cases.

Variable	Total cases	n=52
Side affected n (%)	Left	31(60%)
	Right	21(40%)
NPRS grading n (%)	Mild	19(36.5%)
	Moderate	24(46.2%)
	Severe	9(17.3%)
NPRS scale M±SD	4.54±2.36	

NPRS: Numerical Pain Rate Scale

Table 3. Knee ultrasound findings in the studied cases.

	Ultrasound findings	Total cases	n=52(percent)
Main findings, n (%)	Grade I (Blurred margin)	30	(57.7%)
	Grade II (Local thinning <50 %)	4	(7.7%)
	Grade III (Local thinning >50 %, no bony involvement)	10	(19.2%)
	Grade IV (Local thinning >50 %, with bony involvement)	8	(15.4%)
Associated findings, n (%)	Patellar dislocation	10	(19.2%)
	Patella alta	5	(9.6%)
	Synovial plica	9	(17.3%)
	Joint effusion	35	(67.3%)

According to MRI findings, 50% showed Grade II, 19.2% had Grade III, and both Grade I and Grade IV were distributed in 15.4% of studied subjects. Associated MRI findings showed that 21.2% of cases had patellar dislocation, 13.5% had patella alta, 21.2% had synovial plica and 69.2% had joint effusion, Table 4.

Ultrasonography results compared to MRI in each finding as true positive, false

positive, true negative and false negative to calculate positive predictive and negative predictive values for each finding of ultrasound result. Ultrasound results showed high positive prediction in all findings except in Grade II (15.38%). Ultrasound results showed high negative prediction in all findings except in Grade I (50%), Table 5.

According to knee ultrasound findings in the studied cases, the majority of cases (57.7%) showed Grade I, followed by Grade III (19.2%), Grade IV (15.4%) and Grade II (7.7%). According to associated findings in the studied cases, 19.2% of cases had patellar dislocation, 9.6% had patella alta, 17.3% had synovial plica and 67.3% had joint effusion, Table 3.

According to accuracy of ultrasonography in detecting the right MRI findings, all findings showed high sensitivity except Grade I (26.67%). All findings showed

100% specificity except in Grade II (54.17%). A high significant p value was detected using kappa agreement for all findings, Table 6.

Table 4. Knee MRI findings in the studied cases.

MRI findings		Total cases n=52(percent)
Main findings, n (%)	Grade I (Signal heterogeneity with smooth surface)	8(15.4%)
	Grade II (Fibrillation or erosion more than 50% of cartilage thickness)	26(50%)
	Grade III (Fibrillation or erosion more than 50% of cartilage thickness with or without small bone ulcerations)	10(19.2%)
	Grade IV (Full thickness cartilage lesions with underlying bony changes)	8(15.4%)
Associated findings, n (%)	Patellar dislocation	11(21.2%)
	Patella alta	7(13.5%)
	Synovial plica	11(21.2%)
	Joint effusion	36(69.2%)

Table 5. Validity of ultrasound in predicting accurate diagnosis compared to MRI results in studied cases.

		TP	FP	FN	TN	PPV%	NPV%
Main findings, n (%)	Grade I	8	0	22	22	100	50
	Grade II	4	22	0	26	15.38	100
	Grade III	10	0	0	42	100	100
	Grade IV	8	0	0	44	100	100
Associated findings, n (%)	Patellar dislocation	10	0	1	41	100	99.10
	Patella alta	5	0	2	45	100	98.82
	Synovial plica	9	0	2	41	100	98.44
	Joint effusion	35	0	1	16	98.77	98.08

TP: true positive, FP: false positive, FN: false negative, TN: true negative

Table 6. Agreement between ultrasonography and MRI findings in studied cases.

		Sensitivity	Specificity	Kappa	P-value
Main findings, n (%)	Grade I	26.67	100	0.235	0.008*
	Grade II	100	54.17	0.154	0.037*
	Grade III	100	100	1.000	<0.001*
	Grade IV	100	100	1.000	<0.001*
Associated findings, n (%)	Patellar dislocation	90.91	100	0.780	<0.001*
	Patella alta	71.43	100	0.898	<0.001*
	Synovial plica	81.82	100	0.658	0.002*
	Joint effusion	97.22	100	0.895	<0.001*

Cases

Case 1: Female patient 32y complaining of left anterior knee pain with limitation of flexion of 4m. No history of trauma, operations or chronic diseases.

By MRI TRUFI: focal cartilaginous hyperintensity is seen within trochlear notch.

By Ultrasonography: normal femoro-trochlear cartilage thickness with no evidence of cartilage lesions, Figure 1.

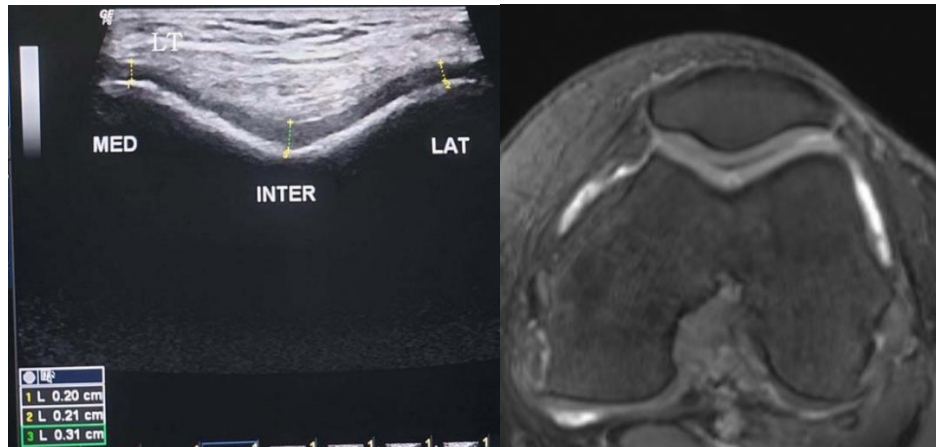


Figure 1: case 1

Case 2: Female patient 30y complaining of left anterior knee pain, limitation of flexion of 8m. No history of trauma, operations or chronic diseases. By MRI TRUFI: symmetrical reduction in trochlear cartilage thickness less than 50%

with no evidence of underlying bony changes (grade II).

By ultrasonography: symmetrical reduction in trochlear cartilage thickness less than 50% with no evidence of underlying bony changes (grade II), Figure 2.

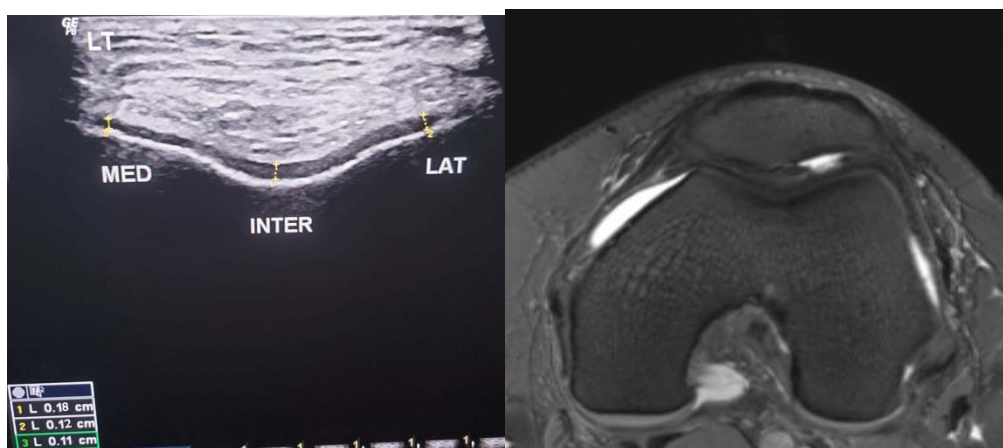


Figure 2: case 2

Case 3: Female patient 29y, complaining of left anterior knee pain with limitation of flexion of 5m. No history of operations, trauma or chronic diseases. By MRI TRUFI: complete loss of lateral aspect of trochlear cartilage with no

evidence of underlying bony changes (grade III).

By ultrasonography: complete loss of lateral aspect of trochlear cartilage with no evidence of underlying bony changes (grade III), Figure 3.

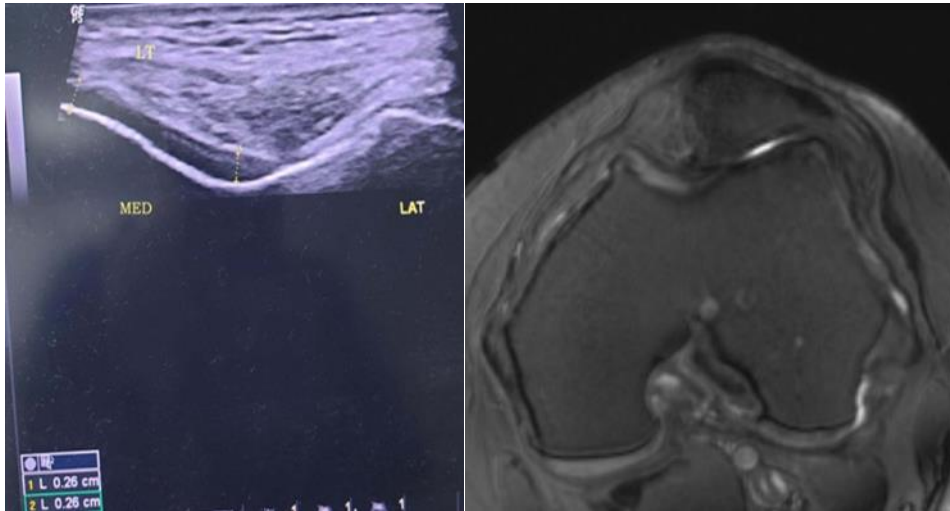


Figure3: case3

Discussion

Knee pain, a prevalent musculoskeletal issue affecting individuals of all ages, can significantly impede daily activities and quality of life ⁽¹⁰⁾. Among knee pain types, anterior knee pain stands out as common, stemming from factors like patella-femoral joint disorders, tendinopathies, and cartilage lesions. The femoro-trochlear cartilage, pivotal for smooth knee joint function and load distribution, can be disrupted by cartilage lesions, leading to pain and dysfunction ⁽¹¹⁾. Precise cartilage evaluation is thus vital in managing anterior knee pain. Ultrasonography and true fast imaging with steady state precession (TRUFI) MRI have been used to assess cartilage, yet, comparative studies in anterior knee pain patients remain limited ^(12, 13).

In the current study, knee pain distribution revealed that 60% of participants experienced left-sided knee pain, while 40% reported right-sided pain. The severity of knee pain, evaluated using the NPRS scale, showed 36.5% with mild pain, 46.2% with moderate pain, and 17.3% with severe pain, yielding a mean NPRS score of 4.54. These findings align with prior research; for instance, a study reported a similar distribution of knee pain sides in knee osteoarthritis patients ⁽¹⁴⁾, and

the observed pain severity is consistent with studies among knee osteoarthritis patients ⁽¹⁵⁾.

The study also explored knee ultrasound findings in individuals with anterior knee pain, revealing diverse cartilage abnormalities. Grade I changes were most prevalent (57.7%), resembling early cartilage softening or swelling. These observations are consistent with a study reported similar Grade I changes in anterior knee pain patients ⁽¹³⁾. Furthermore, Grade III (19.2%) and Grade IV (15.4%) cartilage alterations- were identified, mirroring the findings of another study regarding Grade III and IV changes in knee pain patients. Patellar dislocation was noted in 19.2% of cases, echoing another study findings of a link between patellar instability and anterior knee pain ⁽¹⁶⁾. Notably, patella alta (9.6%) and synovial plica (17.3%)- were also observed, consistent with some studies, respectively, in relation to altered patellofemoral mechanics and synovial plica irritation ^(14,17).

The study's MRI assessment revealed a spectrum of femoro-trochlear cartilage abnormalities in anterior knee pain patients, with Grade II changes (50%) indicating partial thickness fissures being

the most prevalent, akin to Everhart JS., 2021⁽¹⁸⁾. Grade III alterations (19.2%) were also identified, consistent with Everhart JS., 2021⁽¹⁸⁾. Intriguingly, Grade I and Grade IV abnormalities were distributed in 15.4% of subjects, suggesting a unique pattern deserving further exploration. Additionally, associated MRI findings such as patellar dislocation (21.2%) and patella alta (13.5%) aligned with prior researches^(19,20). Synovial plica presence (21.2%) underscored its significance in anterior knee pain, similar to Li W., 2019⁽²¹⁾.

Comparison of ultrasonography and MRI findings highlighted their diagnostic strengths. Ultrasonography exhibited high positive predictive values, corroborating its accuracy in identifying cartilage abnormalities and associated features. However, a lower positive predictive value was noted for Grade II changes (15.38%), as discussed by Vande Berg,⁽²²⁾. Ultrasonography's high negative predictive values, except for Grade I changes (50%), supported its role in ruling out significant abnormalities, consistent with Saarakkala⁽²³⁾. Notably, ultrasonography's relatively lower sensitivity for Grade I changes and challenges in detecting Grade II changes-warrant careful interpretation, aligning with Tamsel et al.'s concerns⁽²⁴⁾.

Conclusively, both ultrasonography and MRI effectively assessed femorotrochlear cartilage abnormalities, with ultrasonography excelling in confirming and excluding significant changes. Nevertheless, cautious interpretation is needed, particularly for Grade II and I changes. Prior studies have similarly highlighted ultrasonography's accuracy in detecting knee abnormalities⁽²⁵⁾.

Similarly, another study reported high sensitivity (89.5%) and specificity (96.6%) of ultrasonography in detecting medial collateral ligament injuries in comparison to MRI⁽²⁶⁾.

Moreover, studies have shown that ultrasound is a reliable imaging modality for detecting joint effusion, which is the

most common finding in the current study, with high sensitivity and specificity^(27, 28). Additionally, a study reported that ultrasonography had high sensitivity and specificity in detecting chondral lesions in the knee joint⁽²⁹⁾.

Overall, the findings of the current study suggest that ultrasonography can be a reliable alternative to MRI in assessing femoro-trochlear cartilage in anterior knee pain, especially in detecting joint effusion and chondral lesions. However, further studies with larger sample sizes are required to confirm these findings and determine the diagnostic accuracy of ultrasonography in comparison to MRI in assessing femoro-trochlear cartilage in anterior knee pain.

According to accuracy of ultrasonography in detecting the right MRI findings, all findings showed high sensitivity except Grade I (26.67%). All findings showed 100% specificity except in Grade II (54.17%). A high significant p value was detected using kappa agreement for all findings.

These findings are consistent with previous studies that have shown good accuracy of ultrasonography in detecting various knee pathologies such as joint effusion and tendinopathies. However, it is important to note that the accuracy of ultrasonography may vary depending on the experience and expertise of the operator^(13,30).

Conclusion

In conclusion, the study revealed that ultrasonography and MRI exhibit distinct strengths in detecting femoro-trochlear cartilage abnormalities. Ultrasonography demonstrated high positive predictive values in most findings, while MRI exhibited excellent specificity. Sensitivity varied between the two modalities for different cartilage grades. Both techniques demonstrated overall agreement in identifying cartilage structural changes, albeit with varying diagnostic performance in specific grades.

Sources of funding

This research did not receive any specific grant from funding agencies in the public, commercial, or not-for-profit sectors.

Author contribution

Authors contributed equally in the study.

Conflicts of interest

No conflicts of interest

References

- Nischal N, Iyengar KP, Herlekar D, Botchu R. Imaging of Cartilage and Chondral Defects: An Overview. *Life (Basel)*. 2023;13.
- Rodriguez-Merchan EC. The Current Role of Disease-modifying Osteoarthritis Drugs. *Arch Bone Jt Surg*. 2023;11:11-22.
- Bedewi MA, Elsifey AA, Naguib MF, Saleh AK, Al-Ghamdi S, Alhariqi BA, et al. Ultrasonographic measurement of femoral cartilage thickness in type II diabetic patients. *Medicine (Baltimore)*. 2020;99:e19455.
- Drevet S, Favier B, Lardy B, Gavazzi G, Brun E. New imaging tools for mouse models of osteoarthritis. *Geroscience*. 2022;44:639-50.
- Mars M, Tbini Z, Chelli M, Ladeb F. Comparison of 3D MR imaging sequences in knee articular cartilage at 1.5 T. *Biomedical Research (0970-938X)*. 2018;29.
- Han CH, Park HJ, Lee SY, Chung EC, Choi SH, Yun JS, et al. IDEAL 3D spoiled gradient echo of the articular cartilage of the knee on 3.0 T MRI: a comparison with conventional 3.0 T fast spin-echo T2 fat saturation image. *Acta Radiol*. 2015;56:1479-86.
- Walter SS, Fritz B, Kijowski R, Fritz J. 2D versus 3D MRI of osteoarthritis in clinical practice and research. *Skeletal Radiol*. 2023.
- Van Dyck P, Vanhevel F, Vanhoenacker FM, Wouters K, Grodzki DM, Gielen JL, et al. Morphological MR imaging of the articular cartilage of the knee at 3 T-comparison of standard and novel 3D sequences. *Insights Imaging*. 2015;6:285-93.
- Slattery, C. & Kweon, C. Y. 2018. Classifications in Brief: Outerbridge Classification of Chondral Lesions. *Clin Orthop Relat Res*, 476, 2101-2104.
- D'Ambrosi R, Meena A, Raj A, Ursino N, Hewett TE. Anterior Knee Pain: State of the Art. *Sports Med Open*. 2022;8:98.
- Howell M, Liao Q, Gee CW. Surgical Management of Osteochondral Defects of the Knee: An Educational Review. *Curr Rev Musculoskelet Med*. 2021;14:60-6.
- Majidi H, Niksolat F, Anbari K. Comparing the Accuracy of Radiography and Sonography in Detection of Knee Osteoarthritis: A Diagnostic Study. *Open Access Maced J Med Sci*. 2019;7:4015-8.
- Basha MAA, Eldib DB, Aly SA, Azmy TM, Mahmoud NEM, Ghandour TM, et al. Diagnostic accuracy of ultrasonography in the assessment of anterior knee pain. *Insights Imaging*. 2020;11:107.
- Wheatley MGA, Rainbow MJ, Clouthier AL. Patellofemoral Mechanics: a Review of Pathomechanics and Research Approaches. *Curr Rev Musculoskelet Med*. 2020;13:326-37.
- Pereira D, Peleteiro B, Araújo J, Branco J, Santos RA, Ramos E. The effect of osteoarthritis definition on prevalence and incidence estimates: a systematic review. *Osteoarthritis Cartilage*. 2011;19:1270-85.
- Culvenor AG, Øiestad BE, Hart HF, Stefanik JJ, Guermazi A, Crossley KM. Prevalence of knee osteoarthritis features on magnetic resonance imaging in asymptomatic uninjured adults: a systematic review and meta-analysis. *Br J Sports Med*. 2019;53:1268-78.
- Kanazawa H, Maruyama Y, Takamiya S, Kaneko K. Bilateral symptomatic lateral parapatellar synovial plica of the knee in an adolescent athlete: a case report. *Open Journal of Orthopedics*. 2017;7:63-71.
- Everhart JS, Boggs Z, DiBartola AC, Wright B, Flanigan DC. Knee Cartilage Defect Characteristics Vary among Symptomatic Recreational and Competitive Scholastic Athletes Eligible for Cartilage Restoration Surgery. *Cartilage*. 2021;12:146-54.
- Aysin IK, Askin A, Mete BD, Guvendi E, Aysin M, Kocyigit H. Investigation of the Relationship between Anterior Knee Pain and Chondromalacia Patellae and Patellofemoral Malalignment. *Eurasian J Med*. 2018;50:28-33.
- Kalichman L, Zhang Y, Niu J, Goggins J, Gale D, Zhu Y, et al. The association between patellar alignment on magnetic resonance imaging and radiographic manifestations of knee osteoarthritis. *Arthritis Res Ther*. 2007;9:R26.
- Li W, Liu Y, Zhu J, Bilig A, Liu F, Chen Z. Ultrasound remission can predict future good structural outcome in collagen-induced arthritis rats. *Sci Rep*. 2019;9:13294.
- Vande Berg BC, Lecouvet FE, Poilvache P, Jamart J, Materne R, Lengele B, et al. Assessment of knee cartilage in cadavers with dual-detector spiral CT arthrography and MR imaging. *Radiology*. 2002;222:430-6.
- Saarakkala S, Waris P, Waris V, Tarkiainen I, Karvanen E, Aarnio J, et al. Diagnostic performance of knee ultrasonography for detecting degenerative changes of articular cartilage. *Osteoarthritis Cartilage*. 2012;20:376-81.

24. Tamsel İ, Kavakli K, Özbek SS, Hekimsoy İ, Balkan C, Şahin F, et al. The value of ultrasonography in detecting early arthropathic changes and contribution to the clinical approach in patients of hemophilia. *J Clin Ultrasound*. 2022;50:428-32.
25. Park GY, Kim JM, Lee SM, Lee MY. The value of ultrasonography in the detection of meniscal tears diagnosed by magnetic resonance imaging. *Am J Phys Med Rehabil*. 2008;87:14-20.
26. Meyer P, Reiter A, Akoto R, Steadman J, Pagenstert G, Frosch KH, et al. Imaging of the medial collateral ligament of the knee: a systematic review. *Arch Orthop Trauma Surg*. 2022;142:3721-36.
27. Bloecker K, Wirth W, Guermazi A, Hunter DJ, Resch H, Hochreiter J, et al. Relationship Between Medial Meniscal Extrusion and Cartilage Loss in Specific Femorotibial Subregions: Data From the Osteoarthritis Initiative. *Arthritis Care Res (Hoboken)*. 2015;67:1545-52.
28. Roemer FW, Jarraya M, Collins JE, Kwok CK, Hayashi D, Hunter DJ, et al. Structural phenotypes of knee osteoarthritis: potential clinical and research relevance. *Skeletal Radiol*. 2022.
29. Aghaghazvini L, Tahmasebi MN, Gerami R, Vaziri AS, Rasuli B, Tahami M, et al. Sonography: a sensitive and specific method for detecting trochlear cartilage pathologies. *J Ultrasound*. 2020;23:259-63.
30. Brom M, Gandino IJ, Zacariaz Hereter JB, Scolnik M, Mollerach FB, Ferreyra Garrott LG, et al. Performance of Ultrasonography Compared to Conventional Radiography for the Diagnosis of Osteoarthritis in Patients With Knee Pain. *Front Med (Lausanne)*. 2020;7:319.

To cite this article: Hamada M. khater, Asmaa M. Azab, Sherif A. Abd Elsattar. Comparing Ultrasonography with True Fast Imaging with Steady State Precession MRI Images in Assessment of Femoro-Trochlear Cartilage in Anterior Knee Pain. *BMFJ XXX*, DOI: 10.21608/bmfj.2023.231471.1882.