

## Outcome of Spongioplasty as a Standalone Covering Layer After Urethroplasty in Distal Hypospadias

Ehab M. Oraby, Hazem M. Sobeih, Eslam W. Elbanayousi, Mohammed O. Elshaer

General surgery Department,  
Faculty of Medicine Benha  
University, Egypt.

Corresponding to:  
Dr. Eslam W. Elbanayousi.  
General surgery Department,  
Faculty of Medicine Benha  
University, Egypt.  
Email: eslamwafeek@gmail.com

Received:  
Accepted:

### Abstract:

**Background:** In hypospadias, the urethra opens proximally and ventrally, operative repairs aim to provide a better function as well as good cosmesis. Various tissues were used as a second layer after urethroplasty to improve outcomes. The aim of the current study was to demonstrate the efficacy of the corpus spongiosum and its capability to be the one and only 2nd layer after urethroplasty. **Patients and methods:** A total number of 30 distal cases were included with an age ranging from 6 – 120 months most of them was coronal/ sub coronal, non-circumcised, with developed proximal urethra and spongiosum and absent ventral curvature. Urethroplasty technique was either tubularized incised plate (TIP) or Thiersch-Duplay and the second layer was always the mobilized then approximated spongiosal pillars. The mean operative time was 87.80 ( $\pm$  8.56) min and patients were discharged at the same day of surgery with a three month follow up period and monitoring of signs of any post-operative complications. **Results:** Results at one month showed overall complication rate of 16.7% including spraying of urinary stream, meatal stenosis, Urethro-cutaneous fistula (1 mm in size at the coronal sulcus), skin sloughing and slipped urinary catheter in one case (3.3%) for each of them. No glans dehiscence, urethral diverticulum, residual chordee, symptoms of lower urinary tract infection or major aesthetic issues were encountered. **Conclusion:** Spongioplasty alone can be used as a second layer if a well-developed, strong spongiosum is available. **Keywords:** Hypospadias; Tubularized incised plate; Spongioplasty.

### Introduction

Hypospadias is a congenital anomaly of the penis. The urethral meatus is located along the ventral surface of the penis between the glans and the perineum in hypospadias, a condition in which the distal urethra does not develop correctly<sup>(1)</sup>.

In 1968, hypospadias was divided into anterior, middle, and posterior

categories based on the placement of the meatus following curvature release. The meatus is frequently located close to the penile tip ("distal" position)<sup>(2)</sup>. The usage of various hypospadias correction techniques varies depending on the kind of hypospadias and the surgeon's expertise<sup>(3-4)</sup>.

Diverse tissues, including the Dartos, de-epithelialized penile skin flap, tunica vaginalis, and corpus spongiosum, have been employed as a protective intermediate layer between the neourethra and the skin to prevent urinary fistula. The separation of two branches of the bifurcated urethral spongiosum, which were later reunited and utilized to cover the ventral side of the neourethra, was initially described in 2000. This technique was known as "spongioplasty" <sup>(5)</sup>.

In 2009, no statistically significant change in the re-operation rate was observed after adding spongioplasty to the dartos fascia cover in a single center experience with 500 cases defining variables impacting the success of tubularized incised plate (TIP) urethroplasty <sup>(6)</sup>.

Many currently used hypospadias repairs can readily involve the use of spongy tissue as an intermediary layer in urethral covering. It helped explain why there were so few urethrocutaneous fistulas. Additionally, it reduces stress on the healing process and has a minimal risk of complications from penile torsion, chordee development, and dorsal skin loss. Also, it takes less time than the dartos flap covering <sup>(7)</sup>.

Because it lessened the degree of penile curvature and allowed dorsal plication to be avoided in more than half of the hypospadias patients who displayed moderately severe curvature, spongioplasty could be used as an additional procedure after dartos flap coverage of the neourethra following TIP urethroplasty <sup>(9)</sup>.

It offers strong support to the hypoplastic distal urethra and neourethra, which may make catheterization easier in the immediate and early postoperative periods <sup>(10)</sup>.

When distal hypospadias is repaired in children, failure to identify and/or treat the inadequate corpus spongiosum may result in symptoms in adolescents <sup>(11)</sup>.

### **Aim of the work**

The aim of the work was to demonstrate the outcome of spongioplasty as a standalone covering layer after urethroplasty in distal hypospadias regarding operative time and complication rate.

---

### **Patients and methods**

The current study is a prospective study that included 30 children who presented to the outpatient clinic, General surgery department, Benha university hospital – Egypt – with distal penile hypospadias throughout the period between March 2022 and February 2023 after an approval from the research ethics committee in Benha faculty of medicine {M.S.5.1.2022}. Written informed consent with detailed description of the repair technique and expected complications were explained and signed by the parents or guardians.

Inclusion criteria: Glanular (from the subcorona out) or distal penile anomaly; Primary cases only. Exclusion criteria: Age less than six months; Recurrent cases; Uncontrolled chronic ill patients.

Urethroplasty was done by TIP and Thiersch-duplay and the second layer in all cases was the corpus spongiosum (spongioplasty) as a second layer between the neourethra and the skin.

All patients were submitted to full history, complete examination and routine investigations, counselling of the parents.

A fasting regimen was instructed by the anesthetist and single dose IV prophylactic antibiotic was given.

The procedure was done similar to that which was done by <sup>(12)</sup> General anesthesia followed by caudal anesthesia, optical magnification, using fine instruments and bipolar cautery all by staff surgeons under similar circumstances. Sterilization from the umbilicus to the knee joint and draping. Traction suture to the glans penis, Urethral sounding followed by introduction of a urinary catheter of appropriate size into the bladder.

A circumferential skin incision, Penile degloving, gittes test was used to verify chordee correction<sup>(13)</sup>. Hemostasis was achieved using either a tourniquet bound to the penile root or a 1:150000 epinephrine injection or a combination of both and by using bipolar cautery all along.

Two paramedian incisions between glans and urethral plate. Dissection of the glanular wings from the underlying corpora cavernosa. The decision of whether to incise the plate or not was made at this step depending on its capacity and depth. If incision was contemplated, it was done -using scissors- from the hypospadias opening to the end of the urethral plate distally down to the tunica albuginea.

Tubularization was done over the catheter with continuous subcuticular suture inverting all epithelium into the inside of the neourethra.

The spongiosum was located and dissected on both sides from lateral to medial until it could be approximated without tension. We carefully mobilized the glans wings distally while the spongiosal pillars extended beneath them on each side. A second layer of spongioplasty was performed over the neourethra.

Single layered glanuloplasty, Circumcision, skin closure and urinary catheter fixation to the glans were done. Then, application of an ophthalmic ointment, gentle pressure gauze then adhesive plaster wrapped around the penis as a dressing. Starting oral feeding was permitted from 1-2 hours post operatively, oral antibiotic, analgesic and antiedematous were prescribed for one week.

First dressing was removed after about 3 days and the urinary catheter was removed after about a week. Patients were discharged at the day of surgery and follow up visits were planned to be after three days, one week, one month and three

months post operatively giving special attention to post-operative complications and final functional and aesthetic outcome.

### **Statistical analysis**

Data management and statistical analysis were done using SPSS version 28 (IBM, Armonk, New York, United States). Quantitative data were assessed for normality using the Shapiro-Wilk test and direct data visualization methods. According to normality, quantitative data were summarized as means and standard deviations or medians and ranges. Categorical data were summarized as numbers and percentages. Operative time was compared according to the technique type using the independent t-test. The rate of complication was compared using Fisher's exact test. All statistical tests were two-sided. P values less than 0.05 were considered significant.

---

### **Results**

This prospective study was conducted in the General Surgery Department, Faculty of Medicine, Benha University Hospital and General Surgery Department, Benha health insurance hospital- on 30 patients with a clinical diagnosis of distal hypospadias.

#### **❖ General characteristics**

The median age of the studied patients was 11 months, ranging from 6 – 120 months. Only 10% of cases were circumcised (Table 1).

#### **❖ Meatal position**

The most frequent meatal position was coronal (50%), followed by sub-coronal (23.3%), distal shaft (13.3%), and glanular (13.3%) (Table 2).

#### **❖ Ventral curvature**

Most patients had absent curvature (86.7%). Only 10% and 3.3% had curvatures of 0-10 degrees and 40-45 degrees, respectively (Table 3).

**Table 1:** General characteristics of the studied patients.

| General characteristics |                |              |
|-------------------------|----------------|--------------|
| Age (months)            | Median (range) | 11 (6 - 120) |
| Circumcised cases       | n (%)          | 3 (10)       |

**Table 2:** Meatal position of the studied patients

| Meatal position | n (%)    |
|-----------------|----------|
| Coronal         | 15 (50)  |
| Sub-coronal     | 7 (23.3) |
| Distal shaft    | 4 (13.3) |
| Glanular        | 4 (13.3) |

**Table 3:** Ventral curvature of the studied patients

| Ventral curvature | n (%)     |
|-------------------|-----------|
| 0 - 10 degrees    | 3 (10)    |
| 40 - 45 degrees   | 1 (3.3)   |
| Absent curvature  | 26 (86.7) |

❖ Proximal urethra and spongiosum  
Most patients had a developed proximal urethra and spongiosum. Only two patients had a hypoplastic proximal urethra and spongiosum (Table 4).

❖ Procedure characteristics  
About three-quarters of the patients (73.3%) underwent the Thiersh duplay technique, and approximately one-quarter (26.7%) underwent TIP. The mean procedure time was 88 ±9 minutes (Table 5).

❖ Complications  
Complications were reported in 16.7% of the studied patients. The complications

were catheter slippage, meatal stenosis, skin sloughing, sprayed stream, and urethrocutaneous fistula (one patient in each complication) Complications according to different techniques

Patients who underwent the TIP technique reported significantly higher complications (50%) than those who underwent the Thiersh duplay (4.5%) ( $P = 0.011$ ).

❖ Operative time according to different techniques.

No significant difference was reported between the Thiersh duplay and TIP techniques regarding procedure time ( $P = 0.406$ ) (Table 6).

**Table 4:** Proximal urethra and spongiosum of the studied patients

| Proximal urethra and spongiosum | n (%)     |
|---------------------------------|-----------|
| Developed                       | 28 (93.3) |
| Hypoplastic                     | 2 (6.7)   |

**Table 5:** Procedure characteristics of the studied patients.

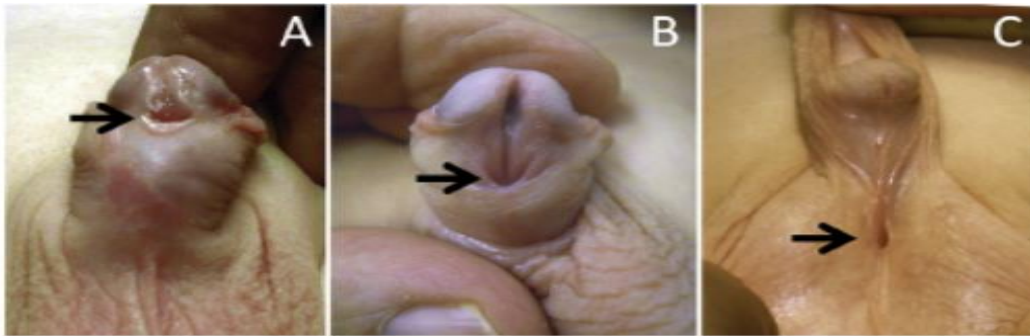
| Procedure characteristics |          |           |
|---------------------------|----------|-----------|
| Technique                 |          |           |
| Thiersh duplay            | n (%)    | 22 (73.3) |
| TIP                       | n (%)    | 8 (26.7)  |
| Operation time (minutes)  | Mean ±SD | 88 ±9     |

TIP: Tubularized Incised Plate

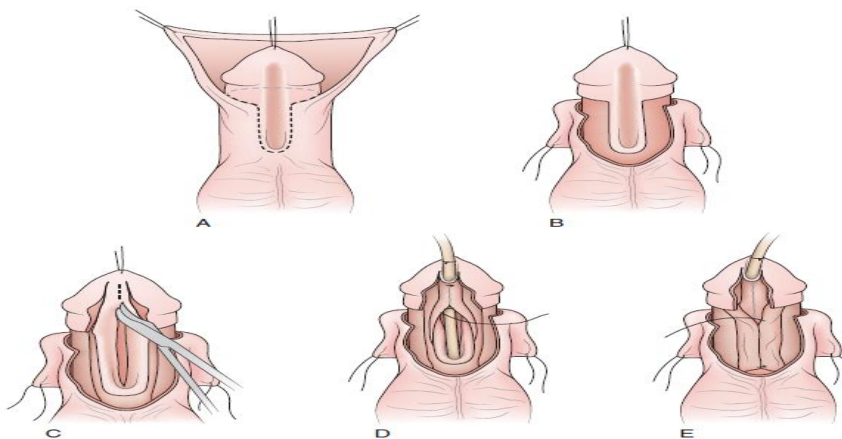
**Table 6:** Procedure time according to different techniques

| Operation time (minutes) | Mean ±SD | Urethroplasty technique |             |         |
|--------------------------|----------|-------------------------|-------------|---------|
|                          |          | Thiersh duplay (n = 22) | TIP (n = 8) | P-value |
|                          |          | 87 ±8                   | 90 ±10      | 0.406   |

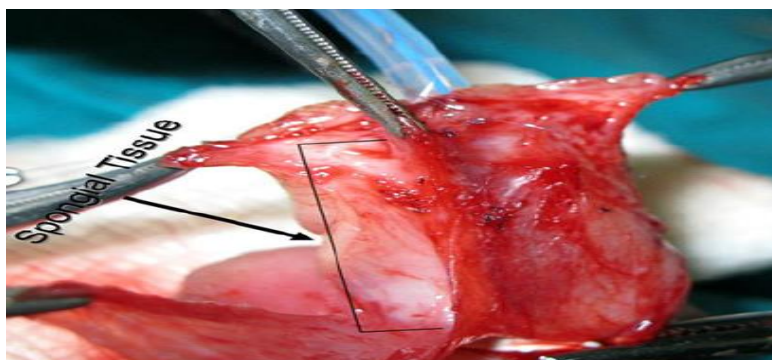
TIP: Tubularized Incised Plate



**Figure 1:** The arrows show the placements of the urethral meatus in the distal (A), midshaft (B), and proximal (C) regions in three examples of males with hypospadias (3).

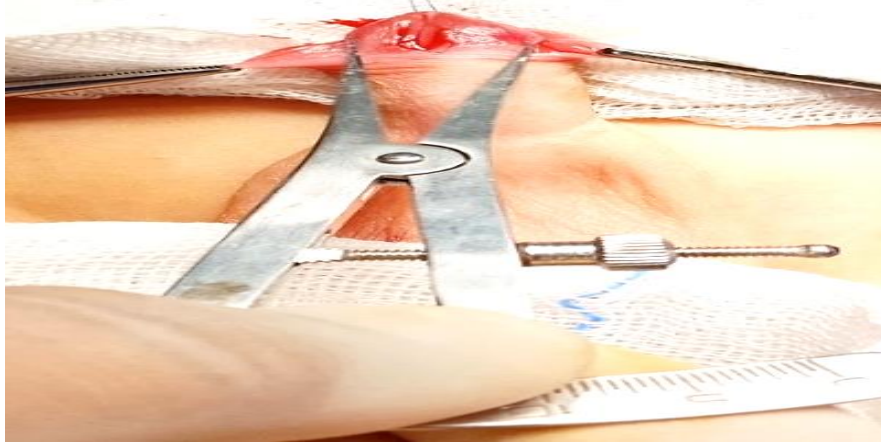


**Figure 2:** TIP with spongioplasty (8).

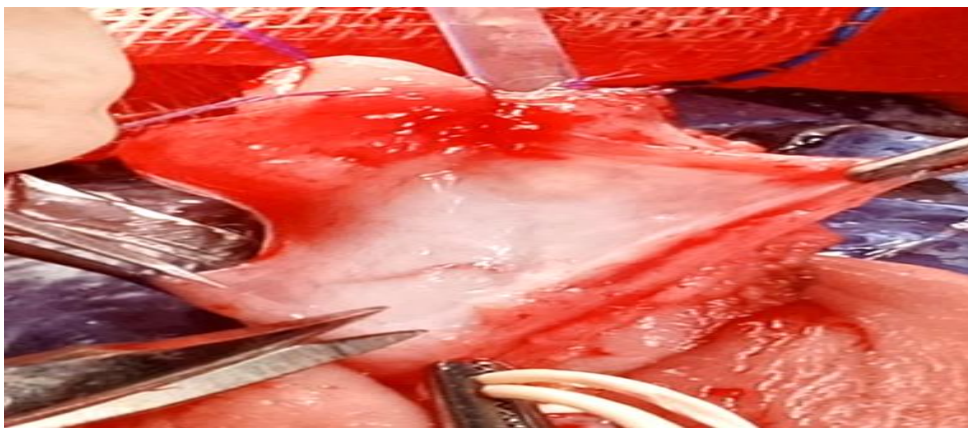

**Figure 3:** Appearance of the paraurethral spongy tissue (1).

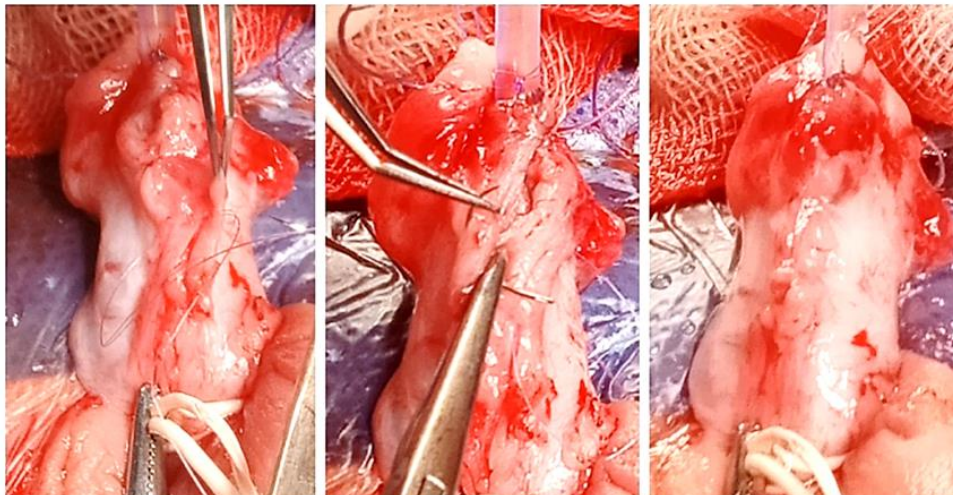




**Figure 4:** Remeasurement of glans width and urethral plate width.



**Figure 5:** Mobilization of spongiosal pillars.



**Figure 6:** Spongioplasty.

## Discussion

Hypospadias is an abnormally positioned external urethral meatus in male infants sometimes linked to a ventral bending of the penis or dorsal hood, which may affect the function of the urethra and the genital organs<sup>(12)</sup>. TIP urethroplasty is a flexible repair that may be used to treat a variety of abnormalities<sup>(14)</sup>. The modified Duplay procedure involves a number of modifications that enable the correction of the associated anomalies common in hypospadias including the incision of the meatus, which is typically required, a prolonged dissection of the penile skin upward from the orifice to remove cutaneous urethral adherence, which is primarily the cause of the penile angulation, and spongioplasty<sup>(4)</sup>.

Various reports have indicated fistula rates ranging from 0 to 28% after TIP repair<sup>(6)</sup>. In 2014, some authors concluded that a worse spongiosum was associated with more problems in their prospective research. About one third of the poor spongiosum cases had proximal hypospadias, indicating that the more proximal the hypospadias, the less developed is the spongiosum<sup>(17)</sup>. Aiming to achieve the best results, this study included only distal hypospadias cases unlike other studies in which about half of the study sample was of distal type and the other half was mid penile<sup>(7)</sup> or included all types of hypospadiac meatal locations<sup>(6)</sup>. This study included primary cases only<sup>(4,19)</sup>, but unlike the single-center experience with 500 cases published in 2009 in which about one eighth of the cases had at least one unsuccessful prior surgery<sup>(6)</sup>.

We Included distal cases only assuming that the spongiosum would mostly be well developed but a recent publication applied a stricter criterion of well-developed robust spongiosum and other suitable glanular, meatal and shaft specifications and used the TIP technique with spongioplasty alone as the second layer<sup>(19)</sup>.

Most of the related studies tended to limit the urethroplasty technique to just one or merely two techniques. In this study about one quarter of the cases received TIP urethroplasty and the rest received Thiersch-Duplay urethroplasty. Many authors used only the TIP technique to create the neourethra<sup>(1,9,12and 15)</sup> unlike others who employed different urethroplasty techniques (advancement, tubularization, Flip flap and island onlay pedicle graft)<sup>(16)</sup>.

A protective barrier between the neourethra and the skin is one of the key elements in minimizing the development of fistulas<sup>(15)</sup>. In this study we decided to follow the footsteps of some of the recent reports using the mobilized approximated spongiosum as a standalone covering layer after urethroplasty<sup>(17,19)</sup> but other publications choose to assess the supporting effect of spongioplasty in conjunction with the standard TIP urethroplasty repair, including dorsal preputial dartos flap<sup>(7,10)</sup>. Many attempts were done trying to select the best second layer cover for repairing different forms of hypospadias that some of them investigated the extra added effect of reconstructing forked corpus spongiosum compared to the standard standalone dartos flap as a second layer<sup>(1,9and18)</sup> and others divided the study sample into two halves and compared between the dartos flap and the spongioplasty as the second layer<sup>(12)</sup>. Some authors utilized spongioplasty, dartos flap, and both<sup>(6)</sup> and others compared between tunica vaginalis flap, dartos flap and spongioplasty as the one and only second layer<sup>(15)</sup>.

We aimed to lessen the operative time and gain the highest success rate at the same time. The mean operative time of this study was  $88 \pm 9$  min which was comparable to related studies with operative time ranging from 85.9 min<sup>(7)</sup> to 93.84 min<sup>(18)</sup>. This study's success rate was 83.3% similar to most of the recent related literature<sup>(6,9,18)</sup> but it seems that meticulous selection of urethroplasty

technique according to urethral plate width (TIP if width  $\geq$  6 mm and on lay island flap if width less than 6 mm) and the use of a double layer cover between the neo urethra and the skin can combined raise the success rate up to 93.2%<sup>(18)</sup>.

This study's fistula rate was 3.3% which was comparable to fistula rates associated with spongioplasty as a standalone covering layer reported in the recent English literature that we reviewed ranging from 0%<sup>(19)</sup> to 3.9%<sup>(4)</sup> and less than the reported 7.5% fistula rate of the standard dartos flap<sup>(1,14,18)</sup>. The added effect of spongioplasty in conjunction with dartos flap cover resulted in decreased fistula rates even to 0%<sup>(1,10,18)</sup>. We noticed that this one fistula case had got a hypoplastic spongiosum favoring the conclusion that a worse spongiosum is associated with more post-operative problems<sup>(16)</sup>.

About three quarters of our chordee cases (which was mild ranging from zero to ten degrees) were successfully managed by only penile degloving<sup>(6)</sup>, but one quarter needed adjunct dorsal plication<sup>(9)</sup>.

Post-operative meatal issues (stenosis/sprayed urinary stream) were encountered in 6.6% of patients in this study which was comparable to related reports (4% meatal retraction<sup>(16)</sup>, 1.4% meatal stenosis<sup>(18)</sup>, 5.8% meatal stenosis<sup>(15)</sup> and 4.7% meatal stenosis<sup>(19)</sup>). In this study we fortunately succeeded to treat all meatal abnormalities using only regular calibration<sup>(12)</sup> but this treatment modality alone wasn't sufficient in managing some of other authors' meatal issues cases correcting them only using meatoplasty<sup>(15)</sup>.

The study's limitations include its relatively short follow-up period of three months (a minimum of 6 months), which prevented it from determining possible late post-operative consequences, and the possibility that patients who were seen earlier in the study had different follow-up than children who were monitored more recently.

---

## Conclusion

Spongioplasty is an available, easily obtained covering layer that can be applied after various types of urethroplasty techniques with no more complications than other procedures that can be used in primary hypospadias surgery for distal variants. This method offers a highly vascularized barrier layer for urethroplasty with no devitalized skin flap problem, which is favorable in the short as well as the long run. It also has a quick procedure and requires less complexity. We advise using spongioplasty alone as the second layer if a well-developed, strong spongiosum is available in carefully chosen individuals with primary hypospadias in order to prevent problems.

## Conflict of interest

No conflict of interest.

## Funding

The authors declare that no funds, grants, or other support were received during the preparation of this manuscript.

---

## References

- 1) Bilici, S., Sekmenli, T., Gunes, M., Gecit, I., Bakan, V, and Isik, D. Comparison of dartos flap and dartos flap plus spongioplasty to prevent the formation of fistulae in the snodgrass technique. *International Urology and Nephrology* 2011, 43(4), 943–948.
- 2) Hadidi, A. T., and Azmy, A. F. *Hypospadias Surgery* (A. T. Hadidi & A. F. Azmy, Eds 2004, Springer Berlin Heidelberg.
- 3) Marrocco, G., Grammatico, P., Vallasciani, S., Gulia, C., Zangari, A., Marrocco, F., et al. Environmental, parental and gestational factors that influence the occurrence of hypospadias in male patients. *Journal of Pediatric Urology* 2015, 11(1), 12–19.
- 4) Dodat, H., Landry, J. L., Szwarc, C., Culem, S., Murat, F. J. and Dubois, R. Spongioplasty and separation of the corpora cavernosa for hypospadias repair. *BJU International* 2003, 91(6), 528–531.
- 5) Xie, L., Xi, Y., Zhang, X., Ding, H. and Li, S. Effects of spongioplasty on neourethral function following hypospadias repair: An experimental study in rabbits. *International Braz J Urol* 2020, 46(3), 436–443.
- 6) Sarhan, O. M., El-Hefnawy, A. S., Hafez, A. T., Elsherbiny, M. T., Dawaba, M. E. and Ghali, A. M. Factors affecting outcome of



- tubularized incised plate (TIP) urethroplasty: Single-center experience with 500 cases. *Journal of Pediatric Urology* 2009, 5(5), 378–382.
- 7) Gamal, W. M., Zaki, M., Rashid, A., Mostafa, M. and Abouzeid, A. E. M. Tubularized incised plate (TIP) repair augmented by spongioplasty for distal and midpenile hypospadias. *UroToday International Journal* 2009, 2(3).
  - 8) Long, C. J., Zaontz, M. R. and Canning, D. A. Hypospadias. In D. R. K. L. P. C. and W. A. Partin AW (Ed.), *Campbell Walsh Wein Urology*, 12th ed. Elsevier. 2021, 905–948.
  - 9) Hayashi, Y., Mizuno, K., Moritoki, Y., Nakane, A., Kato, T., Kurokawa, S. et al. Can spongioplasty prevent fistula formation and correct penile curvature in TIP urethroplasty for hypospadias? *Urology* 2013, 81(6), 1330–1335.
  - 10) Almodhen, F., Alzahrani, A., Jednak, R., Capolicchio, J. P. and el Sherbiny, M. T. Nonstented tubularized incised plate urethroplasty with Y-to-I spongioplasty in non-toilet trained children. *Canadian Urological Association Journal*. 2013, 2(2), 110.
  - 11) Ali, D. and Hanna, M. K. Symptomatic corpus spongiosum defect in adolescents and young adults who underwent distal hypospadias repair during childhood. *Journal of Pediatric Urology* 2021, 17(6), 814.e1-814.e5.
  - 12) Verma, A., Murtaza, S., Kundal, V. K., Sen, A. and Gali, D. Comparison of Dartos flap and spongioplasty in Snodgrass urethroplasty in distal penile hypospadias. *World Journal of Pediatric Surgery*. 2021, 4(3).
  - 13) Gittes, R. F., and McLaughlin, A. P. Injection technique to induce penile erection. *Urology* 1974, 4(4), 473–474.
  - 14) Snodgrass, W. T. Tubularized incised plate hypospadias repair: indications, technique, and complications. *Urology* 1999, 54(1), 6–11.
  - 15) Sengol, J., Gite, V. A., Agrawal, M., Sankapal, P. and Shaw, V. Choosing an ideal second layer cover in snodgrass repair for various types of hypospadias. *Turkish Journal of Urology* 2021, 47(3), 229–236.
  - 16) Yerkes, E. B., Adams, M. C., Miller, D. A., POPE, J. C., Rink, R. C. and Brock, J. W. Y-to-I wrap use of the distal spongiosum for hypospadias repair. *The Journal of Urology* 2000, 163(5), 1536–1539.
  - 17) Bhat, A., Sabharwal, K., Bhat, M., Saran, R., Kumar, V. and Singla, M. Outcome of tubularized incised plate urethroplasty with spongioplasty alone as additional tissue cover: A prospective study. *Indian Journal of Urology* 2014, 30(4), 392.
  - 18) Zhang, B., Bi, Y. L. and Ruan, S. S. Application and efficacy of reconstructing forked corpus spongiosum in distal/midshaft hypospadias repair. *Asian Journal of Andrology* 2021, 23(1), 47–51.
  - 19) Maheshwari, M., Gite, V. A., Agrawal, M., Sankapal, P., Shaw, V., Sharma, S. et al. Outcome of spongioplasty alone as second layer of tubularised incised plate urethroplasty in patients with hypospadias. *African Journal of Urology*. 2022, 28(1).

**To cite this article:** Ehab M. Oraby, Hazem M. Sobeih, Eslam W. Elbanayousi, Mohammed O. Elshaer. Outcome of Spongioplasty as a Standalone Covering Layer After Urethroplasty in Distal Hypospadias. *BMFJ* XXX, DOI: 10.21608/bmfj.2023.208387.1812.