

Role of 3D-Ultrasound in Patients with Abnormal Uterine Bleeding for Detection of IUCD Malposition

Mohsen A. Nosseir, Amr A. Sharaf Eldeen, Mohamed T. Soliman, Amira E. Ahmed

Department of Obstetrics and Gynecology, Faculty of Medicine Benha University, Egypt.

Corresponding to: Mohamed T. Soliman, Department of Obstetrics and Gynecology, Faculty of Medicine Benha University, Egypt.

Email:

draco.mohamed@gmail.com

Received: 29 March 2023

Accepted: 30 June 2023

Abstract

Background: The intrauterine contraceptive device (IUD) has been one of the most commonly used forms of contraception throughout the world over the last 50 years. **This study aimed to** determine the incidence of mal-positioned IUCD (located abnormally in the myometrium or in the cervix) in patients presenting with abnormal uterine bleeding by using 3D ultrasound in comparison with 2D ultrasound. **Methods:** This observational cross-sectional study was conducted on 100 patients who underwent gynecological 2D ultrasound. They had a 3D volume acquisition of the uterus in addition to the standard 2D ultrasound evaluation in cases with abnormal uterine bleeding. The coronal view of the uterus was then reconstructed to evaluate endometrial polyps and the position of fibroids, and to determine the configuration of the uterus. **Results** The mean age was 31.3 ± 2.85 . The mean BMI was 27.4 ± 2.40 . 85% of cases were displacement, 4.7% penetration, 9.4% malposition. There were 45.0% with Pelvic pain, 85.0 % with Abnormal Bleeding. There were 21.0% with Localization of IUD, 1.0% Suspected fibroid, 1.0% Suspected ovarian cyst. There were 79.0% by 2D mode, 96% by 3D mode. Regarding 3D and 2D mode in detection of malposition of the IUD. There were 95.0% by 3D mode, 77% 2D mode. As regard 3D mode in detection of malposition of the IUD, Sensitivity was 95.0%, Specificity was 90.0%, PPV was 90.47%, NPV was 94.7%. **Conclusion:** 3D ultrasound assessment followed has proven a higher accuracy when compared to the 2D technique in the visualization of IUDs and the diagnosis of mal-positioned IUDs.

Keywords: 3D-Ultrasound; Abnormal Uterine Bleeding; IUCD; Malposition.

Introduction

The intrauterine contraceptive device (IUD) has been one of the most commonly used forms of contraception throughout the world over the last 50 years (1). While its use has waxed and waned in the United States owing

to associated complications and lawsuits, the IUD has become more popular lately, with the introduction of copper-containing and hormone-containing devices that have progesterone or synthetic progestogen (2).

IUDs are often seen incidentally during pelvic ultrasound examination, and it is important to be able to determine their position within the uterus accurately. Typically, a standard two-dimensional (2D) ultrasound examination demonstrates the shaft of the IUD with reasonable precision, but is often unable to show the location of the IUD side arms that are found on most IUDs currently in use (3).

Three-dimensional (3D) ultrasound can be used to acquire a volume containing the entire uterine anatomy, from which the coronal plane of the endometrial cavity can be reconstructed (4). The coronal view of the uterus is particularly well-suited to demonstrate the relationship of the entire IUD, including the shaft and both arms, to the endometrial cavity (3). Such a coronal reconstructed view can demonstrate the exact position of the IUD, and specifically whether the side arms of the device are located abnormally, embedded within the myometrium (5).

The purpose of this study was to determine the incidence of mal-positioned IUCD (located abnormally in the myometrium or in the cervix) in patients presenting with abnormal uterine bleeding by using 3D ultrasound in comparison with 2D ultrasound.

Patients and methods

This observational cross-sectional study was conducted on 100 patients who underwent gynecological 2D ultrasound. They had a 3D volume acquisition of the uterus in addition to the standard 2D ultrasound evaluation in

cases with abnormal uterine bleeding. The coronal view of the uterus was then reconstructed to evaluate endometrial polyps and the position of fibroids, and to determine the configuration of the uterus. The study was done at Benha University Hospitals over a period of one year from July 2021 to July 2022. The study was approved by the research ethics committee, Faculty of Medicine, Benha University.

All patients who had an IUCD were demonstrated on 2D ultrasound by visualization of the shaft of the IUD underwent a 3D volume sweep of the uterus, with reconstruction of the coronal view of the uterine cavity, to demonstrate the position of the entire IUD.

The method of coronal view reconstruction was based on the Z-plane technique of (6).

This technique was a quick and easy way to manipulate 3D volumes so that a coronal view of the uterine cavity and its contents could be displayed in under a minute. With the A-plane (sagittal view) representing the acquisition plane and the B-plane (transverse view) being perpendicular to the acquisition plane, the C-plane represented the coronal plane, and by minor adjustments of this plane the IUD could be best visualized throughout its full extent (7).

The IUD was also rendered by placing the 3D IUD, and then manipulating the y-axis of the volume such that the arms of the IUD appeared on either side. This volume manipulation was done directly on the ultrasound machine at the time of the scan, and the examining physician determined

whether the IUD was in a normal location or located abnormally in the myometrium (3).

The IUD was considered abnormally located if any part of it was seen to extend past the confines of the endometrial cavity, poking into the substance of the uterus or cervix. This was a subjective determination as no specific measurement of the abnormally located portion was made. If there was any question as to whether the IUD was slightly embedded or not, then the patient was not included in the abnormally located group but included in the normal group. Only those IUDs that was embedded unequivocally on the 3D reconstructed views were considered mispositioned (7). The indications for sonography were recorded at the time of presentation for the examination. For those patients with an abnormally located IUD.

Sample size calculation

The sample size was calculated using Epi info software, version 7.2.2.16, based on a previous study done by Benacerraf et al. (5). The study reported abnormally located intrauterine contraceptive devices detected by three-dimensional ultrasound of 16.8%. The total sample size calculated was 100 patients. The confidence level and margin of error were adjusted at 95% and 8%, respectively.

Statistical analysis

Statistical analysis was done by SPSS v28 (IBM Inc., Armonk, NY, USA). Quantitative variables were presented as mean and standard deviation (SD) and compared between the two groups utilizing unpaired Student's t- test. Qualitative

variables were presented as frequency and percentage (%).

Research ethics committee: Ms.18.10.2021

Results

Regarding demographic characteristics among the studied cases. The mean age was 31.3 ± 2.85 . The mean Body mass index was 27.4 ± 2.40 . The mean Parity was 2.3 ± 0.42 . 85% of cases were displacement, 4.7% penetration, 9.4% malposition. **Table 1**

There were 45.0% with Pelvic pain, 85.0 % with Abnormal Bleeding. There were 21.0% with Localization of IUD, 1.0% Suspected fibroid, 1.0% Suspected ovarian cyst. **Table 2**

Regarding the length of time between intrauterine contraceptive device (IUD) insertion and sonographic evaluation in patients with an abnormally located device. The mean Length of time was 13.5 ± 1.2 . **Figure 1**

Regarding satisfying visualization of the uterine cavity and the IUD. There were 79.0% by 2D mode, 96% by 3D mode. **Figure 2**

Regarding 3D and 2D mode in detection of malposition of the IUD. There were 95.0% by 3D mode, 77% 2D mode. **Figure 3**

As regard 3D mode in detection of malposition of the IUD, Sensitivity was 95.0%, Specificity was 90.0%, PPV was 90.47%, NPV was 94.7%. **Table 3 and Figure 4**

Table 1: Demographic characteristics among the studied cases and Abnormal position (85 out of 100 cases)

Parameter	Mean ± SD N (%)
Body mass index (kg/m ²)	27.4± 2.40
Age (years)	31.3± 2.85
Parity (mean ± SD)	2.3± 0.42
Descriptive term	
Displacement N (%)	73 (85%)
Penetration N (%)	4 (4.7%)
Malposition N (%)	8 (9.4%)

Data were presented as mean ± SD (standard deviation), number (percentage).

Table 2: Principal indications for sonography in patients with an abnormally located intrauterine contraceptive device (IUD)

	N	%
Pelvic pain	45	45%
Abnormal Bleeding	85	85%
Localization of IUD	21	21%
Suspected fibroid	1	1%
Suspected ovarian cyst	1	1%

Table 3: Diagnostic performance of 3D mode in detection of malposition of the IUD

	Sensitivity	Specificity	PPV	NPV
3D mode	95.0	90.0	90.47	94.7

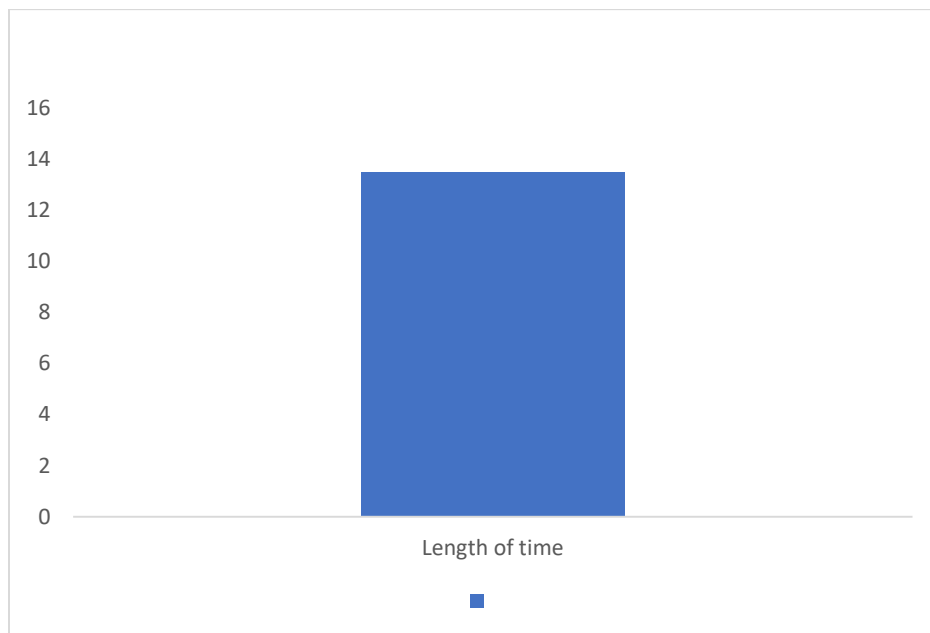


Figure 1: Length of time between intrauterine contraceptive device (IUD) insertion and sonographic evaluation in 28 patients with an abnormally located device.

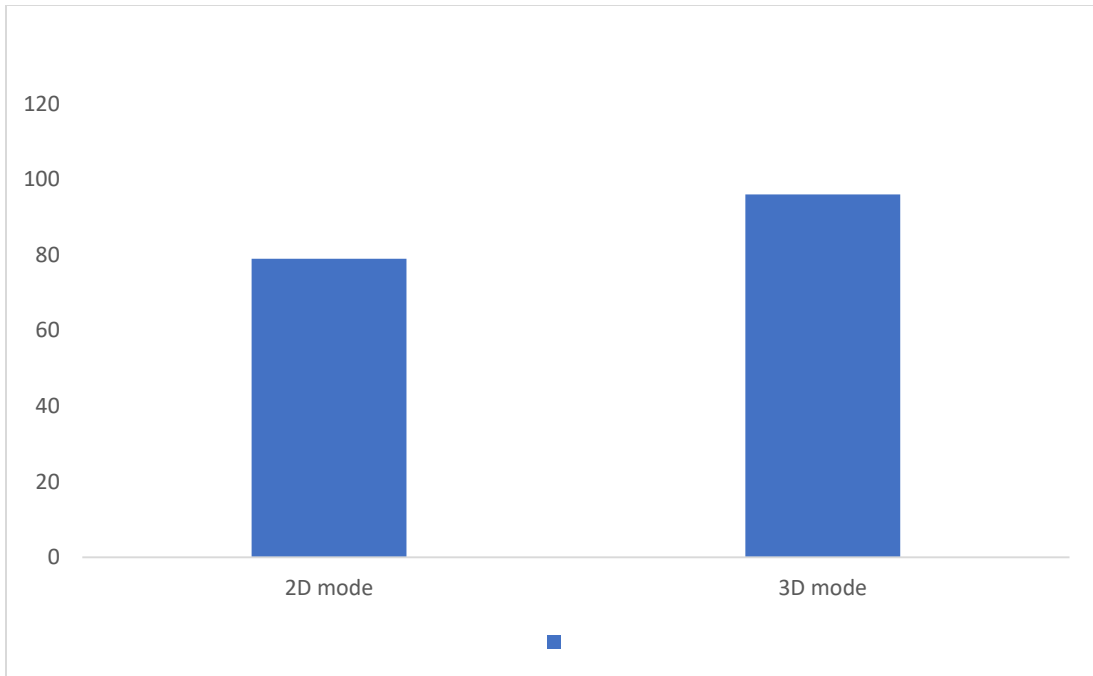


Figure 2: Satisfying visualization of the uterine cavity and the IUD

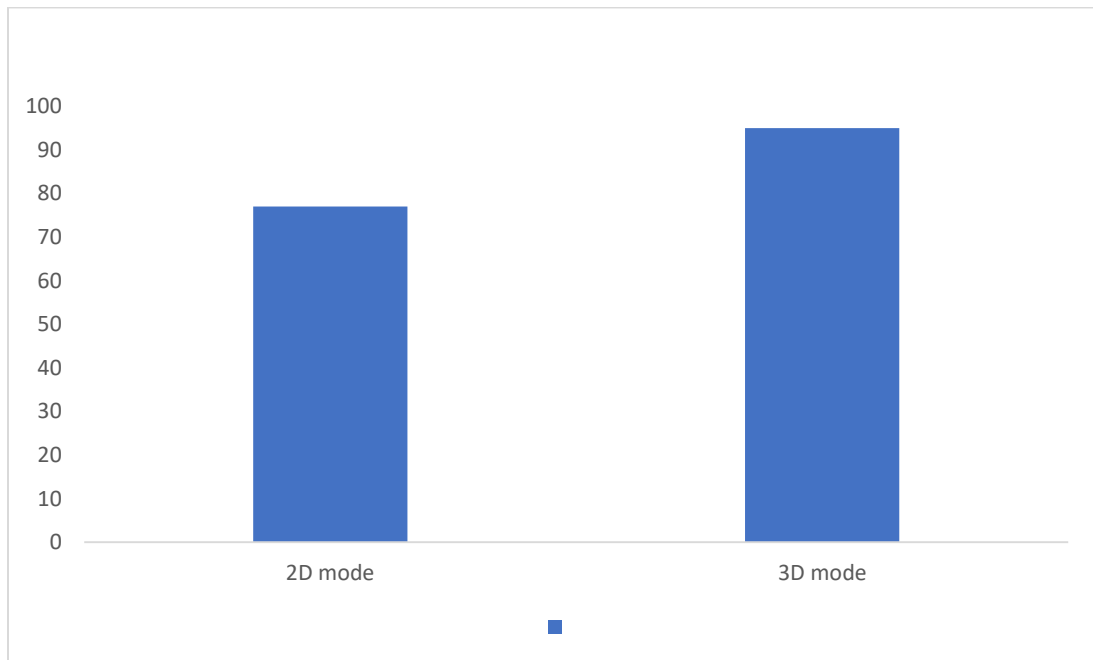


Figure 3: 3D and 2D mode in detection of malposition of the IUD

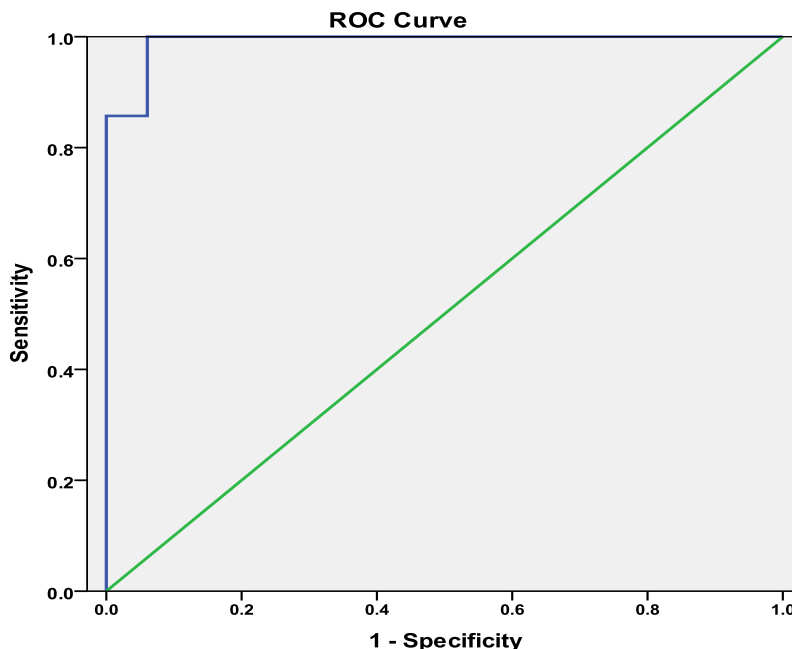


Figure 4: Diagnostic performance of 3D mode in detection of malposition of the IUD.

Discussion

This study showed demographic characteristics among the studied cases. The mean age was 31.3 ± 2.85 . The mean BMI was 27.4 ± 2.40 . The mean Parity was 2.3 ± 0.42 . A study done in 2016 (8) showed that during their study period, 29 patients were included in the analysis, 28 of them (96.55%) were more than 30 years old, 27 patients (93.1%) had a history of one or two deliveries, 16 (55.17%) had previously one or two caesarean sections and 6.9% of all patients were multiparous (more than 3 deliveries). A study reported demographic and clinical characteristics of the study population along with p values from univariate analyses. The study population was young, with a mean age of 32.6 years and 30.1 years for cases and controls, respectively ($p = 0.08$). The mean BMI, and

the distribution of smoking status, null gravidity, uterine position, and presence/location of a second fibroid were

not significantly different between cases and controls. Cases were more likely than controls to have undergone one or more CD ($p = 0.03$).

This present study showed principal indications for sonography in patients with an abnormally located intrauterine contraceptive device (IUD). There were 45.0% with Pelvic pain, 85.0 % with Abnormal Bleeding. There were 21.0% with Localization of IUD, 1.0% Suspected fibroid, 1.0% Suspected ovarian cyst. A study (8) showed that all 29 IUD cases included in their study accused abnormal uterine bleeding and/or chronic pelvic pain. A study (5) showed that the principal

indications for sonography in the 139 patients with a normally located IUD. The two most common indications among these patients were localization of an IUD due to a lost string (n = 34) and to rule out ovarian cyst (n = 30). They showed the indications for sonography among the 28 patients whose IUD was found to be located abnormally on 3D ultrasound. The two most common indications for these examinations were pelvic pain (n = 11 patients) and bleeding.

In a recent study it was found that an overall rate of IUD malpositioning of 16.6% and a rate of IUD malpositioning requiring removal of 8.8% in patients who had a seemingly correct IUD placement at time of insertion, including on 2D TVUS (9), Morbid obesity, prior uterine window or rupture, placement of a copper IUD, and presence of symptoms at time of follow-up ultrasound were significant risk factors for malpositioning. The study also showed that patients who had malpositioned IUDs that were ultimately removed also had higher rates of morbid obesity and symptoms at follow-up and were significantly younger and had a shorter time from IUD insertion to follow-up ultrasound. Their study reinforces the significance of IUD malpositioning detected on 3D ultrasound and identifies novel risk factors for malpositioned IUDs more likely to require removal (9).

This present study showed Length of time between intrauterine contraceptive device (IUD) insertion and sonographic evaluation in patients with an abnormally located device. The mean Length of time was 13.5 ± 1.2 . Other study (2) showed that in six of the seven patients whose IUD was not removed,

it was located at the fundus and in only one was the IUD partly in the cervix. This last patient chose to delay the removal of her IUD until her husband had his vasectomy. The decision on whether or not to remove and replace the IUD was made by each individual referring gynecologist and they do not have detailed information of long-term follow up.

This study showed Satisfying visualization of the uterine cavity and the IUD. There were 79.0% by 2D mode, 96% by 3D mode. A different study (8) showed that using the 2D mode, They obtained a satisfying visualization of the uterine cavity and the IUD in 23 female patients (79.3%). When 3D mode was used, a satisfactory visualization of the IUD and uterine cavity was higher as 96.6% (28 patients).

In contrast, all IUDs were correctly identified with 3D volume ultrasound. It was reported that (10) in the study performed on 96 women who had a 3D sonographic evaluation following IUD insertion, complete visualization of all of the parts of the IUD was achieved in 95% of cases on 3D reconstruction, as opposed to 64% without volume rendering.

This present study showed 3D and 2D mode in detection of malposition of the IUD. There were 95.0% by 3D mode, 77% 2D mode. A trail (3) showed that a malposition of the IUD was noted in 6 cases of levonorgestrel-releasing IUDs (85.7%) and in 19 cooper IUDs (90.47%). Uterine deviation was noted in 12 cases of IUD, all of these proved to be malpositioned. The authors also showed that the detection rate

of malpositioned IUDs using 3D reconstructions (96.1%) was higher than using 2D scans (76.9%). One single case of levonorgestrel-releasing IUD and one single case of copper IUD were recorded in a normal position both in 2D and also 3D (3).

A study showed that around 10% of IUDs are not correctly placed in the uterus and there is some concern that the malposition of an IUD can reduce its contraceptive efficacy. Although there is no recommendation for routine transvaginally ultrasound monitoring, still if women with IUD are symptomatic, ultrasound may be of great use (11).

This present study showed that as regard 3D mode in detection of malposition of the IUD, Sensitivity was 95.0%, Specificity was 90.0%, PPV was 90.47%, and NPV was 94.7%. A clinical study (3) showed that in 83.3% of patients (5 out of 6 cases) with not satisfactory visualized IUDs in 2D, they found a uterine deviation (retroversion, laterodeviation or associations). In all these cases a malpositioned IUD was diagnosed further during the investigation protocol. Contrary, when using 3D technique, only one case out of 12 uterine deviations was improperly evaluated, requiring additional hysteroscopy. Therefore, using 3D technique, IUDs were properly seen in 91.6% cases of uterine deviations, compared with 58,3% when They used classic 2D investigation. Also, another study (5) showed IUDs malposition in cases with uterine deviations, diagnosed with 2D and 3D ultrasound evaluation. However, 3D ultrasound performed better in IUD malposition diagnosis, especially in the

cases of uterine deviations (91.6% versus 58.3%), indifferently the echogenicity of the IUD.

The lack of ultrasound investigation, or the solely use of 2D scan, may imply an incorrect etiological diagnosis of symptomatic IUD cases and also a potential failure of the IUD extraction, due to the unknown certain position of the IUD (12).

Strengths of our study are that 3D ultrasound evaluation and measurement of the uterine cavity was performed by an experienced sonographer with special skills in female pelvic sonography and 3D imaging required to perform a 3D reconstruction. An additional strength was the use of a statistical technique known as penalized maximum likelihood estimation, which was employed to reduce the risk of sparse data bias.

Finally, several limitations of this study should be mentioned. Because it was retrospective, we do not have a full history of the patients' symptomatology and can only report on the indications for scans. We also cannot prove that the malposition of the IUD was directly responsible for the patients' symptoms, other than to report an improvement after the IUD was removed. Additionally, the patients with normally positioned IUD were not followed up, as there was no plan to remove the IUD in these patients.

Conclusion

3D ultrasound assessment followed has proven a higher accuracy when compared to the 2D technique in the visualization of

IUDs and the diagnosis of mal-positioned IUDs. Although 2D ultrasound evaluation is recommended as routine follow-up of all users of IUD, 3D reconstructions should be recommended to symptomatic women when a malposition of the IUDs is suspected, especially in cases with abnormal uterine positions.

References

1. Rana A, Shrestha A, Regmi A, Aryal S, Karki P, Singh R. Intrauterine pregnancy with copper intrauterine contraceptive device in situ: A case report from Nepal. *Ann Med Surg (Lond)*. 2022;82:104781.
2. Nelson AL, Massoudi N. New developments in intrauterine device use: focus on the US. *Open Access J Contracept*. 2016;7:127-41.
3. Nowitzki KM, Hoimes ML, Chen B, Zheng LZ, Kim YH. Ultrasonography of intrauterine devices. *Ultrasonography*. 2015;34:183-94.
4. Wong L, White N, Ramkrishna J, Araujo Júnior E, Meagher S, Costa Fda S. Three-dimensional imaging of the uterus: The value of the coronal plane. *World J Radiol*. 2015;7:484-93.
5. Benacerraf BR, Shipp TD, Bromley B. Three-dimensional ultrasound detection of abnormally located intrauterine contraceptive devices which are a source of pelvic pain and abnormal bleeding. *Ultrasound Obstet Gynecol*. 2009;34:110-5.
6. Abuhamad AZ, Singleton S, Zhao Y, Bocca S. The Z technique: an easy approach to the display of the mid-coronal plane of the uterus in volume sonography. *J Ultrasound Med*. 2006;25:607-12.
7. Benacerraf BR, Shipp TD, Bromley B. Three-dimensional ultrasound detection of abnormally located intrauterine contraceptive devices which are a source of pelvic pain and abnormal bleeding. *Ultrasound in Obstetrics & Gynecology*. 2009;34:110-5.
8. Drăgușin R-C, Florea M, Pătru C, Iliescu D, Cernea N, Tudorache S. Benefits of 3D ultrasound in the diagnosis of intrauterine device malposition. *Obstetrica si Ginecologia*. 2016;64:56-9.
9. Connolly CT, Fox NS. Incidence and Risk Factors for a Malpositioned Intrauterine Device Detected on Three-Dimensional Ultrasound Within Eight Weeks of Placement. *J Ultrasound Med*. 2022;41:1525-36.
10. Lee A, Eppel W, Sam C, Kratochwil A, Deutinger J, Bernaschek G. Intrauterine device localization by three-dimensional transvaginal sonography. *Ultrasound Obstet Gynecol*. 1997;10:289-92.
11. Nadai MN, Martins WP, Ferriani RA, Vieira CS. Three-dimensional ultrasound imaging of an intrauterine device showing copper corrosion. *Ultrasound in Obstetrics & Gynecology*. 2013;42:606-7.
12. Chen XY, Guo QY, Wang W, Huang LL. Three-dimensional ultrasonography versus two-dimensional ultrasonography for the diagnosis of intrauterine device malposition. *Int J Gynaecol Obstet*. 2015;128:157-9.

To cite this article: Mohsen A. Nosseir, Amr A. Sharaf Eldeen, Mohamed T. Soliman, Amira E. Ahmed. Role of 3D-Ultrasound in Patients with Abnormal Uterine Bleeding for Detection of IUCD Malposition. *BMFJ* 2024;41(4):1-9.