

Protective Effects of Quercetin and Phytic Acid (Myo Inositol) on Cadmium Toxicity in Thyroid Gland of Adult Male Albino Rats

Gehad A. Abdullah, Maysara A. Salem, Sherifa A. Morsy, Ola M. Mohamed

Department of Histology and Cell Biology Faculty of Medicine Benha University, Egypt.

Corresponding to: Gehad A. Abdullah, Department of Histology and Cell Biology Faculty of Medicine Benha University, Egypt.

Email: gogoseif622@gmail.com

Received: 2 March 2023

Accepted: 1 April 2023

Abstract

Background: Cadmium (Cd) is a metal. It causes thyroid toxicity.

Objective: To explore the possible protective effects of quercetin (QUE) and phytic acid on Cd induced thyroid toxicity.

Materials and Methods: 54 rats divided into two groups. Group I (control), group II subdivided into four subgroups; subgroup IIA (rats were injected s.c with Cd in a dose of 2 mg/kg for 2 weeks), subgroup IIB (rats were injected as subgroup IIA & QUE in a dose of 500 mg/ kg orally for 2weeks), subgroup IIC (rats were injected as subgroup IIA & phytic acid at a dose 360 mg/ kg orally for 2 weeks), subgroup IID (rats were injected with Cd as subgroup IIA & QUE as subgroup IIB & phytic acid as subgroup IIC). Thyroid gland specimens were taken and prepared for histological, immunohistochemical examination. **Results:** Subgroup IIA disorganized follicular cells with small dark nuclei, fused follicles with desquamation of cells, significant marked increase ($p < 0.01$) in collagen fibres and PCNA between follicles and significant decrease ($p < 0.01$) in colloid. Subgroups IIB and IIC showed improvement of some histological microscopic changes, significant decrease ($P < 0.01$) in collagen fibres deposition and PCNA immunostaining compared with subgroup IIA, while subgroup IID

showed histological architecture near to control group. **Conclusion:** This work concluded that each of QUE and IP6 can ameliorate Cd induced thyroid follicular cells toxicity, but their co-administration can give better results

Key words: Thyroid gland, Cd, Quercetin, Phytic Acid.

Introduction

The thyroid gland is enveloped by a thin fibrous capsule, with a narrow septum that divides the thyroid into lobes. The gland is richly vascularized and it is supplied with blood by the upper and lower thyroid artery. Vein drainage is supplied via upper, lower, and middle thyroid veins. Lymph drainage is also well developed and there is pronounced communication between the

right and left lobes, via the isthmus. Nerves are formed on capsule, and they come from sympathetic trunks and vagus nerves¹.

Cadmium (Cd) is one of the most toxic environmental pollutants derived from natural sources as well as human activities. Contaminated air, water, food and cigarette smoke are the major sources of human Cd

exposure². Because of its extremely long biological half-life and low excretion rate, Cd may accumulate inside the body, causing a broad range of cytotoxic effects, especially to the kidneys, liver and muscles³. The presence of cysteine-rich proteins containing thiol groups able to bind Cd makes even the thyroid gland a potential site of Cd deposition, and it has been reported that Cd blood concentration correlates positively with its accumulation in thyroid tissue⁴. Cd concentrations in the thyroid gland of people living in a Cd-polluted area of Japan were three times higher compared to those residing in non-polluted areas⁵.

Quercetin is a bioactive compound that is widely used in botanical medicine and traditional Chinese medicine due to its potent antioxidant activity. Antioxidant activities of QUE including its effects on glutathione (GSH), enzymatic activity, signal transduction pathways, and reactive oxygen species (ROS) caused by environmental and toxicological factors. Chemical studies on quercetin have mainly focused on the antioxidant activity of its metal ion complexes and complex ions⁶.

Phytic acid is generally referred to as an anti-nutrient due to the food micronutrients chelating ability, making them un-absorbable and thus low bioavailability⁷. However, this effect is mainly linked to diets that are simultaneously poor in trace elements and high in phytic acid intake. Its bioavailability may be influenced by the micronutrients binding with other food components and the metal ion: phytic acid molar ratio should also be considered⁸. On the other hand, several studies have been done, both in vitro and in vivo, showing

strong anti-cancer activity evidence for phytic acid⁹.

The aim of this study was to explore the possible protective effects of Quercetin and phytic acid on Cd induced thyroid follicular cells toxicity in adult male albino rats.

Material and methods

Drugs and Chemicals

- Cadmium chloride:** Cd chloride 98%, product no. 208299 were purchased from **Sigma Chemical Co., St. Louis, MO, USA.** as powder (50 gm). Total 100 mg Cd Cl₂ 98% powder were dissolved in 10 ml distilled water and then were injected s.c at a dose of (2 mg/kg/day) for 2 weeks to the assumed rats¹⁰.
- Quercetin:** QUE was purchased from **Sigma Chemical Co., St. Louis, MO, USA.** as a powder (500 mg). Total 500 mg QUE powder were dissolved in 10 ml of 0.1% Tween-80 then were given orally by mouth gavage at a dose of (50 mg/kg) for 2 weeks to the assume rats¹¹.
- Phytic acid:** phytic acid sodium salt hydrate was purchased from **Sigma Chemical Co., St. Louis, MO, USA.** as a powder (3600 mg). Total 3600 mg phytic acid salt powder were dissolved in 10 ml distilled water then were given orally by mouth gavage at a dose of (360 mg/kg) for 2 weeks to the assumed rats¹².

Animals and Diet:

54 adult male Sprague Dawely rats aged about three months and weighing (150–250 g) which were purchased from animal house, Faculty of Veterinary Medicine Moshtahar, Benha University and utilized according to the guidelines of laboratory animal's care.

Experimental Design:

An experimental study was done on January 2021. After one week of housing, 54 adult male albino rats weighting about 200gm were randomly divided into two groups:

Group I (Control Group): n = 30 rats equally divided into 5 subgroups:

- **Subgroup Ia:** rats were kept without any intervention and received only water and normal formula of feeding for 2 weeks.

- **Subgroup Ib:** everyone was injected s.c with 0.4 ml of normal saline (vehicle of Cd group) for 2 weeks.

- **Subgroup Ic:** rats were injected as subgroup b and received orally by mouth gavage about 0.8 ml 0.1% Tween-80 in distilled water (vehicle of QUE group) for 2 weeks.

- **Subgroup Id:** rats were injected as subgroup b and received orally by mouth gavage about 1 ml of distilled water (vehicle of IP6 group) for 2 weeks.

- **Subgroup Ie:** rats were injected s.c as subgroup b and received orally as subgroup c and received orally as subgroup d for 2 weeks.

Group II (Experimental group): n = 24 rats equally divided into 4 subgroups:

- **Subgroup IIA (Cadmium toxicity group):** were injected subcutaneously (s.c) with Cd Cl₂ (2mg/kg/day).

- **Subgroup IIB (Quercetin Group):** rats were received Cd Cl₂ as subgroup IIA and received QUE (50 mg/kg) dissolved in 0.1% Tween-80 in distilled water orally by mouth gavage

- **Subgroup IIC (phytic acid Group):** rats were received Cd Cl₂ as subgroup IIA and received IP6 (360 mg/kg) dissolved in distilled water orally by mouth gavage.

- **Subgroup IID (Quercetin and phytic acid Group):** rats were received Cd Cl₂ as

subgroup IIA and QUE as subgroup IIB and IP6 as subgroup IIC.

Sample preparation

The thyroid gland from the rats will be taken and fixed in 10% buffered formalin, embedded in pure paraffin wax (melting point of 58 °C), and then mounted into blocks and left at 4 °C until the time of use. The paraffin blocks will be sectioned using the microtome at a thickness of 5 mm and mounted on clean glass slides and then left in the oven at 40 °C for drying.

Histological and Immunohistochemical Studies

Paraffin sections of thickness (5-7 μm), mounted on glass slides for H&E¹³ stain to examine histological changes in various groups and sirius red staining for demonstration of collagen fibres deposition¹⁴ and PAS staining for demonstrating amount of colloid¹⁴.

Other sections were mounted on +ve charged slides for immunohistochemical staining:

PCNA¹⁶ is a helper protein of DNA polymerase enzymes, necessary for DNA synthesis and is used as a standard marker for proliferating cells. It is a rabbit polyclonal antibody (catalogue number ab15497, Abcam, Cambridge, UK). Immunostaining required pre-treatment, this was done by boiling for 10 minutes in 10 mmol/l citrate buffer (catalogue number AP 9003) (pH 6) for antigen retrieval and leaving the sections to cool in room temperature for 20 minutes. Then, the sections were incubated for one hour with the primary antibody. Immunostaining was completed by the use of Ultravision detection system (catalogue number TP - 015- HD). Counterstaining was done using Mayer's hematoxylin (catalogue number TA- 060- MH). Citrate buffer, Ultravision

detection system and Mayer's hematoxylin were purchased from Lab Vision Thermo Scientific (Fremont, California, USA). Small intestine was used as a positive control sections. Positive reaction appeared as brown nuclear coloration. On the other hand, one of the thyroid sections was used as a negative control by passing the step of applying the primary antibody.

Morphometric Study

The mean area percentage for collagen fibres deposition (Sirius red stain), colloid area (PAS stain) & PCNA immunostaining were quantified in 15 images from 15 non-overlapping fields of each group rats using Image-Pro Plus program version 6.0 (Media Cybernetics Inc., Bethesda, Maryland, USA).

Statistical Methods

Statistical analysis was conducted using SPSS (version 21, Chicago, IL, USA). Qualitative data were presented as number and percentage; while quantitative parametric data (normally distributed) was presented as mean and standard deviation and quantitative non-parametric data (abnormally distributed) was presented as median. The results will be considered significant when the probability is less than 5% (p value: 0.01).

Results:

1- Hematoxylin and Eosin results:

Group I (Control group):

The light microscopic examination of subgroups in control group showed nearly the same structures. Sections in the thyroid gland of the control group showed normal histological architecture in the form of multiple thyroid follicles that were uniformly distributed and variable sized. Follicles were filled with acidophilic

homogenous colloid with few peripheral vacuolation. The lining follicular cells were flattened to cuboidal cells with flat to round nucleus with some interfollicular cells (**Fig., 1a**).

Group II (Experimental group):

Subgroup IIA (Cadmium group):

Cadmium group showed disorganization of thyroid follicles. Some fused follicles were noticed and the colloid was interrupted in some follicles but other follicles exhibited markedly vacuolated colloid. Thyroid follicles appear as flattened cells with dark small nuclei and there are cellular infiltration between follicles. Follicular cells were seen desquamated into the lumen (**Fig., 1b**).

Subgroup IIB (Quercetin treated group):

Quercetin group showed only slight improvement in regularity of follicles and tissue arrangement. Some restore their normal architecture but some of them still small in size filled with colloid with peripheral vacuolation. Some follicular cells still showing dark stained nuclei (**Fig., 1c**).

Subgroup IIC (Phytic Acid treated group):

Phytic acid treated rats showed more improvement compared to the pervious group that most of the thyroid follicles almost restored their normal architecture except some of them still small in size. The follicular lumen is filled with homogenous acidophilic colloids that show peripheral small vacuoles. Follicular cells show normal round nucleus (**Fig., 1d**).

Subgroup IID (phytic acid and quercetin treated group):

Phytic acid and quercetin treated group showed normal appearance of thyroid follicle with normal colloid almost restore their normal architecture. The follicular lumen is filled with homogenous acidophilic colloid with peripheral small

vacuoles. Follicular cell showed normal round nuclei (**Fig., 1e**).

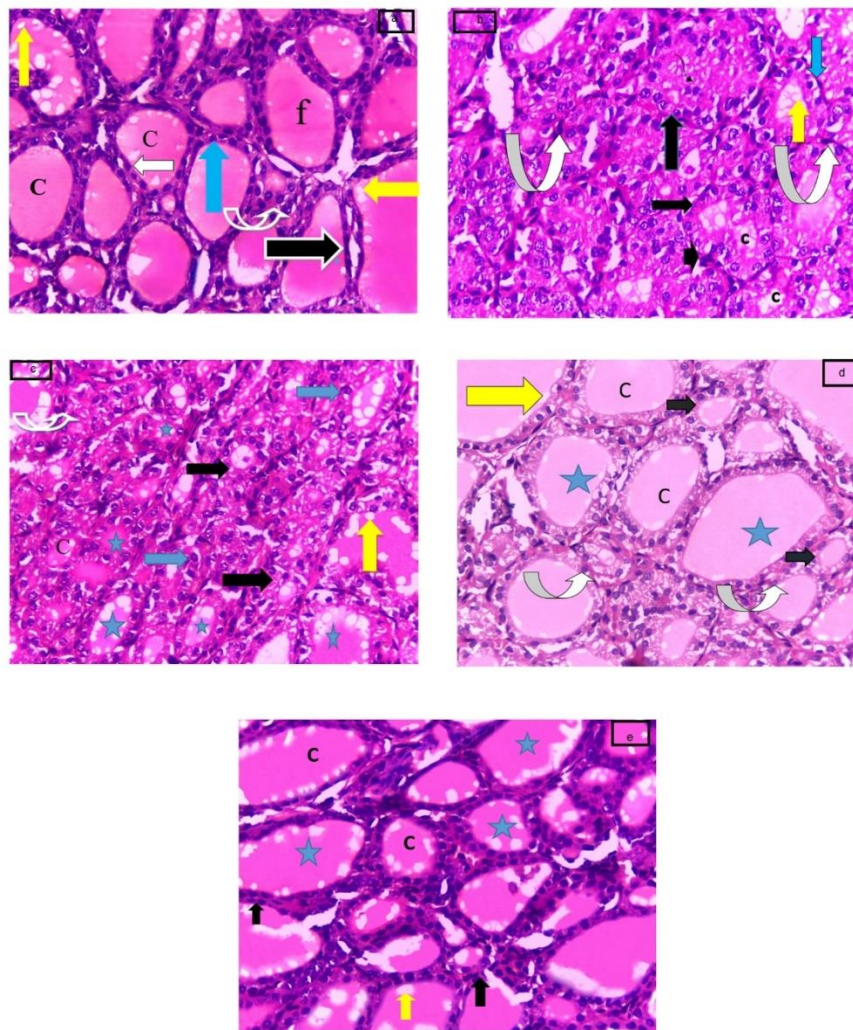


Fig.1. (a) A photomicrograph of a section in the thyroid gland of a rat of control group showing apparently normal thyroid follicles (f) lined with a single layer of flat (black arrow) or cubical follicular cells (blue arrow). Follicular cells exhibiting oval to rounded nuclei (white arrow). The follicular lumen is filled with homogenous acidophilic colloid (C) with peripheral small vacuoles (yellow arrows). There is some interfollicular cells between follicles (white curved arrow), (b) Subgroup IIA showing disorganized and fused thyroid follicles (black arrows) with desquamated epithelial cells (thin curved arrow) in their lumen. The follicles have diminished colloid (C) with more vacuolation (yellow arrow). The follicles lined with follicular cells with dark flat or round nuclei (curved white arrow) with vacuolated cytoplasm (blue arrow). There is cellular infiltration between follicles (arrow head), (c) Subgroup IIB showing that some of the follicles of thyroid (*) restore their normal architecture and some of them still small in size (black arrows). Some follicles are filled with colloid (c) with peripheral vacuolation (yellow arrow). The follicles lined with follicular cells with round nuclei (blue arrows). Some follicular cells still showing dark nuclei (curved arrow), (d) Subgroup IIC A photomicrograph of a section in the thyroid gland of a rat from subgroup C showing that most of the follicles of thyroid (*) restore their normal architecture except little of them still small in size (black arrows). Follicular cells show normal round nucleus (curved arrows). The follicular lumen is filled with homogenous acidophilic colloids (C) that show peripheral small vacuoles (yellow arrow), (e) Subgroup IID showing that most of the follicles of thyroid (*) restore their normal architecture. Follicular cell showing normal round nuclei (black arrows). The follicular lumen is filled with homogenous acidophilic colloids (C) that show peripheral small vacuoles (yellow arrow) (**H&E X400**).

Sirius Red stains results:

Group I (Control group): It showed minimal collagen fibers accumulation between thyroid follicles (**Fig., 2a**).

Group II (Experimental group):

- Subgroup IIA (cadmium group):** It showed marked collagen fibers accumulation between thyroid follicles (Fig., 2b).
- Subgroup IIB (quercetin treated group):** It showed mild collagen fibers accumulation between thyroid follicles (Fig., 2c).
- Subgroup IIC (phytic acid treated group):** It showed few collagen fibers accumulation between thyroid follicles (Fig., 2d).
- Subgroup IID (quercetin and phytic acid treated group):** It showed minimal collagen fibers accumulation between thyroid follicles (Fig., 2e).

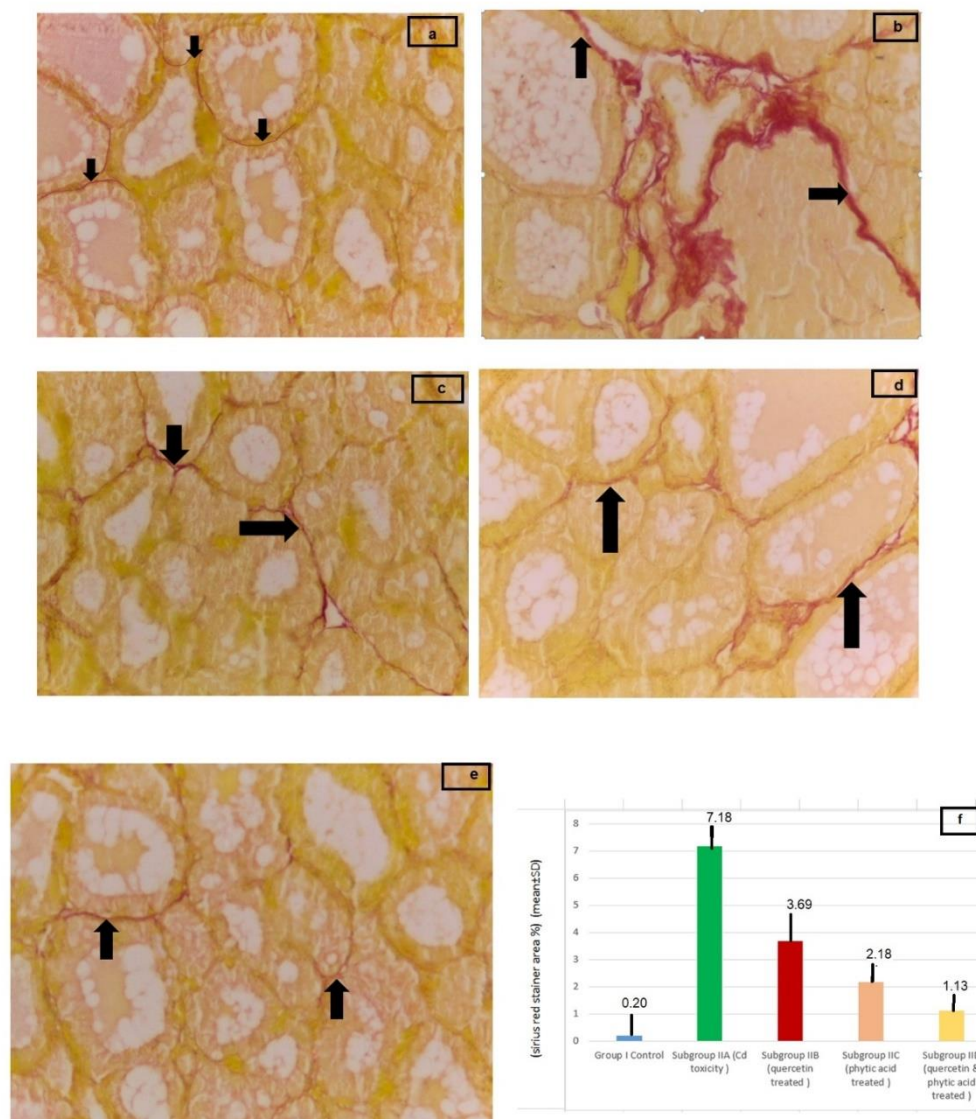


Figure 2: A Photomicrograph of section in the thyroid gland (a) control group showing minimal collagen fibres deposition between the follicles of thyroid (arrows), (b) Subgroup IIA showing marked collagen fibres deposition between thyroid follicles (arrows), (c) Subgroup IIB showing mild deposition of collagen (arrows), (d) Subgroup IIC showing few deposition of collagen (arrows), (e) Subgroup D showing minimal deposition of collagen (arrows) (Sirius red X400). (f) Histogram Showing the mean \pm SD of Sirius % area between Group I, Subgroups IIA, IIB, IIC & IID.

PAS stain results:

Group I (Control group): It showed strong PAS reaction in the colloid and moderate reaction in the basement membrane (Fig., 3a).

Group II (experimental group)

Subgroup IIA (cadmium group): It showed weak PAS reaction of both colloid and basement membrane. Most follicles showed colloid retraction (Fig., 3b).

Subgroup IIB (quercetin treated group): It showed mild PAS reaction in the colloid and the basement membrane. (Fig., 3c).

Subgroup IIC (phytic acid treated group): It showed moderate PAS reaction in the colloid and the basement membrane. (Fig., 3d).

Subgroup IID (phytic acid and quercetin treated group): It showed strong PAS reaction in the colloid and moderate reaction in the basement membrane more or less similar to control group (Fig., 3e).

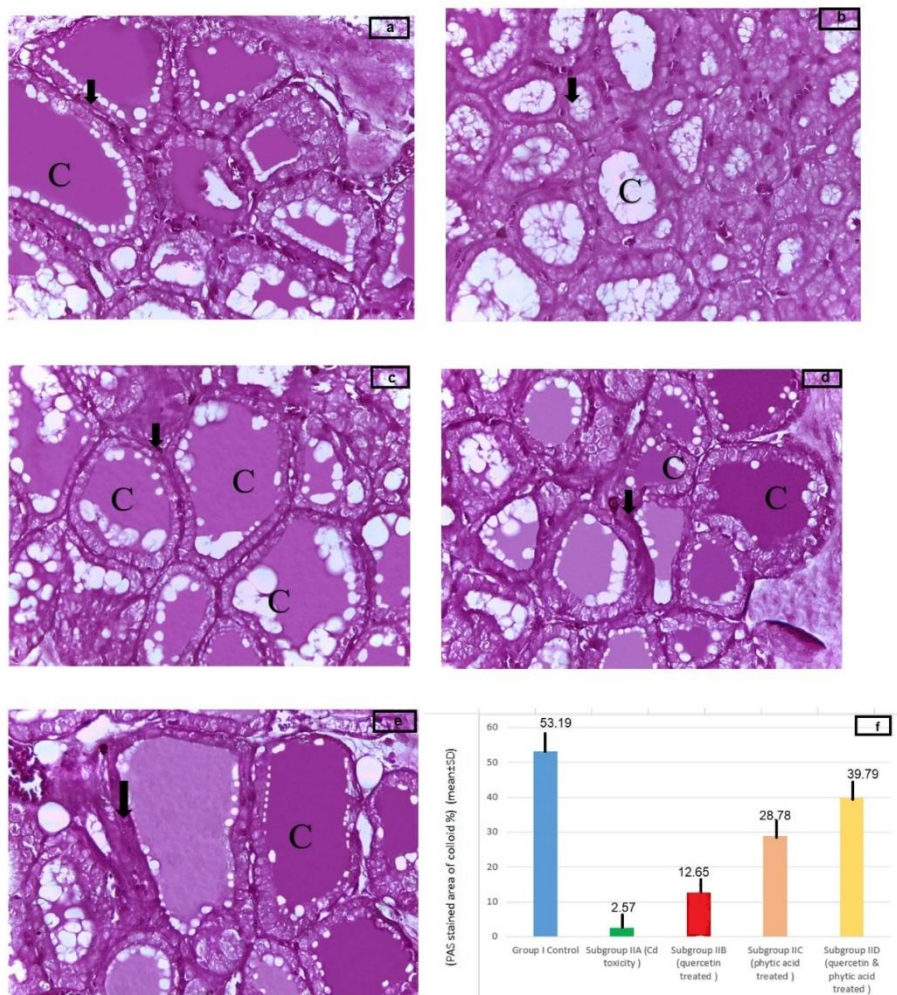


Fig.3: A photomicrograph of section in the thyroid gland (a) Control group showing strong PAS reaction of abundant colloid "magenta in colour" (C) and moderate reaction in the basement membrane (arrow), (b) Subgroup IIA Cadmium treated group showing weak PAS reaction in the colloid and most follicles show colloid retraction (C).The basement membrane shows weak PAS reaction (arrow), (c) Subgroup IIB quercetin treated group Showing mild PAS reaction of colloid and decreased colloid in some follicles (C). The basement membrane shows moderate reaction (arrow), (d) Subgroup IIC phytic acid treated group showing moderate PAS reaction of colloid and decreased colloid in some follicles (C). The basement membrane shows moderate reaction (arrow), (e) Subgroup IID quercetin and phytic acid treated group showing strong PAS reaction of colloid and decreased colloid in some follicles (C). The basement membrane shows moderate reaction (arrow) (PAS x 400). (f) Histogram showing the mean \pm SD of PAS % area between Group I, Subgroups IIA, IIB, IIC & IID.

Immunohistochemical results:

Group I (Control group): Sections in the thyroid gland of the control group demonstrated weak positive PCNA nuclear immune reactivity (Fig., 4a).

Group II (Experimental group)

Subgroup IIA: Examination of thyroid gland strong nuclear immune reactivity (Fig., 4b).

Subgroup IIB (quercetin treated group): It showed moderate PCNA nuclear immune reactivity (Fig., 4c).

Subgroup IIC (phytic acid treated group): It showed mild PCNA nuclear immune reactivity (Fig., 4d).

Subgroup IID (phytic acid and quercetin treated group): It showed minimal positive PCNA nuclear immune reactivity (Fig., 4e).

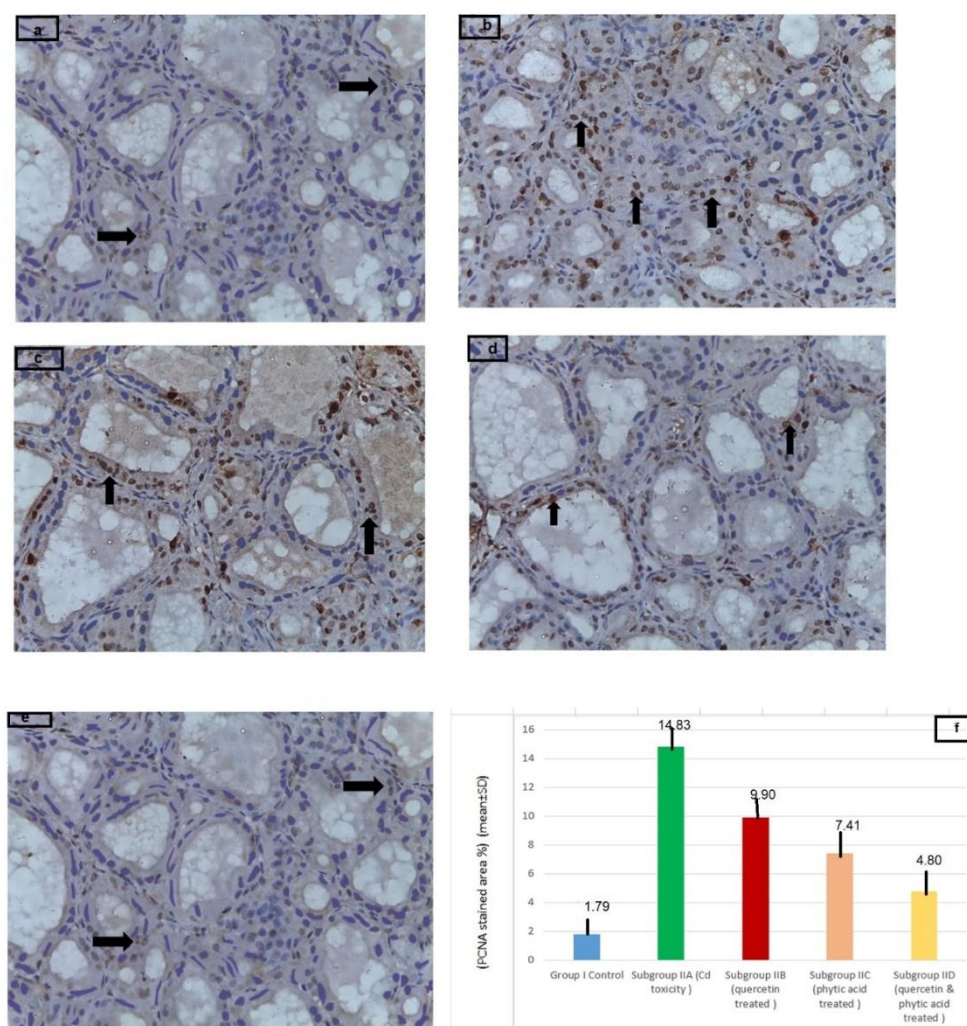


Fig.4: Photomicrograph of a section in the thyroid gland. (a) control rat showing weak positive immune reaction of PCNA (black arrows), (b) Subgroup IIA showing strong positive immunoreactivity of PCNA as a brown cytoplasmic immune reaction in the follicular cells (black arrows), (c) Subgroup IIB showing moderate nuclear immune reaction for PCNA (black arrows), (d) Subgroup IIC showing mild nuclear immune reaction for PCNA (black arrows), (e) Subgroup IID rat showing minimal positive immune reaction of PCNA (black arrows) (PCNA x 400). (f) Histogram showing the mean \pm SD of PCNA% area between Group I, Subgroups IIA, IIB, IIC & IID.

Morphometric and Statistical Results

The mean area % and standard deviation (SD) of collagen fibres deposition and PAS and PCNA immunostaining of all groups was represented in (Table 1) and (Histograms 1,2,3). There was a significant decrease ($P < 0.01$) in mean area % of collagen fibres and PCNA of group I,

subgroups IIB, IIC compared with subgroup IIA and insignificant increase ($P < 0.01$) in mean area % of subgroup IID compared with group I. There was a significant increase ($P < 0.01$) in mean area % of colloid of group I, subgroups IIB, IIC compared with subgroup IIA and insignificant increase ($P < 0.01$) in mean area % of subgroup IID compared with group I.

Table (1): Showing the mean area % of collagen fibres, colloid by PAS, PCNA immuno-expression \pm SD in all groups by ANOVA with Post Hoc LSD test.

	Group I	Subgroup IIA	Subgroup IIB	Subgroup IIC	Subgroup IID	P value
Sirius red %	0.20 \pm 0.04	7.18 \pm 1.44	3.69 \pm 0.54	2.18 \pm 0.14	1.13 \pm 0.07	<0.001*
Post-hoc		P1=<0.001*	P1=<0.001* P2=<0.001*	P1=<0.001* P2=<0.001* P3=<0.001*	P1=0.03* P2=<0.001* P3=<0.001* P4=0.01*	
PAS %	53.19 \pm 12.84	2.57 \pm 0.51	12.65 \pm 1.33	28.78 \pm 5.76	39.79 \pm 7.96	<0.001*
Post-hoc		P1=<0.001*	P1=<0.001* P2=0.025*	P1=<0.001* P2=<0.001* P3=<0.001*	P1=0.001* P2=<0.001* P3=<0.001* P4=0.012*	
PCNA %	1.79 \pm 2.63	14.83 \pm 1.30	9.90 \pm 1.65	7.41 \pm 2.57	4.80 \pm 3.10	<0.001*
Post-hoc		P1=<0.001*	P1=<0.001* P2=0.04*	P1=<0.001* P2=<0.001* P3=<0.001*	P1=0.029* P2=<0.001* P3=<0.001* P4=0.002*	

Data expressed as Mean \pm SD; SD: standard deviation; P: Probability; *: significance <0.05; Test used: One way ANOVA followed by post-Hoc tukey; P1: significance vs Group I, P2: significance vs Subgroup IIA, P3: significance vs Subgroup IIB, P4: significance vs Subgroup IIC.

Discussion

The thyroid system plays a pivotal role in the body homeostasis and functioning of the nervous, cardiovascular and reproductive systems, and of body growth control; hence, putative thyroid disruptors can cause significant impairments in living organs⁴.

Cadmium is a metal with established endocrine disrupting activities. This toxic metal is widespread in the environment both naturally and as a pollutant emanating from industrial, agricultural and other sources. The main routes of exposure are via the digestive tract and inhalation¹⁷.

Quercetin is one of the most omnipresent flavonoids. QUE prevents oxidative damage and cell death by preventing lipid peroxidation and scavenging oxygen free radicals. QUE has also been shown to protect germ cells from Cd-induced toxicity¹⁸.

Phytic acid (inositol hexaphosphate; IP6) is the principal storage form of phosphorus in many plant tissues, especially bran and seeds¹⁹. IP6 decreases Mn and Ca absorption. Cd accumulation was estimated in liver and kidney and was increased by the addition of Ca. IP6 inhibits the increase in tissue Cd promoted by supplements but does not influence tissue Cd values²⁰.

Section obtained from subgroup IIA (Cd group) stained by H & E revealed disorganization of thyroid follicles and desquamation of thyroid cells. Thyroid cells appeared flattened with dark stained nucleus, irregular follicular pattern with microfollicoli. Small sized follicles with ruptured wall and small amount of colloid and there is cellular infiltration between follicles. It showed significant increase (P <0.01) in collagen fibres deposition and PCNA immunostaining compared to

control group. It showed significant decrease of colloid in the Cd group with loss of clarity of basement membrane ($p < 0.01$).

These results agreed with some investigators^{21, 22, 23, 24, 25, 26} who stated that Cd have cytotoxic effect on thyroid, these pathological effects are due to Cd toxicity that induces mitochondrial damage and oxidative stress, which forms excess ROS. Normally, ROS are balanced by natural antioxidant enzymes, but when an imbalance occurs between these ROS and natural antioxidants an oxidative stress condition is created, the mitochondrial injury causes release of cytochrome c and activation of caspase pathways that lead to apoptosis and induced thyrotoxic effects.

Some investigators^{27, 28, 29} who reported increased amount of collagen fibres in thyroid glands of rats treated with Cd. High significant increase in collagen fibres deposition (fibrosis) at the interfollicular space was detected in Cd group. Authors stated that Cd induced fibrosis by degranulation of mast cell with releasing of its cytokine tryptase. This cytokine stimulates fibroblast proliferation and collagen fibres formation. Also, Cd improvement may be due to specific mechanisms. First, they clean the ROS of QUE, reducing lipid peroxide production and increasing the activity of antioxidation enzymes. Second, they chelate Cd, reducing Cd deposition and altering in vivo levels of other basic metal ions. The administration of IP6 in subgroup IIC revealed more improvement in the regularity of thyroid follicle and tissue arrangement and increase amount of colloid in follicles but still some follicle is small in size. There was a significant decrease ($P < 0.01$) in collagen fibres

toxicity reported to decrease selenium. This deficiency may lead to activation of fibrosis through inflammatory reaction and excess stimulation of growth factor.

Some investigators^{4, 22, 26, 27} who reported decreased amount of colloid in thyroid glands of rats treated with Cd. investigators^{4, 30} who reported increase in area % of PCNA in thyroid glands of rats treated with Cd. this might represent the early resistant stage of the gland in which thyroid follicles were under stress of the toxicant and were trying to cope with this condition by increase follicular growth³¹.

The administration of QUE in subgroup IIB revealed slight improvement in the regularity of thyroid follicle and tissue arrangement but colloid was still little and some follicles showed vacuolated colloid, still some follicles were small in size. There was a significant decrease ($P < 0.01$) in collagen fibres deposition and PCNA staining expression compared to subgroup IIA. It showed that the colloid was significantly increased ($p < 0.01$).

These results agreed with some investigators^{17, 32, 33, 34} who stated that QUE have protective effect on Cd toxicity. This

deposition and PCNA staining expression compared to subgroup IIB. It showed that the colloid was significantly increased ($p < 0.01$).

These results agreed with some investigators^{19, 35, 36, 37} who stated the protective effect of phytic acid on Cd toxicity the improvement may be due to IP6 increases oxidative/nitroductive status and restores enzyme activities almost to normal levels. IP6 is a natural antioxidant that protects against disease and prevents the development of tumours. Moreover, IP6 is known to suppress Fenton reactions

and the subsequent release of hydroxyl radicals by chelating cations of iron. Authors administrated that IP6 also reportedly inhibited the development of ROS in biological tissues, thereby protecting against free radical damage in cells and tissue following inflammation, hypoxia or exposure to radiation. In addition, scavenging of superoxide radicals prevents the formation of complexes of ADP and iron that cause lipid peroxidation in vivo and in vitro. Accordingly, IP6 was shown to inhibit lipid peroxidation in animal studies.

The administration of QUE & IP6 in subgroup IID revealed more improvement in the regularity of thyroid follicle and tissue arrangement and increase amount of colloid in follicles but still some follicle is

Conclusion

This work concluded that each of QUE and IP6 can ameliorate Cd induced thyroid

small in size. There was a significant decrease ($P < 0.01$) in collagen fibres deposition and PCNA staining expression compared to subgroup IIC. It showed that the colloid was significantly increased ($p < 0.01$) and insignificant ($P < 0.01$) in collagen fibres deposition and PCNA staining expression compared to control group. It was noticed that the group treated with Cd and QUE plus IP6 showed better amelioration of the harmful effect of Cd on the histological structure of thyroid gland. No previous results were well-matched the findings of that combination between QUE & IP6 but this effect may be due to synergism between the effect of both QUE & IP6. The antioxidant levels are tightly regulated within the cell and can significantly affect cell behaviour, characteristics and survival.

follicular cells toxicity, but their co-administration can give better result.

References

1. Asa, S. L.; Ezzat, S.: Endocrine organs. The Cancer Handbook: John Wiley and Sons Ltd: West Sussex, England.; (2007) pp 611-623.
2. Capriglione, F.; Maiuolo, J.; Celano, M. Damante, G.; Russo, D.; Bulotta, S. et al.: Quercetin Protects Human Thyroid Cells against Cadmium Toxicity. International Journal of Molecular Sciences. (2021); 22(13): 6849-6858.
3. Genchi, G.; Sinicropi, M. S.; Lauria, G.; Carocci, A.; Catalano, A.: The effects of cadmium toxicity. International journal of environmental research and public health. (2020); 17(11):1-24.
4. Buha, A.; Matovic, V.; Antonijevic, B.; Bulat, Z.; Curcic, M. Renieri E. A.; et al.: Overview of cadmium thyroid disrupting effects and mechanisms. International Journal of Molecular Science. (2018); 19(5):1501-1520.
5. Uetani, M.; Kobayashi, E.; Suwazono, Y.; Honda, R.; Nishijo, M. Nakagawa H.; et al.: Tissue cadmium (Cd) concentrations of people living in a Cd polluted area, Japan. Biometals. (2006); 19(5): 521-531.
6. Xu, D.; Hu, M. J.; Wang, Y. Q.; Cui, Y. L.: Antioxidant activities of quercetin and its complexes for medicinal application. Molecules.(2019); 24(6):1-15.
7. Thavarajah, P.; See, C. T.; Vandenberg, A.: Phytic acid and Fe and Zn concentration in lentil (*Lens culinaris* L.) seeds is influenced by temperature during seed filling period. Food Chemical.(2010); 122(1):254-259.
8. Lopez, H. W.; Leenhardt, F.; Coudray, C.; Remesy, C.: Minerals and phytic acid interactions: is it a real problem for human nutrition? International journal of food science & technology.(2002); 37(7):727-739.
9. Bloot, A. P. M.; Kalschne, D. L.; Amaral, J. A. S.; Baraldi, I. J.; Canan, C.: A review of phytic

- acid sources, obtention, and applications. *Food Rev Int.*(2021); 1-20.
10. Sassia, S.; Amine, B.; Nadia, B.; Hadda, A.; Smail, M.: Investigation of single and combined effects of repeated oral cadmium and lead administration in ewes. *Scientific African.*(2021);13: 1-10.
 11. Guan, T.; Xin, Y.; Zheng, K.; Wang, R.; Zhang, X.; Jia, S.; Li, S.; Cao, C. and Zhao, X. :
:
 13. Bancroft, J. D. and Layton. C.: The hematoxyline and eosin. *Bancroft's theory & practice of histological Techniques.* Eds. Suvarna, S. K.; Layton, C. and Bancroft, J. D. 8th ed., ch. 10, Churchill Livingstone, Elsevier, Philadelphia,(2019); pp 126 -138.
 14. Rittié, L.: Method for picosirius red-polarization detection of collagen fibers in tissue sections. *Methods of Molecular Biology.*(2017); 1627: 395-407.
 15. Fu, D. A. and Campbell-Thompson, M. :Periodic Acid-Schiff Staining with Diastase. *Methods in Molecular Biology.*(2017); 1639: 145-149.
 16. Jackson, P. and Blythe, D.: Immunohistochemical techniques. In: Bancroft, J.D. Eds. *Bancroft's theory & practice of histological techniques.* Eds. Suvarna, S. K.; Layton, C. and Bancroft, J. D. 7th ed., ch. 18, Churchill Livingstone, Elsevier, Philadelphia,(2013) pp 381-426.
 17. Khatun, J.; Intekhab, A. and Dhak, D. : Effect of uncontrolled fertilization and heavy metal toxicity associated with arsenic (As), lead (Pb) and cadmium (Cd), and possible remediation. *Toxicology.* (2022); 477: 153274.
 18. Wang, J.; Zhu, H.; Wang, K.; Yang, Z. and Liu, Z. : Protective effect of quercetin on rat testes against cadmium toxicity by alleviating oxidative stress and autophagy. *Environmental Science and Pollution Research.*(2020); 27(20): 25278-25286.
 19. Manzoor, A., Nabi, A.; Shiekh, R. A.; Dar, A. H.; Usmani, Z. Altaf, A.; Khan, S. A. and
 25. Yousif, A. S. and Ahmed, A. A. : Effects of cadmium (Cd) and lead (Pb) on the structure and function of thyroid gland. *African Journal of Environmental Science and Technology.* (2009); 3(3): 78-85.
 - Metabolomics analysis of the effects of quercetin on renal toxicity induced by cadmium exposure in rats. *Biometals.*(2021); 34(1): 33-48.
 12. Bhowmik, A.; Ojha, D.; Goswami, D.; Das, R.; Chandra, N. S. et al.: Inositol hexa phosphoric acid (phytic acid), a nutraceuticals, attenuates iron-induced oxidative stress and alleviates liver injury in iron overloaded mice. *Biomed Pharmacother.* (2017); 87: 443-450.
 - Ahmad, S.: Phytates. *Handbook of Plant and Animal Toxins in Food.* Chemical Rubber Company Press.(2022); 27-36.
 20. Mohamed, T. M.; Salama, A. F.; Nimr, T. M. E. and Gamal, D. M. E. :Effects of phytate on thyroid gland of rats intoxicated with cadmium. *Toxicology and industrial health.*(2015); 31(12): 1258-1268.
 21. Liu, Z.; Cai, L.; Liu, Y.; Chen, W. and Wang, Q. : Association between prenatal cadmium exposure and cognitive development of offspring: A systematic review. *Environmental Pollution.* (2019); 254.
 22. Yang, H.; Xing, R.; Liu, S. and Li, P. : Effect of Fucoxanthin administration on thyroid gland injury induced by cadmium in mice. *Biological Trace Element Research.*(2021); 199(5): 1877-1884.
 23. Bekheet, S. H. : Comparative effects of repeated administration of cadmium chloride during pregnancy and lactation and selenium protection against cadmium toxicity on some organs in immature rats' offsprings. *Biological trace element research.*(2011);144(1): 1008-1023.
 24. Luca, E.; Fici, L.; Ronchi, A.; Marandino, F.; Rossi, E. D.; Caristo, M. E.; Malandrino, P.; Russo, M.; Pontecorvi, A. and Vigneri, R. : Intake of Boron, Cadmium, and Molybdenum enhances rat thyroid cell transformation. *Journal of Experimental & Clinical Cancer Research.* (2017); 36(1): 1-9.

26. Teng, Y.; Ren, C.; Chen, X.; Shen, Y.; Zhang, Z.; Chai, L. and Wang, H. : Effects of cadmium exposure on thyroid gland and endochondral ossification in *Rana zhenhaiensis*. *Environmental Toxicology and Pharmacology*.(2022); 92: 103860.
27. Benvenga, S.; Marini, H. R.; Micali, A.; Freni, J.; Pallio, G.; Irrera, N.; Squadrito, F.; Altavilla, D.; Antonelli, A. and Ferrari, S. M. (2020): Protective effects of myo-inositol and selenium on cadmium-induced thyroid toxicity in mice. *Nutrients*; 12(5): 1-16.
on blood and the thyroid gland and pharmacological intervention by vitamin C in rabbits. *Environmental Science and Pollution Research*.(2019); 26(16): 16727-16741.
28. Velickov, A.; Jancic, N.; Dinidic, N.; Rancic, I.; Bojanic, N. and Krstic, M.: Histological and histochemical characteristics of rat myocardium Cd toxicosis. *Acta Medica Medianae*.(2013); 52 (2): 15-22.
29. Jancic, S. A. and Stosic, B. Z. : Cadmium effects on the thyroid gland. *Vitamins & hormones*. (2014); 94: 391-425.
30. Midorikawa, K.; Murata, M.; Oikawa, S.; Hiraku, Y. and Kawanishi, S.: Protective Effect of Phytic Acid on Oxidative DNA Damage with Reference to Cancer Chemoprevention. *Biochemical and Biophysical Research Communications*. (2001); 288: 552–557.
31. Mahmood, T.; Qureshi, I. Z.; Iqabi, M. J. : Histopathological and biochemical changes in rat thyroid following acute exposure to hexavalent chromium. *Histology and Histopathology*. (2010); 25: 1355-70.
32. Iranshahi, M.; Rezaee, R.; Parhiz, H.; Roohbakhsh, A. and Soltani, F.: Protective effects of flavonoids against microbes and toxins: the cases of hesperidin and hesperetin. *Life Science*. (2015); 137:125-132.
33. Khan, R.; Ali, S.; Mumtaz, S.; Andleeb, S.; Ulhaq, M.; Tahir, H. M.; Khan, M. K. A.; Khan, M. A. and Shakir, H. A. : Toxicological effects of toxic metals (cadmium and mercury)
34. Donmez, H.H.; Donmez, N.; Kisadere, I. and Undag, I. : Protective effect of quercetin on some hematological parameters in rats exposed to cadmium. *Biotechnic & Histochemistry*.(2019); 94(5): 381-386.
35. Abu -El-Saad, A. S. and Mahmoud, H. M.: Phytic acid exposure alters aflatoxin B1-induced reproductive and oxidative toxicity in albino rats (*Rattus norvegicus*). *Evidence-Based Complementary and Alternative Medicine*. (2009); 6(3): 331-341.
36. Alkhalaf, M. I.; Alansari, W. S.; Alshubaily, F. A.; Alnajeebi, A. M.; Eskandrani, A. A.; Tashkandi M. A. and Babteen N. A. : Chemoprotective effects of inositol hexaphosphate against cyclophosphamide-induced testicular damage in rats. *Scientific Reports*.(2020); 10 (1):1-13.
37. Daley, T.; Omoregie, S. N.; Wright, V. and Omoruyi, F. O. : Effects of phytic acid and exercise on some serum analytes in rats orally exposed to diets supplemented with cadmium. *Biological Trace Element Research*. (2013); 151(3): 400-405.

To cite this article: Gehad A. Abdullah, Maysara A. Salem, Sherifa A. Morsy, Ola M. Mohamed. Protective Effects of Quercetin and Phytic Acid (Myo Inositol) on Cadmium Toxicity in Thyroid Gland of Adult Male Albino Rats. *BMFJ* 2023;40(academic):94-106.