

# Role of Ultrasound in Detecting Developmental Hip Dysplasia in Neonates at Risk

Hisham E. Elshikh, Ahmed M. Shallan, Riyadh M. Kadhim

Department of radiology,  
Benha faculty of medicine,  
Benha University, Egypt.

**Correspondence to:** Riyadh M. Kadhim Department of radiology, Benha faculty of medicine, Benha University, Egypt.

**Email:**

riyadhmohammed43@gmail.com

**Received:** 1 November 2022

**Accepted:** 22 January 2023

**Abstract**

**Background:** Developmental dysplasia of the hip (DDH) is a musculoskeletal condition occupying any point along a spectrum of anatomical abnormalities that alter the stability of the newborn hip. Ultrasonography is the most reliable imaging method for the diagnosis of DDH before femoral head epiphyseal nucleus ossification. The study aimed to assess the capability of ultrasound in detecting the developmental dysplasia of hip in high risk neonate. **Methods:** This was prospective studies that included 50 babies who were at risk of developing DDH and were candidates to USG imaging. The study was conducted at Central teaching pediatric hospital in Baghdad /Iraq and the radiology departments of Benha University, Egypt. **Results:** According to diagnosis of DDH by USG 9 (18%) of babies were diagnosed to have a degree of DDH while 41 (82%) were normal according to USG findings. According to Graf's classification, 41 (82%) babies were type I (normal) and 8 (16%) babies were Type II graf (immature or abnormal) and only one baby (2%) was Graf Type III . According Validity of USG in Diagnosis of DDH, sensitivity was 100%, Specificity 89.13% and Accuracy of USG in diagnosis DDH was 89.24%. **Conclusion:** USG is an accurate and effective tool for routine screening for early diagnosis DDH in high risk neonates with or without presence of risk factors alone. Patient characteristics that were found to be significant risk factors were breech delivery and positive family history.

**Key words:** Ultrasound - Developmental Hip Dysplasia - DDH - Neonates - At Risk

from mild acetabular dysplasia to total, irreducible dislocation. DDH may also

**Introduction:**

Developmental dysplasia of the hip (DDH) is a musculoskeletal condition occupying any point along a spectrum of anatomical abnormalities that alter the stability of the newborn hip. Clinical instability may range

manifest without clinical instability as solely radiological abnormalities. The etiology is multifactorial, with the strongest risk factors being the breech position, female sex, family history, and primiparity.

Cases may present anywhere from birth to late infancy.

Approximately 60-80% of hips in newborns that are clinically suspicious and 90% of those suspicious on ultrasound resolve spontaneously without intervention. (1)

Undiagnosed DDH result in shortening of the affected limb which affects the child's gaits decreased strength and increased risk of degenerative joint diseases in hip and knee joints. Effective treatment of DDH with early noninvasive methods is possible only in early infancy (2).

Hip ultrasonography provides an early diagnostic tool for DDH with lower risk of missing DDH diagnosis less than 0.1%. Ultrasonography can provide detailed imaging of the hip before femoral head

ossification by visualizing both the bony and cartilaginous parts of newborn hip joints and the coverage of the femoral head by the cartilaginous acetabulum. Hip ultrasonography has become the most commonly used diagnostic tool for DDH during early infancy and for many years. (3)

Using USG in the detection of abnormal hip findings was showing the more accurate mean of revealing findings than physical examination with or without presence of risk factors alone.

Although, most newborn screening studies suggest that some degree of hip instability can be detected in one in 100 to one in 250 babies, actual dislocated or dislocatable hips are much less frequent being founded in 1 - 1.5 of 1000 live births. Unlike the clinical examination signs which was conducted in this study; using Graf's criteria of

ultrasonography to assess hip dislocation or instability was showing minimal anatomic abnormalities detected early, most of which will not affect the later development of the hip which will go on to become normal. (4)

The study aimed to assess the capability of ultrasound in detecting the developmental dysplasia of hip in high risk neonate.

## **Patients and Methods**

### **Patients:**

This is prospective studies that included 50 babies who were at risk of developing DDH and were candidates to USG imaging. The study was conducted at Central teaching pediatric hospital in Baghdad /Iraq and the radiology departments of Benha University, Egypt. The study period was from April 2021 till May 2022.

• Approval of the Scientific Research Ethics Committee October 2021

### **Neonates at risk of developing DDH e.g.:-**

Family history of DDH , abnormal clinical examination of the hip , breach presentation , twin pregnancy , oligohydramineas , caesarian section , foot deformities ., and other anomalies .

### ***Inclusion criteria:***

Neonate at risk of developmental dysplasia of the hip who underwent sonographic examination after their parent approved to participate in the study.

**Exclusion criteria:**

Neonate without risk of development dysplasia of the hip or those who their parents refused to participate in the study,

**Site of the study:**

- Central teaching pediatric hospital in Baghdad /Iraq
- Radiology department - Benha university /Egypt

**Methods:**

All studied cases were subjected to the following:

**Clinical assessment:** was performed by colleges in pediatrics and orthopedics outpatient clinics

**1. Detailed history taking, including:**

**A- Perinatal history including:**

**Maternal disease and Oligohydramnios.**

**B- Natal history:**

- Type and site of delivery.
- If delivery is complicated or not).
- Breech presentation.
- Large baby.
- Twins.

**B- Postnatal history:**

Crying, cyanosis, jaundice, resuscitative measures.

**D- Family history** of hip developmental dysplasia.

**E- Parents complains:**

- Limb shortening.
- Limitation of hip movement (abduction).
- A symmetrical skin folds.
- Shortened thigh at one side.
- Other congenital anomalies as (foot deformity, torticollis, spina bifida with meningocele).

**2. Full clinical examination, including:**

**A-General examination including:**

Vital sign, and anthropometric measurements (Weight, height, & head circumference).

**B-Systemic examination** to exclude congenital anomalies,

1. **Cardiovascular System:** For detection of any abnormal heart sounds or murmurs.
2. **Chest examination:** Decrease air entry and signs of respiratory distress
3. **Gastrointestinal Tract (GIT) and Abdomen:** Presence of organomegaly or ascites.

4. **Central Nervous System (CNS) and Musculoskeletal System** Assessment of Glasgow coma score, pupillary reaction, examination of motor system including power, tone and reflexes.

**C-Local examination of the hip joint:** a pediatrician or pediatric orthopedic surgeon to detect signs of developmental dysplasia of the hip as:

- Limited abduction <70 degrees.
- Loss of normal mild hip/knee flexion.
- External signs as swelling or deformity, detection of areas of tenderness.

#### **Radiological assessment:**

##### **Technique: of hip ultrasonography**

Ultrasound examination was done for about one hundred leg of 50 baby by well-trained pediatric radiologist using good ultrasound machine by using linear probe of 7.5 MHZ frequency .positioned the neonate by keeping on lateral decubitus position using child support pads ( if available ) to ensure good coronal & transverse view then asses beta & alpha angle & femoral head coverage percentage by acetabulum (Graf's methods ). Dynamic & stress view was done to asses instability.

The hip screening protocol was ultrasound-based and considered the results of a manual test and DDH risk factors. Newborns with a Graf's type Ia or Ib who did not screen positive by physical exam or have other risk factors were classified as negative and were deemed not at risk for developing DDH. However, if newborns had a negative Graf classification (Ia, Ib) and a positive physical examination or a risk factor, they were categorized as an intermediate case and were followed up after one month to monitor progression. Manual tests used included the Barlow test, the Ortolani test, and limited abduction of the hip, the Galeazzi sign, and the Allis sign. Risk factors included a family history of DDH, [breech presentation](#), [oligohydramnios](#), and any postural deformities of the neck or lower extremities.

Newborns with a Graf's type IIa hip were immature and flagged for follow-up one month later, while cases with Graf's type IIc, III, IV and D hips had more severe dysplasia and were transferred to a pediatric orthopedic specialist. After the initial screening, the patients were asked to return for reexamination if deemed necessary. Upon reexamination, some cases were still found to be positive or inconclusive due to risk factors or results of a physical examination (Table 1).

**Table 1:** Graf’s classification

Types	Definition
<b>Type I</b>	Is a mature hip with $\alpha$ angle $>60^\circ$ . It is divided into two subgroups: type 1a, with $\beta$ angle $>55^\circ$ ; and type 1b with $\beta$ angle $<55^\circ$ .
<b>Type IIa</b>	Is the physiologic immature hip in which $\alpha$ is between $50^\circ$ and $59^\circ$ in an infant younger than 12 weeks of age. If type 2a morphology persists beyond 12 weeks, it is termed as type 2b (acetabular dysplasia) where $\alpha$ is between $50^\circ$ and $59^\circ$ .
<b>Type IIc</b>	Is a hip in the critical range $\alpha = 43^\circ - 49^\circ$ . It is divided into two subgroups: Type 2c stable and Type 2c unstable. In the Type D hip, the $\alpha$ angle is in the same range as in the Type 2c hip; however, the Type D is decentered and has a $\beta$ angle $>77^\circ$ .
<b>Type III</b>	Hips are both decentered hips, with $\alpha <43^\circ$ and $\beta >77^\circ$ in each. Determination of the position of the cartilaginous roof is crucial for the differentiation of Type 3 and 4, & which is pushed cranially in Type 3 hips, and caudally in Type 4 hips.
<b>Type IV</b>	Type 3 hip is further divided into two subgroups according to the echogenicity of the cartilaginous roof. In Type 3a hips, the roof is hypoechoic, whereas, in the Type 3b hip, the hyaline cartilage is deformed, and appears hyperechoic.

**Final Diagnosis**

These cases were followed-up at up to additional screenings, clinical examination and further investigations for final diagnosis as was required on a case-by-case basis. Patients that were deemed positive or intermediate upon their last visit which at least after one month from the first USG evaluation.

**Ethical consideration:**

- An informed consent was obtained from parents before enrollment in the study.
- An approval from Research Ethics Committee in Benha Faculty of Medicine was obtained.

**Statistical analysis:**

The collected data was presented in tables and suitable graphs and analyzed by (SPSS). Quantitative variables were expressed as mean  $\pm$  SD, and range. Qualitative variables are expressed as frequency and percentage. The level of significance is  $p < 0.05$ .

**Results:**

According to Risk factors of DDH, 11 (22%) baby were with positive family history 3 (6%) Associated congenital anomalies, 36 (72%) were female gender, 5 (10%) maternal DM, 12 (24%) oligohydramnios, 43 (86%), Cesarean section, 6 (12%) were twin, 4 (8%) prematurity and 4 (8%) were breech presentation **Table (2).**

According to mean value of alpha and beta angles in both sides, alpha angle was  $58.42^{\circ} \pm 7.57$  at Right hip and was  $56.08^{\circ} \pm 9.11$  at Left hip while Beta angle was  $59.32^{\circ} \pm 8.76$  at Right hip and was  $61.04^{\circ} \pm 7.54$  at left hip **Table (3)**.

According to diagnosis of DDH by USG 9 (18%) pf babies was diagnosed to have a degree of DDH while 41 (82%) were normal according to USG findings As reported at last visit (after at minimum one month from the first evaluation) 4 (8%) were confirmed to have DDH and 46 (92%) babies were normal **Table (4)**.

According to Graf's classification, 41 (82%) baby was type I (normal) and 8 (16%) baby was Type II graf (immature or abnormal) and only one baby (2%) was Graf Type III . Sonographic Hip Type According to Graf's classification is showed at details in **Table (5)**.

According Validity of USG in Diagnosis of DDH, Sensitivity was 100%, Specificity 89.13% and Accuracy of USG in diagnosis DDH was 89.24% **Table (6)**.

**Table (2): Risk factors**

<b>Risk factors</b>	Positive family history	11 (22%)
	Associated congenital anomalies	3 (6%)
	Female gender	36 (72%)
	Maternal DM	5 (10%)
	Oligohydramnios	12 (24%)
	Cesarean section	43 (86%)
	Twin	6 (12%)
	Prematurity	4 (8%)
	Breech presentation	4 (8%)
<b>Total</b>		25 (100%)

**Table (3): Mean value of alpha and beta angles in both sides**

Alpha angle	Right hip Mean $\pm$ SD	$58.42^{\circ} \pm 7.57$
	Left hip Mean $\pm$ SD	$56.08^{\circ} \pm 9.11$
Beta angle	Right hip Mean $\pm$ SD	$59.32^{\circ} \pm 8.76$
	Left hip Mean $\pm$ SD	$61.04^{\circ} \pm 7.54$

**Table 4 . Diagnosis of DDH by USG and Final diagnosis of DDH**

	<b>Positive</b>	<b>Negative</b>
Presence of DDH according to USG	9 (18%)	41 (82%)
Presence of DDH	4 (8%)	46 (92%)

**Table 5:** Analysis of Sonographic findings, according to Graf’s classification

Sonographic Hip Type	Results N = 50	Percentage
<b>I (normal)</b>	41	82%
<b>IIa/IIa+ (immature)</b>	2	4%
<b>IIa2 (immature)</b>	4	8%
<b>IIb (abnormal)</b>	1	2%
<b>IIc (abnormal)</b>	1	2%
<b>D (abnormal)</b>	0	0%
<b>III (abnormal)</b>	1	2%
<b>IV (abnormal)</b>	0	0%

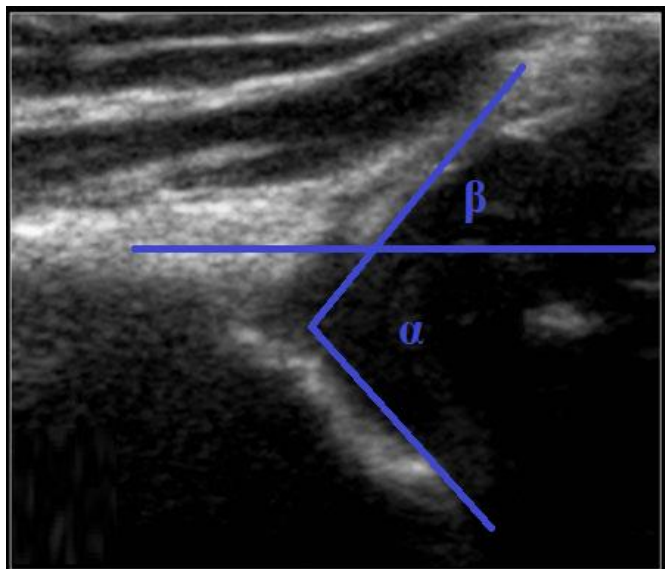
**Table 6:** Validity of USG in Diagnosis of DDH

<b>Validity of USG in Diagnosis of DDH</b>	<b>False Positive</b>	5
	<b>False Negative</b>	0
	<b>True Positive</b>	4
	<b>True Negative</b>	41
	<b>Positive Likelihood Ratio</b>	9.2
	<b>Negative Likelihood Ratio</b>	0
	<b>Sensitivity</b>	100%
	<b>Specificity</b>	89.13%
	<b>Accuracy</b>	89.24%

## Case Presentation

### Case 1

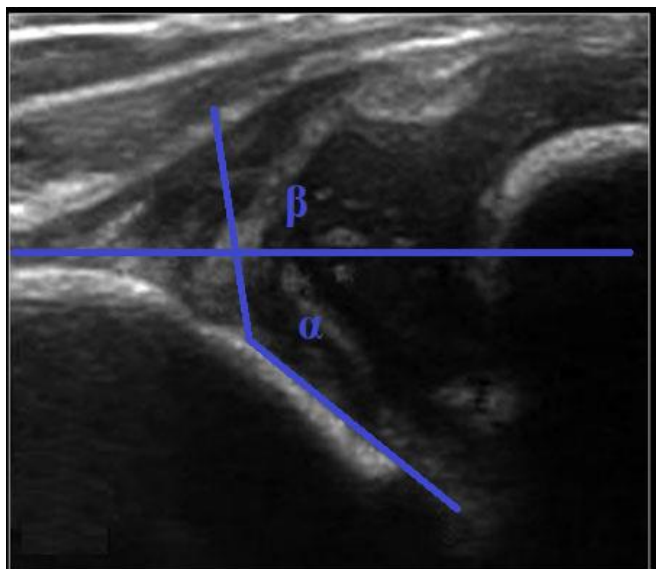
- Female baby aged 3 months. USG of Rt hip was showed as following (**fig 1**):
- B angle = 69°
- $\alpha$  angle = 47°
- Graft type IIc



**Fig 1:**

**Case 2**

- Female baby aged 2.5 months. USG of Lt hip was showed as following (**fig 2**):
- B angle =  $101^\circ$
- $\alpha$  angle =  $39^\circ$
- Graft type III

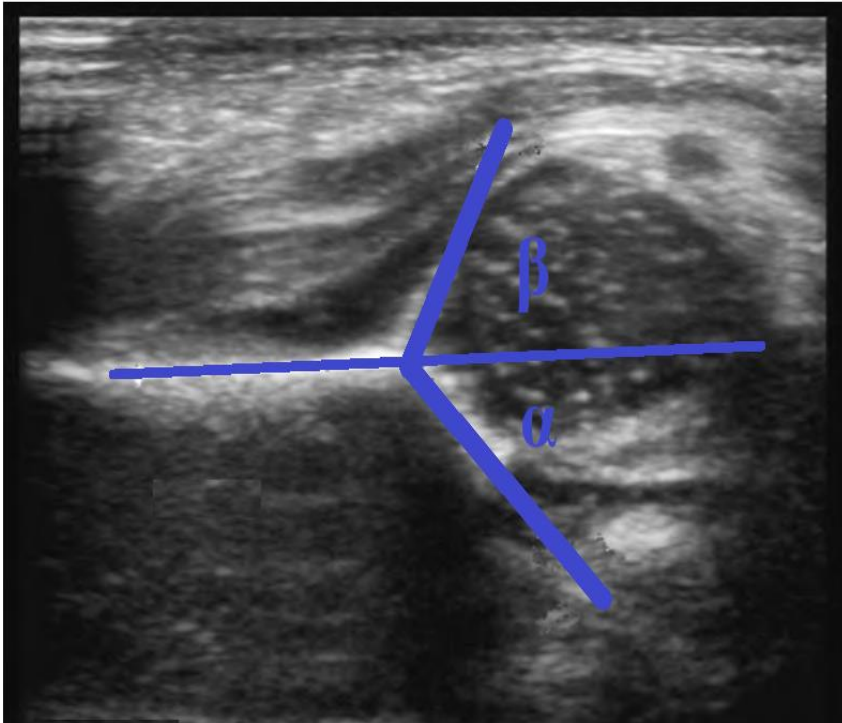


**Fig 2:**



### Case 3

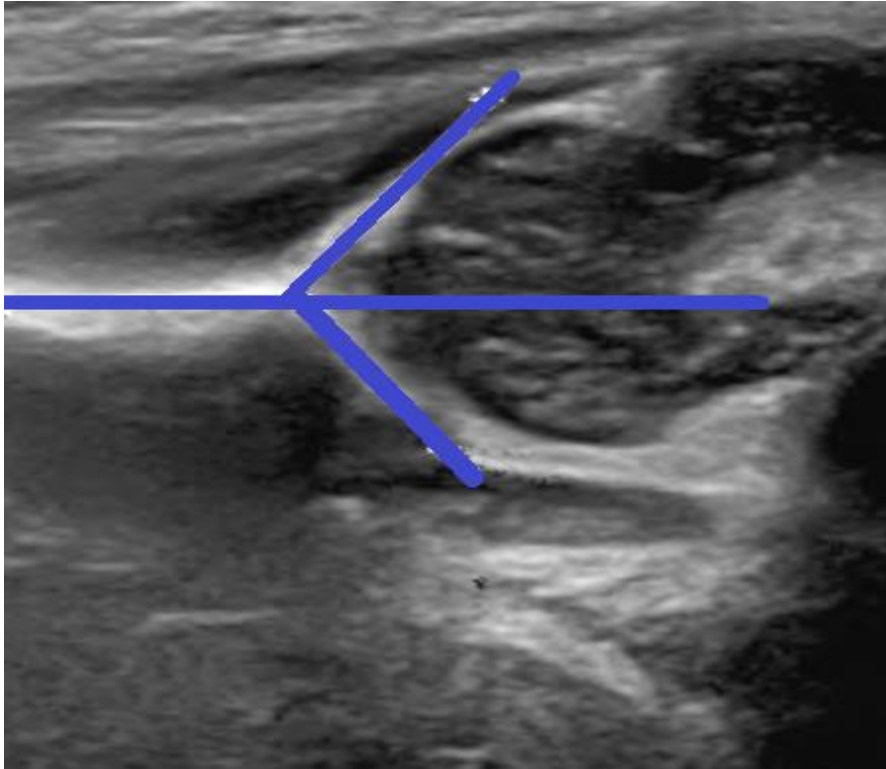
- Female baby aged 2.5 months. USG of Rt hip was showed as following (**fig 3**):
- B angle =  $68^{\circ}$
- $\alpha$  angle =  $57^{\circ}$
- Graft type IIa



**Fig 3:**

### Case 4


- Male baby aged 1.5 months. USG of Lt hip was showed as following (**fig 4**):
- B angle =  $56^{\circ}$
- $\alpha$  angle =  $51^{\circ}$
- Graft type IIb



**Fig 4:**

**Case 5**

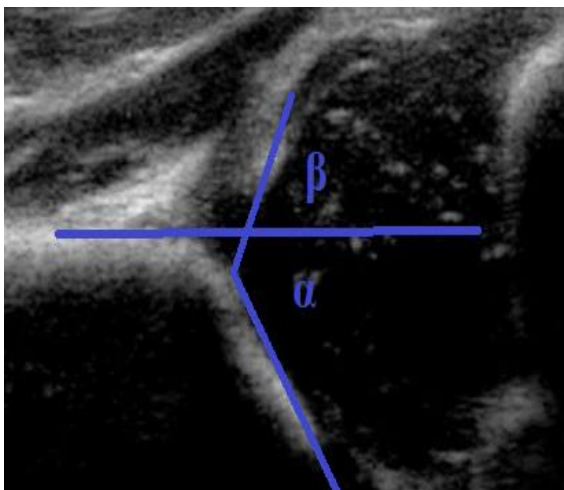
- Female baby aged 2 months. USG of Rt hip was showed as following (**fig 5**):
- B angle =  $54^{\circ}$
- $\alpha$  angle =  $61^{\circ}$
- Graft type Ia



**Fig 5:**

**Case 6**

- Male baby aged 3.5 months. USG of Rt hip was showed as following (**fig 6**):
- B angle =  $71^\circ$
- $\alpha$  angle =  $59^\circ$
- Graft type IIa



**Fig 6.**

## Discussion

According to Risk factors of DDH, 11 (22%) baby were with Positive family history. 3 (6%) Associated congenital anomalies, 36 (72%) were Female gender, 5 (10%). Maternal DM, 12 (24%) Oligohydramnios, 43 (86%), Cesarean section, 6 (12%) were Twin, 4 (8%) Prematurity and 4 (8%) were Breech presentation.

According to Mean value of alpha and beta angles in both sides Alpha angle was  $58.42^{\circ} \pm 7.57$  at Right hip and was  $56.08^{\circ} \pm 9.11$  at Left hip while Beta angle was  $59.32^{\circ} \pm 8.76$  at Right hip and was  $61.04^{\circ} \pm 7.54$  at Left hip.

According to diagnosis of DDH by USG 9 (18%) pf babies was diagnosed to have a degree of DDH while 41 (82%) were normal according to USG findings.

According to Graf's classification, 41 (82%) baby was type I (normal) and 8 (16%) baby was Type II Graf (immature or abnormal) and only one baby (2%) was Graf Type III .

As reported at last visit (after at minimum one month from the first evaluation) 4 (8%) were confirmed to have DDH and 46 (92%) babies were normal

According to correlation between incidence of DDH and risk factors, the was a statistically significant correlation between ( Family history and Breech presentation ) and development of DDH and no statistically significant correlation was found between development of DDH and (age, sex,

Maternal DM, Oligohydramnios or Associated anomalies).

According Validity of USG in Diagnosis of DDH, Sensitivity was 100%, Specificity 89.13% and Accuracy of USG in diagnosis DDH was 89.24%.

While Prematurity, oligohydramnios and a positive family history were observed to be significant risk factors for developmental dysplasia of the hip in another study <sup>(5)</sup>.

Prematurity has been associated with a decreased risk of DDH. Higher birth weight have been identified, increased birth weight likely lead to constrictive conditions in utero, causing abnormal hip positioning. Oligohydramnios is associated with a fourfold increase in DDH risk, likely due to similar mechanisms <sup>(6)</sup>

First-degree relatives have 12 times higher risk over patients without family history [28], positive family history increases the risk of DDH. A positive family history of DDH has each been consistently shown to increase an infant's risk of DDH. Other risk factors for DDH reported include primiparity, oligohydramnios, post maturity and high birth weight <sup>(7)</sup>

Another study reported that prevalence of the different risk factors among their studied group was (13.7%) for Oligohydramnios, (52.2%) for Caesarean section delivery, (6%) for Clinical suspicion, (14.4%) for breech presentation, (6%) for Twins, (2%) for 1st born/CS (combined risk factors) and (6%) for positive family history <sup>(8)</sup>.

According to a study by another study <sup>(9)</sup>, **the** most frequent risk factor was identified as being a firstborn girl, followed by breech presentation, multiple pregnancy, and oligohydramnios. Breech presentation, oligohydramnios, female sex, and primiparity were determined to be risk factors for DDH in the study of group of researchers <sup>(10)</sup>. The meta-analysis of another study <sup>(11)</sup> indicated that breech presentation, female sex, positive family history, and clicking hips at physical examination were the most potent risk factors for DDH.

The present study showed that the most common risk factor was cesarean section this was in agreement with another study <sup>[12]</sup> found that children born by caesarean section are more likely to have associated instability and dislocations and another study <sup>[8]</sup> who reported that the most prevalent risk factor in our group was Caesarean section delivery ( 52.2%), but in disagreement with another study <sup>[13]</sup> who reported that the most frequent risk factor was family history followed by oligohydramnios.

The present study showed higher prevalence of cases with DDH as we target the high risk infants, this in parallel with another study <sup>[14]</sup> which reported that screening of all newborns with ultrasonography led to a high rate of reexaminations and ultrasound screening should not be performed before 3-4 week of age in infants with clinical signs or risk factors for DDH because of the normal physiologic laxity that resolves spontaneously by 6 week of age.

Another study reported that hip ultrasonography is currently the most accurate diagnostic tool in developmental DDH during early infancy. Besides, either the universal or the selective ultrasonographic newborn hip screening programs have notably decreased the rate of late detected and surgically treated DDH cases <sup>(3)</sup>.

Another study recommended that ultrasound screening of DDH should be done for all high risk infants; they said that it is better to do examination after 4-6 weeks as before that will often reveal minor degrees of dysplasia that resolve spontaneously and do not need treatment <sup>(8)</sup>. Group of researchers reported that all infants may be examined but selective screening with imaging should be performed for abnormal physical exams or high risk infants <sup>(15)</sup>.

In another study <sup>(16)</sup>, in total, we screened 1683 newborns in 2016. Of the initial cases screened within 28 days (n = 1168), 86.6% were negative, 10.1% positive, and 3.3% intermediate, while of the cases screened after 28 days (n = 515), 97.3% were negative, 0.8% positive, and 1.9% intermediate. Screening of the newborns' final hip outcomes revealed that 1641 (97.6%) were negative, treatment was administered in 8 cases (0.4%), and 34 (2.0%) cases were lost to follow-up. When comparing screening times, screening after 28 days improved specificity (89%–97%), and later screenings were associated with fewer visits needed to confirm hip outcomes (a OR = 0.19, CI95% = 0.10–0.38, p < 0.001) and improved accuracy (a

OR = 13.84, CI95% = 4.23–45.26, p < 0.001).

In another study <sup>(17)</sup> a total of 3,541 infants underwent clinical examination and hip ultrasonography. Measured against ultrasonography as a standard, the sensitivity and specificity of clinical examination were 97% and 13.68%, respectively. Graf type IIb or more severe developmental dysplasia was found in 167 infants (208 hips), at an overall frequency of 4.71%. Graf type IIa physiological immaturity was encountered in 838 hips, and of these, 15 hips (1.78%) developed Graf type IIb dysplasia and underwent treatment. Patient characteristics that were found to be significant risk factors were swaddling use, female gender, breech delivery and positive family history. Given its low specificity their findings suggest that clinical examination does not reliably detect ultrasonographically defined developmental dysplasia of the hip in infants being screened for this disease.

Delays in diagnosis and treatment resulting in sequelae increase the cost of treatment. Furthermore, total hip arthroplasty may be necessary owing to the development of coxarthrosis. This condition prolongs the treatment process and leads to serious labor force loss. In cases of early diagnosis and conservative treatment, the necessity of surgical treatment can be reduced. <sup>(5)</sup>

Therefore, hip ultrasonography has been included in the screening program and adopted as a health policy in various countries. In our country, within the national early diagnosis and treatment program for DDH, it is aimed to perform a routine hip

examination during the newborn period, identify high risk and clinically suspected groups and to initiate early and appropriate treatment <sup>(18)</sup>.

### Conclusion:

USG is an accurate and effective tool for routine screening for early diagnosis DDH in high risk neonates with or without presence of risk factors alone. Patient characteristics that were found to be significant risk factors were breech delivery and positive family history.

### References:

1. **Yu RX, Gunaseelan L, Malik AS, Arulchelvan A, Yue E, Siddiqua A, et al.** Utility of Clinical and Ultrasonographic Hip Screening in Neonates for Developmental Dysplasia of the Hip. *Cureus*. 2021 Oct 5;13(10):e18516.
2. **OKOŃSKI M., JAKUBOWSKI P., MATUSZEWSKI L., PIETRZYK D. and KANDZIERSKI G.:** Developmental dysplasia of the hip in newborns - a still relevant problem. *Chir. Narzadow. Ruchu. Ortop. Pol.*, 2018; 83 (1): 15-8.
3. **OMEROGLU H.** Use of ultrasonography in developmental dysplasia of the hip. *J. Child Orthop.* 2014; 8: 105-13,.
4. **Ali, A. Al-Zahrani, J. , Elsayed, A. and Serhan, O.** Role of Ultrasound in Evaluation of Developmental Dysplasia of the Hip in Infants. *Open J Pediatr*, 2017; 7, 1-12.
5. **Demir, G. Ü., Sarı, E., Karademir, S.** Ultrasonographic Screening and the Determination of Risk Factors involved in Developmental Dysplasia of the Hip. *J Pediatr Res*, 2020; 7(1), 52-58.
6. **Woodacre T, Ball T, Cox P.** Epidemiology of developmental dysplasia of the hip within the UK: refining the risk factors. *J Child Orthop.* 2016 Dec;10(6):633-642.
7. **LODER R.T. and SKOPELJA E.N.:** The epidemiology and demographics of hip dysplasia. *ISRN Orthop.*, 2011: 238607, 2011.

8. **Loder RT, Skopelja EN.** The epidemiology and demographics of hip dysplasia. *ISRN Orthop.* 2011 Oct 10;2011:238607.
9. **ABDULLAH M.S. and ZYTOON A.S.** Developmental Dysplasia of the Hip: Optimal Ultrasound Screening Strategy Among High Risk Newborns. *IJMI*, 2015; 3 (3): 49-58.
10. **Çakır Çuhacı B, Kibar AE, Çakır HT, Arhan E, Cansu A, Yakut Hİ.** Ultrasonographic examination of developmental dysplasia of the hip in 300 infants. *Turkish J Pediatr Dis* 2009;3:5-9.
11. **Chan A, McCaul KA, Cundy PJ, Haan EA, Byron-Scott R.** Perinatal risk factors for developmental dysplasia of the hip. *Arch Dis Child* 1997;76:94–100.
12. **de Hundt M, Vlemmix F, Bais JMJ.** Risk factors for developmental dysplasia of the hip: a meta-analysis. *Eur J Obstet Gynecol Reprod* 2012;165:8-17.
13. **SUTTON D.** Developmental dysplasia of the hip, *Br J Radiol*, 2003; 7: 1856.
14. **DANTE B., GIUSEPPE A., FRANCESCO A,** Screening for developmental dysplasia of the hip. *Pediatrics* 335 rics: OJAA, e5: 99, 1997
15. **American Institute of Ultrasound in Medicine;** American College of Radiology: AIUM practice guideline for the performance of an ultrasound examination for detection and assessment of developmental dysplasia of the hip. *J. Ultrasound Med.*, 2009; 28: 114-9.
16. **Swarup I, Penny CL, Dodwell ER.** Developmental dysplasia of the hip: an update on diagnosis and management from birth to 6 months. *Curr Opin Pediatr.* 2018 Feb;30(1):84-92.
17. **Lussier EC, Sun YT, Chen HW, Chang TY, Chang CH. (2019).** Ultrasound screening for developmental dysplasia of the hip after 4 weeks increases exam accuracy and decreases follow-up visits. *Pediatrics & Neonatology*, 60(3), 270-277.
18. **Lussier EC, Sun YT, Chen HW, Chang TY, Chang CH.** Ultrasound screening for developmental dysplasia of the hip after 4 weeks increases exam accuracy and decreases follow-up visits. *Pediatr Neonatol.* 2019 Jun;60(3):270-277.

**To cite this article:** Hisham E. Elshikh, Ahmed M. Shallan, Riyadh M. Kadhim. Role of Ultrasound in Detecting Developmental Hip Dysplasia in Neonates at Risk. *BMFJ* 2023; 40 (Radiology):191-205.