

The Possible Protective Role of Oxytocin on Hepatic Ischemia and Reperfusion injury Via Modulation of NADPH Oxidase in Adult Male Rats

Heba M. mohey, Mohamed S. EL Hamady, Abeer A. Shoman, Hala M. Anwer

Department of Physiology,
Benha faculty of medicine,
Benha University, Egypt.

Correspondence to: Heba M. mohey, Department of Physiology, Benha faculty of medicine, Benha University, Egypt.

Email:

hebanwar48@gmail.com

Received: 22 September 2022

Accepted: 26 October 2022

Abstract:

Background: Hepatic ischemia reperfusion injury (HIRI) is considered one of the most common causes of liver damage and dysfunction. Oxytocin (OT), besides its classical functions, exhibits a potent antistress, anti-inflammatory, and antioxidant effects. **Aim:** This study was designed to evaluate the effect of pretreatment with OT on HIRI and to determine its possible protective mechanisms, focusing on the potential role of NADPH oxidase 2 (NOX2). **Methods:** 28 adult Wister albino male rats were divided into 4 groups: group I (control group): received saline and subjected to surgery without ischemic procedure, group II (OT group): received OT and subjected to surgery without ischemic procedure, group III (HIR group): underwent hepatic ischemia reperfusion (HIR) procedure & group IV (HIR+ OT group): received OT and underwent HIR procedure. We assessed the effect of OT on serum liver enzymes, hepatic malondialdehyde (MDA), glutathione (GSH), tumor necrosis factor alfa (TNF α), and NOX2. **Results:** HIR caused significant increase in serum liver enzymes, hepatic MDA, TNF α and NOX2 levels with a significant decrease in GSH level. Administration of OT caused a significant improvement in all previous parameters, these results were supported by histopathological examination. **Conclusion:** OT exerts hepatoprotective effect in HIR-induced liver injury even in part through NOX2.

Key words: HIRI, Oxytocin, NADPH oxidase.

Abbreviations: **HIRI:** Hepatic ischemia reperfusion injury; **OT:** oxytocin; **NOX2:** NADPH oxidase2; **HIR:** Hepatic ischemia reperfusion; **MDA:** malondialdehyde; **GSH:** glutathione; **TNF- α :** Tumor necrosis factor alfa; **AST:** aspartate aminotransferase; **ALT:** alanine aminotransferase.

Introduction:

Hepatic ischemia reperfusion injury (HIRI) is considered as a main cause of liver dysfunction and damage (1). HIRI is commonly seen in hepatic surgery, such as in liver transplantation, hepatectomy, and resuscitation after shock. Also, myocardial ischemia, stroke, and hemorrhagic shock can cause insufficient liver blood flow, resulting in HIRI after reperfusion (2).

Ischemic reperfusion injury (IRI) is a pathophysiological process during which cellular damage in an organ, caused by transient deprivation of blood flow and oxygen, is paradoxically exacerbated after the restoration of blood flow during reperfusion, as there is a concomitant release of oxygen free radicals, cytokines, chemokines and up regulation of adhesion molecules with consequent cellular and organ dysfunction (3).

Oxytocin (OT) is a neuropeptide hormone synthesized in the paraventricular and supraoptic nuclei of the hypothalamus (4). It plays a pivotal role in stimulating contractions of both uterine muscles and the myoepithelial cells of the mammary gland, thus establishing its important role during labor and lactation. Besides its classical

functions, OT exhibits a potent antistress, anti-inflammatory and antioxidant effects (5).

Nicotinamide adenine dinucleotide phosphate (NADPH) oxidase is a membrane-bound enzyme, composed of seven subunits (NOX1-5 and Duox 1-2) that catalyze the formation of ROS, such as superoxide anion (O_2^-) and hydrogen peroxide (H_2O_2) (6). Among the seven NOXs, the main ROS-producing NOXs in the liver are NOX1, NOX2, and NOX4. We have selected NOX2 isoform over the other isoforms as it appears to be the most widely distributed NOX isoform in the liver being expressed in hepatocytes, hepatic stellate cells and Kupffer cells. Researchers have demonstrated that NOX2 occupies the main role in IRI-induced ROS generation than NOX1 and NOX4 (7). All these data suggest that compounds inhibiting or modulating NADPH oxidase may aid in fighting HIRI (8).

The purpose of this current study was to evaluate the possible advantageous effect of OT treatment on HIR induced liver injury and to identify its possible protective mechanisms.

Material and methods:

Animals:

It's a prospective experimental study achieved by using 28 adult male albino rats. They were obtained from Laboratory Animals Farm Unit, Veterinary Medicine, Zagazig University. The experiment was done in department of physiology, Benha University. The rats were fed a standard diet, with free access to food and water. They were placed at room temperature (25° c) with a 12:12-h light/dark cycle. These conditions were continued for 10 days before the experiment for acclimatization. The study period lasted for 7 days from 15 to 21 of May,2022. Experimental rats were under complete healthy conditions. All procedures were approved by ethical committee of Benha faculty of medicine. No rats died throughout the experiment. At the end of the study the rats were incinerated at Benha University Hospital Incinerator.

Chemical used:

OT ampules (Syntocinon): (10 IU/ml) supplied by the Novartis Pharmaceuticals (Switzerland) 10 IU (16.7 micrograms). **Kits for reduced glutathione (GSH) level estimation:** provided by Kamilya Biomedical Company Seattle, U.S.A. (Lot

No: ab65354). **Kits for malondialdehyde (MDA) level estimation:** provided by Abcam biochemicals, Cambridge, UK (Lot No: ab118970). **Kits for tumor necrosis alpha (TNF α) level estimation:** provided by Sigma-Aldrich Co., St Louis, MO, U.S.A. (Lot No: RAB0476). **Kits for (AST/SGOT) estimation:** provided by Randox Laboratories Ltd., Ardmore, Diamond Road, Crumlin, Co. Antrim, United Kingdom (Lot No: BT29 4QY). **Kits for (ALT/SGPT) estimation:** provided by my BioSource for Biotechnology (Lot No: MBS269614). **Kits for NADPH oxidase 2 (NOX2) estimation:** provided by LSBio (Lot No: LS-F39030)

Experimental design:

Male rats were divided into 4 groups, each containing 7 rats:

Group 1: (Control group): Rats received saline and were subjected to sham operation (only laparotomy without IR procedures).

Group 2: (OT): Rats received OT in a dose of (3.6 μ g /100g body weight, S.C) daily for 7 days before being subjected to sham operation (9).

Group 3: (HIR): Rats were subjected to hepatic ischemic procedure for 30 min followed by 2 h reperfusion (10).

Group 4: (HIR+ OT): Rats received OT in a

dose of (3.6µg /100g body weight, S.C) daily for 7 days before the start of ischemic procedure for 30 min followed by 2 h reperfusion (9).

HIR procedure:

The overnight fasted rats were weighed and anesthetized by intraperitoneal (i.p.) injection of sodium pentobarbital (50 mg/kg body weight). Partial hepatic ischemia (70% of liver mass) was induced by clamping the portal vein, hepatic artery, and bile duct (portal triad), which supply the median and left lobes, with an atraumatic vascular clamp. In this way, the blood supply to the right and caudate lobes remained uninterrupted. After 30 min of ischemia, the clamp was removed and reperfusion for 120 min was initiated (11). At the end of the reperfusion period, all rats were anesthetized again and blood samples were obtained through cardiac puncture, then abdomen was opened immediately, median and left lobes were removed for histopathological examination and determination of hepatic MDA, GSH, TNF- α and NOX 2 levels.

Parameters assay:

• **Blood sampling and preparation of serum:**

The blood was left at room temperature until clotting. Serum was separated by

centrifugation at 3000 revolutions per minute (rpm) for 15 min and stored at -20°C for biochemical analysis of alanine transferase (ALT) and aspartate transferase (AST).

• **Tissue sampling and preparation of hepatic homogenate:**

• **The 1st part** was immediately washed with normal saline and stored at -80° C for the preparation of tissue homogenate, about 0.5 g of each liver of the 1st part was homogenized in 4.5 ml of phosphate-buffered saline (PBS, pH 7.0, containing 1 mm EDTA). The crude tissue homogenate was then centrifuged at 8000 rpm for 30 min and the supernatant was collected for the assay of MDA, GSH and TNF- α .

▪ **The 2nd part of the liver** was homogenized in 5-10 ml cold buffer (50 mM potassium phosphate, pH 7.5) per gram tissue. The homogenates were centrifugated for 5 minutes at 5,000 x g. Then the supernatant was removed and stored at -80°c till the assay of NADPH oxidase using ELISA method.

▪ **The 3rd part** was kept in formaldehyde to be stained with Hematoxylin and Eosin for histopathological examination. The

hepatic histopathological injury was scored based on Suzuki score system (12), (13).

Statistical analysis:

The data were analysed using the program: Statistical package for social science (SPSS) version 20 (SPSS Inc., Chicago, IL, USA) to obtain:

Descriptive statistics: were calculated for the data in the form of:

1. Mean.
2. Standard deviation (\pm SD).

Analytical statistics:

In the statistical comparison between the different groups, the significance of difference was tested using one-way analysis of variance (ANOVA) as well as post-hoc multiple comparisons (LSD) were used for the comparison of all study parameters between the groups. Probability of chance (p-value less than 0.05) was considered statistically significant.

RESULTS:

Comparison between different studied groups regarding aspartate transferase (AST) and alanine transferase (ALT) serum levels and hepatic histopathological score (Table 1):

Table 1 Comparison between different studied groups regarding aspartate transferase (AST) and alanine transferase (ALT) serum levels and hepatic histopathological score

	group I (control)	group II (OT)	Group III (HIR group)	Group IV (HIR + OT)
AST (IU/L)	45.37 \pm 6.95	46.94 \pm 7.13	89.24 \pm 12 a, b, d	54.83 \pm 5.73a, b, c
ALT (IU/L)	50.31 \pm 6.34	51.68 \pm 4.31	77.8 \pm 10.8a, b, d	59.30 \pm 2.05a, b, c
Hepatic histopathological Score	0.14 \pm 0.37	0.14 \pm 0.37	5.57 \pm 0.97 a, b, d	1.71 \pm 0.75 a, b, c

Data are represented as Mean \pm SD:

^a significant difference (P < 0.05 from) compared with control group - ^b significant difference (P < 0.05 from) compared with OT group - ^c significant difference (P < 0.05 from) compared with HIR group- ^d significant difference (P < 0.05 from) compared with HIR+OT group.

ALT: Alanine aminotransferase; **AST:** Aspartate aminotransferase; **HIR:** Hepatic ischemia reperfusion; **OT:** Oxytocin

- We can observe that, there was a significant increase ($P < 0.05$) in serum levels of AST /ALT and hepatic histopathological score in **HIR group** when compared with their corresponding in the **Control group**.
- **OT treatment** in a dose of $3.6\mu\text{g} /100\text{g}$ body weight, S.C daily for 7 days resulted in a non-significant increase ($P > 0.05$) in serum levels of AST/ ALT and hepatic histopathological score when compared with their corresponding in the **Control group**.
- OT treated group in a dose of $3.6\mu\text{g} /100\text{g}$ body weight, S.C daily for 7 days before the start of HIR procedure (**OT+HIR group**) resulted in a significant decrease ($P < 0.05$) in serum levels of AST/ ALT and hepatic histopathological score when compared with their corresponding in **HIR group**.

Table 2: Comparison between different studied groups regarding MDA, GSH, $\text{TNF}\alpha$, NOX2 tissue levels

	group I (control)	group II (OT)	Group III (HIR group)	Group IV (HIR + OT)
MDA (nmol/gm tissue)	1.16± 0.09	1.17± 0.12	3.1± 0.45 a, b, d	1.72±0.26 a, b, c
GSH (mg/gm tissue)	40.5± 2.72	40.64± 2.66	16.6± 2.12 a, b, d	38.93± 4.16 c
$\text{TNF}\alpha$ (Pg/gm tissue)	37.7±5.08	38.57±4.72	50.7±4.6 a, b, d	40.85 ±3.13 c
NOX2 (ng/mg protein)	8.22±0.87	8.51±0.94	10.57±0.73 a, b,d	8.79±0.6 c

Data are represented as Mean ± SD:

^a significant difference ($P < 0.05$ from) compared with control group - ^b significant difference ($P < 0.05$ from) compared with OT group - ^c significant difference ($P < 0.05$ from) compared with HIR group- ^d significant difference ($P < 0.05$ from) compared with HIR+OT group.

MDA: malondialdehyde; **GSH:** Glutathione; **$\text{TNF}\alpha$:** tumor necrosis alpha; **NOX2:** NADPH oxidase 2; **HIR:** Hepatic ischemia reperfusion; **OT:** Oxytocin.

- We can observe that, there was a significant increase ($P < 0.05$) in MDA, $TNF\alpha$ and NOX2 tissue levels in **HIR group** when compared with their corresponding in the **Control group**. Regarding tissue GSH level, there was a significant decrease ($p < 0.05$) in GSH tissue level in **HIR group** when compared with its corresponding in the **Control group**.
- **OT treatment** in a dose of $3.6\mu\text{g}/100\text{g}$ body weight, S.C daily for 7 days resulted in a non-significant increase ($P > 0.05$) in MDA, GSH, $TNF\alpha$ and NOX2 tissue levels when compared with their corresponding in the **Control group**.
- OT treated group in a dose of $3.6\mu\text{g}/100\text{g}$ body weight, S.C daily for 7 days before the start of HIR procedure (**OT+HIR group**) resulted in a significant decrease ($P < 0.05$) in MDA, $TNF\alpha$ and NOX2 tissue levels when compared with their corresponding in **HIR group**. Regarding tissue GSH level, there was a significant increase ($P < 0.05$) in GSH tissue level in **HIR+OT group**

when compared with its corresponding in **HIR group**.

Effect of HIR and OT on histopathological changes of the liver: (Figure 1):

In control group (**group I**), liver sections showed a normal histological structure with central vein and radially arranged hepatocytes with patent sinusoids in between (**figure 1-A**). Liver sections of rats received OT alone (**group II**) revealed that liver morphology was similar to that of the control group (**figure 1-B**). In **group III** liver sections of the HIR group showed a wide area of hepatocyte vacuolization, congestion of blood sinusoids in most of the hepatocytes, focal hepatic necrosis, in which several adjacent hepatocytes are lost and replaced by inflammatory cells (**figure 1-C**). Finally, in **group IV**, liver sections of the HIR +OT group showed that OT markedly reduced the hepatocellular changes, as compared with those in the HIR group such as decreased necrosis, decreased inflammatory cell infiltration, decreased vascular congestion, and decreased hepatocytes disruption (**figure 1-D**).

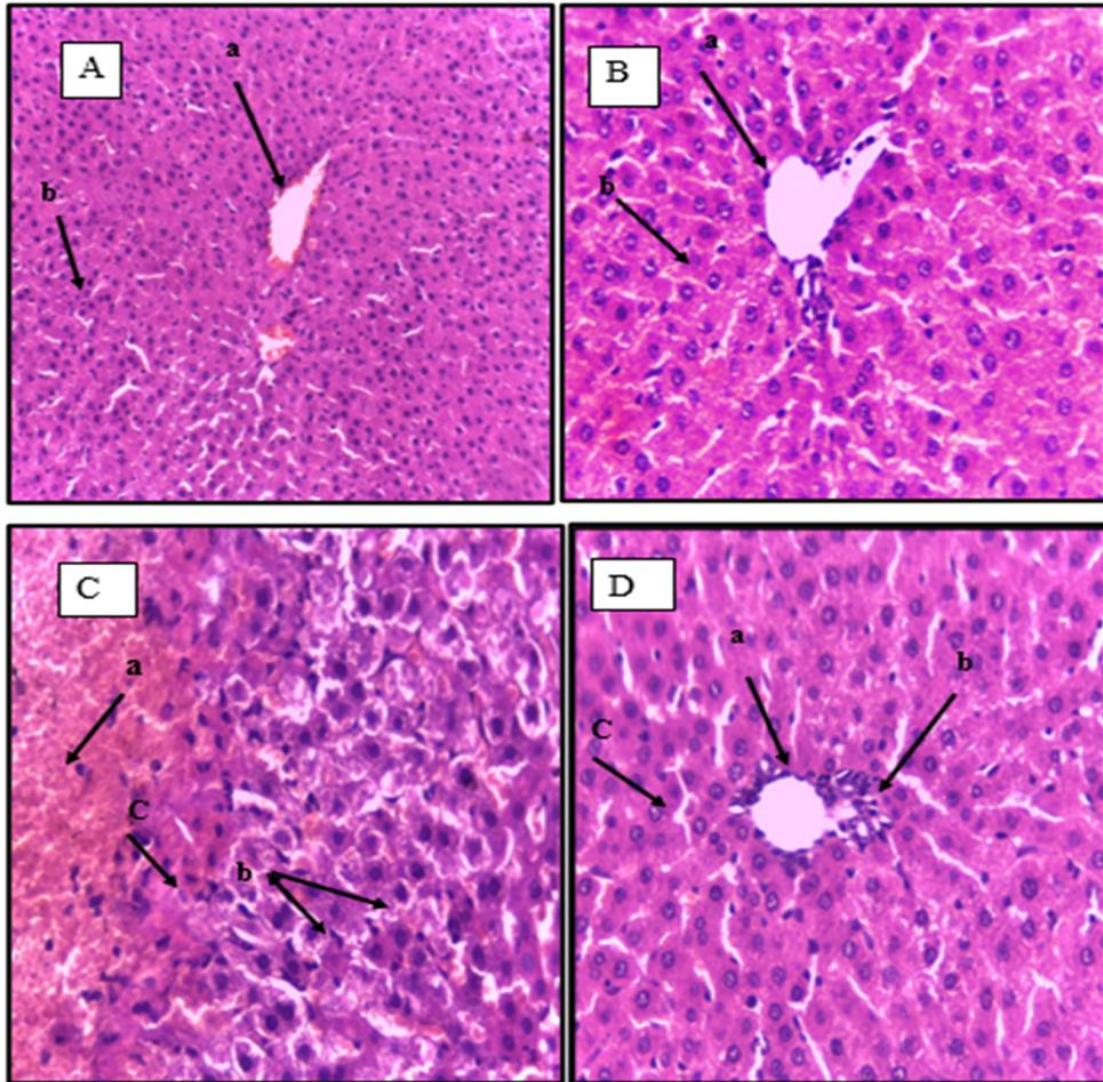


Figure (1): histopathological changes of the liver in studied groups

(A): Control group: showing normal histological structure of hepatic lobule: (a) Central vein, (b) normal hepatocytes (magnification X 200); (B): OT group: showing normal histological structure of hepatic lobule: (a) Central vein, (b) Normal hepatocytes (magnification X 400); (C):HIR: (a) showing focal area of hepatic necrosis, (b) Some hepatocytes show vacuolation of their cytoplasm, (c) inflammatory cells (magnification X 400); (D): HIR+ OT group: showing (a) cv dilated, (b) very slight inflammatory cells, (c) slightly dilated sinusoids (magnification X 400).

Discussion:

In this work, hepatic ischemia was successfully induced by 70% occlusion for 30 min followed by 2 h reperfusion (10). HIR resulted in hepatic injury as proved by significant increase ($p < 0.05$) in level of liver

enzymes AST& ALT in HIR group (group III) when compared with control group (group I). These results agreed with *a previous study (14) that* showed that HIR resulted in disruption of the membrane

stability of hepatocytes due to necrosis, cellular damage, and structural changes with release of large quantities of liver enzymes from the cytoplasm into the blood circulation. Moreover, a histopathological study showed a severe architectural abnormality, coagulation necrosis, and hepatocyte vacuolization and these results agreed with another study (*15*).

The results of the present work showed that the rats exposed to HIR could be attributed to oxidative stress, increased ROS production, associated with decreased antioxidant defense which could be explained by its over consumption to face the increased oxidative stress. This was proved as the rats that were exposed to HIR (group III) had a significantly increased ($p < 0.05$) oxidative stress marker (MDA) and a significantly decreased ($p < 0.05$) antioxidant marker (GSH) in hepatic tissues when compared with control group (group I). These results agreed by another study (*16*) who stated that HIR caused significant increase in hepatic MDA content and decrease in hepatic GSH levels. As many reactive oxygen species (ROS) are produced in liver tissues, which react with lipids to produce a large amount of lipid peroxides (MDA) and reduce the activities of antioxidant enzymes such as

SOD and GSH resulting in an imbalance of tissue oxidation and antioxidant system.

Additionally, we found that rats in group III (exposed to HIR) had a significantly increased ($p < 0.05$) proinflammatory marker (TNF α) in hepatic tissues. These results were also similar to an earlier study (*17*) who suggested that during the reperfusion phase, the activated Kupffer cells released proinflammatory cytokines including TNF- α . However, TNF- α also induces the recruitment of neutrophils into the liver parenchyma.

Other studies demonstrated that IR results in increased ($p < 0.05$) NADPH oxidase 2 (NOX2) in hepatic tissues when compared with control group (group I). We have selected NOX2 over other isoforms for being the most widely distributed isoform. It is expressed in hepatocytes, hepatic stellate cells and Kupffer cells. Researchers have demonstrated that NOX2 occupies the main role in ROS generation during IRI (*18*). These results go along with another study (*19*) who reported that NOX is a family of enzymes involved in the generation ROS and a major factor in the etiology of severe IRI. The explanation could be that activation of NOX2 (e.g., exposure of cells to microorganisms or inflammatory mediators), cytoplasmic subunits, such as

p47phox translocate to the membrane, forming a complex with transmembrane subunit p22phox leading to enzymatic activity, which becomes a new target for antioxidants. With such localization and activation, the NOX2/ROS signaling pathway is initiated.

Interestingly, combined administration of OT by S.C. injection at a dose of 3.6 µg/100 g BW for 7 days, resulted in improvement of hepatic dysfunction which was observed from the significant reduction in the serum levels of ALT and AST, tissue levels of MDA, TNF- α and NOX2 together with significant increase in GSH and alleviated HIR histopathological injury. These results agreed with other studies (9,20) who reported that OT pretreatment to models of HIRI resulted in an improvement of hepatic dysfunction.

Our study proposed some mechanisms by which OT exerted its hepatoprotection. One of the possible mechanisms is mediated through its antioxidant effect. Our work was also in agreement with Ragy and Aziz (21) who proved that OT act as an anti-oxidant, diminishing the toxic oxidative effects of renal IR induced hepatotoxicity through the inhibition of tissue neutrophil accumulation and prevention of lipid peroxidation by scavenging the free oxygen radicals leading

to reduction in MDA and elevation in GSH levels.

The present study suggested another possible mechanism of OT mediated hepatic protection through the improvement of inflammatory processes which accompany HIR. This result was in agreement with Sayyed et.al.,(22) who demonstrated that pretreatment of rats with OT can provide protection against cerebral IRI and this protection was manifested by suppression of cerebral inflammatory cytokine expression (TNF- α , IL-6 and IL-1 β).

We assumed that the beneficial effect of OT against HIRI was mediated, in a part, through decrease NOX2 level and to prove this, hepatic NOX2 level was measured. We found that there was a significant reduction in hepatic NOX2 levels in group IV (OT +HIR group) when compared with those of group III (HIR group).

This result is in agreement with a previous study (23) who reported that OT pretreatment can provide neuroprotection against cerebral IRI and this protection is manifested through the suppression of NOX2.

Previous study reported that reported that IRI was associated with increased NOX2 level while inhibition of NOX2 activity improved oxidative stress and may prevent IRI in fatty

liver. They also found that ROS generation by Kupffer cells (presumably NOX2) plays an important role in HIRI (24).

The present study may provide a novel role of NOX2/ROS signaling, focusing on the relationship between OT and NOX2 in HIRI which maybe a novel target for drug development and treatment. Suppression of NOX derived ROS prevents mitochondrial dysfunction, inflammation, and endoplasmic reticulum (ER) stress leading to attenuation of HIRI.

In the present work, the hepatoprotective role of OT hormone was confirmed by histological examination of hepatic sections. The histological examination showed that OT has attenuated the morphological changes accompanied HIRI. Hepatic sections from rats which pretreated with OT before being subjected to HIR, showed slightly dilated sinusoids, mild localized hemorrhage, and normal appearance of the central vein and hepatocytes which was in accordance with Koroglu et. al.,(25) who reported that OT pretreatment attenuated the histopathological changes associated with HIR.

Conclusion:

From the current study, we can conclude that HIR impaired functional and structural integrity of the liver. Pretreatment with OT showed a protective effect against HIRI. This protective effect could be in part due to the capability of OT to decrease NOX2 level, in addition to its antioxidant and anti-inflammatory effects. Our study may be the first to demonstrate the significant role of NOX2 in the hepatoprotective effect achieved by OT in HIRI rat model.

References:

- 1-Liu, H., Fan, J., Zhang, W., Chen, Q., Zhang, Y., & Wu, Z. OTUD4 alleviates hepatic ischemia-reperfusion injury by suppressing the K63-linked ubiquitination of TRAF6. *Biochemical and Biophysical Research Communications*, (2020) ,523(4), 924-930.
- 2-Schmitz, S. M., Dohmeier, H., Stoppe, C., Alizai, P. H., Schipper, S., Neumann, U. P., et al. Inhaled argon impedes hepatic regeneration after ischemia/reperfusion injury in rats. *International Journal of Molecular Sciences*, (2020), 21(15), 5457.
- 3-Wang, P. P., Huang, X., Yang, M. W., Fang, S. Y., Hong, F. F., & Yang, S. L. Effects of non-drug treatment on liver cells apoptosis during hepatic ischemia-reperfusion injury. *Life Sciences*, (2021) , 275, 119321.

- 4-Donadon, M. F., Martin-Santos, R., and Osório, F. D. L.** The associations between oxytocin and trauma in humans: a systematic review. *Frontiers in pharmacology*, (2018) ,9, 154.
- 5-Buemann, B., & Uvnäs-Moberg, K.** Oxytocin may have a therapeutical potential against cardiovascular disease. Possible pharmaceutical and behavioral approaches. *Medical hypotheses*, (2020) , 138, 109597.
- 6-Mortezaee, K.** Nicotinamide adenine dinucleotide phosphate (NADPH) oxidase (NOX) and liver fibrosis: a review. *Cell Biochemistry and function*, (2018) ,36(6), 292-302.
- 7-Chen, Z., Tian, R., She, Z., Cai, J., & Li, H.** Role of oxidative stress in the pathogenesis of nonalcoholic fatty liver disease. *Free Radical Biology and Medicine*, (2020) , 152, 116-141.
- 8-Vilchis-Landeros, M. M., Matuz-Mares, D., & Vázquez-Meza, H.** Regulation of metabolic processes by hydrogen peroxide generated by NADPH oxidases. *Processes*, (2020) ,8(11), 1424.
- 9-ELKady, A. H., Elkafoury, B. M., Saad, D. A., el-Wahed, A., Doaa, M., Baher, W., & Ahmed, M. A.** Hepatic ischemia reperfusion injury: effect of moderate intensity exercise and oxytocin compared to l-arginine in a rat model. *Egyptian Liver Journal*, (2021) , 11(1), 1-15.
- 10-Shibamoto, T., Kuda, Y., Tanida, M., Wang, M., & Kurata, Y.** Exercise attenuates ischemia-reperfusion injury of nonalcoholic fatty liver in OLETF rat. *Gastroenterol Pancreatol Liver Disord.*, (2015) , 2(2), 1-6.
- 11-Aktaş, H. S., Ozel, Y., Ahmad, S., Pençe, H. H., Ayaz-Adakul, B., Kudas, I., et al.** Protective effects of resveratrol on hepatic ischemia reperfusion injury in streptozotocin-induced diabetic rats. *Molecular and Cellular Biochemistry*, (2019) ,460(1), 217-224
- 12-Saeed, W. K., Jun, D. W., Jang, K., Chae, Y. J., Lee, J. S., & Kang, H. T.** Does necroptosis have a crucial role in hepatic ischemia-reperfusion injury? *PLoS One*, (2017) , 12(9), e0184752.
- 13-Muhammed, M., Mostafa, R., Said, M., Elgndy, A., & Elwakel, H.** Protective Effect of Thymoquinone on Bisphenol A-Induced Hepatotoxicity in Male Rats, Targeting the Role of Associated Pro-Inflammatory Cytokines and NF-κB. *Benha Medical Journal*, (2021) ,38(Academic issue), 61-72.
- 14-Wei, L., Chen, W. Y., Hu, T., Tang, Y. X., Pan, B. B., Jin, M., et al .** Effect and mechanism of propofol in hepatic ischemia/reperfusion injury of rat. *Eur Rev Med Pharmacol Sci*, (2017) , 21(15), 3516-3522
- 15-Lin, J., Huang, H. F., Yang, S. K., Duan, J., Qu, S. M., Yuan, B., et al .** The effect of Ginsenoside Rg1 in hepatic ischemia reperfusion (I/R) injury ameliorates ischemia-reperfusion-induced liver injury by inhibiting apoptosis. *Biomedicine & Pharmacotherapy*, (2020) , 129, 110398.
- 16-Kou, X., Zhu, J., Xie, X., Hao, M., & Zhao, Y.** The protective effect of glycyrrhizin on hepatic ischemia-reperfusion injury in rats and possible related signal pathway. *Iranian Journal of Basic Medical Sciences*, (2020) , 23(9), 1232.
- 17-Du, Y., Qian, B., Gao, L., Tan, P., Chen, H., Wang, A., et al .** Aloin preconditioning attenuates hepatic ischemia/reperfusion injury via inhibiting TLR4/MyD88/NF-κB signal pathway in vivo and in vitro. *Oxidative medicine and cellular longevity*, (2019).
- 18- Hernandez-Resendiz, S., Chinda, K., Ong, S. B., Cabrera-Fuentes, H., & Zazueta, C.** The role of

redox dysregulation in the inflammatory response to acute myocardial ischaemia-reperfusion injury-fuel to the fire. *Current Medicinal Chemistry*, (2018) , 25(11), 1275-1293.

19-Korthuis, R. J. Mechanisms of I/R-induced endothelium-dependent vasodilator dysfunction. *Advances in Pharmacology*(2018) , 81, 331-364.

20-Düşünceli, F., İşeri, S. Ö., Ercan, F., Gedik, N., Yeğen, C., & Yeğen, B. Ç. (2008). Oxytocin alleviates hepatic ischemia–reperfusion injury in rats. *Peptides*, (2018) ,29(7), 1216-1222.

21- Ragy, M. M., & Aziz, N. M. Prevention of renal ischemia/perfusion-induced renal and hepatic injury in adult male Albino rats by oxytocin: Role of nitric oxide. *Journal of Basic and Clinical Physiology and Pharmacology*, (2017), 28(6), 615-621.

22-Sayed, H., Abd Allah, E. S., & Sherif, M. F. Does Oxytocin Have A Neuro-protective Impact in Rats' Stroke Model?. *Bulletin of Egyptian Society for Physiological Sciences*, (2019) , 39(1), 52-62.

adding

23- Moghadam, S. E., Tameh, A. A., Vahidinia, Z., Atlasi, M. A., Bafrani, H. H., & Naderian, H. Neuroprotective effects of oxytocin hormone after an experimental stroke model and the possible role of calpain-1. *Journal of Stroke and Cerebrovascular Diseases*, (2018) , 27(3), 724-732.

24-Kimura, K., Shirabe, K., Yoshizumi, T., Takeishi, K., Itoh, S., Harimoto, N., et al. Ischemia-reperfusion injury in fatty liver is mediated by activated NADPH oxidase 2 in rats. *Transplantation*, (2016) , 100(4), 791-800.

25- Koroglu, P., Bulan, O., BİNGÖL ÖZAKPINAR, Ö. Z. L. E. M., Uras, F., & Arbak, S. The effect of oxytocin treatment on the adult liver of streptozotocin (STZ)-induced diabetic rats. *Fresenius Environmental Bulletin*, (2017) , 26(8).

To cite this article: Heba M. mohey, Mohamed S. EL Hamady, Abeer A. Shoman, Hala M. Anwer. The Possible Protective Role of Oxytocin on Hepatic Ischemia and Reperfusion injury Via Modulation of NADPH Oxidase in Adult Male Rats. *BMFJ* 2023,40(academic issue):35-47.