

# Role of MDCT in Detection of Paranasal Variants and Their Surgical and Clinical Impact

Medhat M. Reffat, Enas M. Sweed, Muntadher L. AbdulSahib

## Abstract:

**Background:** Pneumatization of various bones around the nasal cavity results in the formation of paranasal sinuses. Varying degrees of pneumatization result in multiple variations of paranasal sinuses some of which are important from clinical, pathological and surgical perspective. The aim of the present study was to investigate the role of MDCT in detection of paranasal variants and their surgical and clinical impact. **Methods:** 100 patients with MSCT of the paranasal sinuses were included in this study. Patients having indications of incessant rhinosinusitis hard-headed to restorative treatment and would be candidates for endoscopic sinus surgery were included in this study. **Results:** The mean age of the studied patients was 30 years. There were no significant differences between males and females regarding agger nasi cell, Bulla ethmoidalis (P-value = 1.0), Concha bullosa (P-value = 0.75), crista galli pneumatization, Deviated nasal septum (P-value = 0.208), Frontal sinus agenesis (P-value = 0.62), Frontal sinus hypoplasia (P-value = 0.719), Haller cell (P-value = 1.0), Inferior turbinate pneumatization, Maxillary sinus hypoplasia, Maxillary sinus septation, Onodi cells (P-value = 1.0), Paradoxical middle turbinate (P-value = 0.470), Sphenoid sinus hypoplasia (P-value = 0.497), Sphenoid sinus septation, Superior turbinate pneumatization, Supraorbital cells, and presence of at least one abnormality (P-value = 0.203). **Conclusion:** Inspection of MSCT scans must be performed to identify anatomical variations involving the key area of the osteomeatal complex and frontal recess should be considered before surgical interventions.

**Keywords:** MDCT; paranasal; sinuses; variants

Department of Radio- Diagnosis and Medical Imaging, Faculty of Medicine Benha University, Egypt.

**Corresponding to:** Muntadher Luay AbdulSahib Department of Radio- Diagnosis and Medical Imaging, Faculty of Medicine Benha University, Egypt.

**Email:**  
dr.muntadhar@gmail.com

**Received:** 10 September 2021

**Accepted:** 14 August 2022

---

## Introduction:

Paranasal sinuses (PS) are a group of air-filled spaces developed as an expansion of the nasal cavities, eroding the adjacent bone structures (1). Humans have four pairs of sinuses. The maxillary, ethmoid (divided into anterior and posterior cells) frontal and sphenoid sinuses (2).

According to the literature, some of such regions present a high risk for injuries and consequential intraoperative complications, with the ethmoid and frontal sinuses being most frequently affected (1).

The paranasal sinuses are subject to marked variation between individuals and between sides in the same individual, regarding size (aeration) and bony septations. (3).

The most common Paranasal variants are Agger nasi cells, infraorbital ethmoidal Haller cells, sphenoethmoidal Onodi cells, deviated nasal septum, isolated frontal sinus agenesis, and concha bullosa (3, 4). On the other hand, total paranasal sinus agenesis is very rare (3).

Computed Tomography (CT) plays an important diagnostic role in patients with sino-nasal diseases and determines the treatment. The CT images clearly show fine structural architecture of bony anatomy thereby determining various anatomical variation, extent of disease and characterization of various inflammatory, benign and malignant sino-nasal diseases and associated complications thereby planning the further management of the patient (5).

Computed tomography (CT) has revolutionized the diagnosis and management of many head and neck disorders (6). The CT provides detailed images of the structures scanned. The use of CT scans in endodontic practice could allow for improved treatment planning of surgical procedures by showing the size and location of the lesion in relation to other anatomic structures. The CT scanning has become the standard in medicine for visualizing the maxillary sinuses because of the ability to visualize both bone and soft tissue in multiple views with thin sectioning (7).

Multidetector Computed Tomography (MDCT) are modern and developed generations of CT, and it is the gold standard in the radiologic investigation of the paranasal sinuses, either for diagnosis for sino-nasal lesions or pre- and post-surgical assessment. Its capability in delineating the anatomical variants in

paranasal sinuses protects against iatrogenic injury to essential structures around the paranasal sinuses and recurrent diseases from extramural cells (8).

The purpose of this study is to investigate the role of MDCT in detection of paranasal variants and their surgical and clinical impact.

---

## Patients and methods

This cross-sectional study included 100 Egyptian patients attending Benha University hospital for routine MSCT of the paranasal sinuses from the period of January 2020 till the end of January 2021. The findings were reported by a single radiologist and were analyzed prospectively. The investigators recorded and reported the findings in Excel.

All patients who had indications of incessant rhinosinusitis hard-headed to restorative treatment and will be candidates for endoscopic sinus surgery were included.

All participants signed a written informed consent and filled a written survey including demographic and clinical data. The study was approved by the Ethical Committee of Benha Faculty of medicine.

All enrolled patients were submitted to complete history of symptoms suggestive of chronic rhinosinusitis and findings of ENT examination, MSCT examination of the paranasal sinuses (PNS), and diagnostic endoscopy.

Patients were divided equally into two groups. Patients were diagnosed as rhinosinusitis according to the major criteria of the Task Force on Chronic Rhinosinusitis (9). The symptoms were facial pain, facial pressure, nasal obstruction, hyposmia, or purulent rhinorrhea. The study extended from January 2020 to January 2021.

**Inclusion Criteria:**

Male and female patients having clinical history of rhinosinusitis

**Exclusion Criteria:**

- Presence of general contraindications for CT such as pregnancies
- Uncooperative patients

**Patient protocol: -**

Routine multi-slice CT of the paranasal sinuses was performed to look for mucosal disease of the paranasal sinuses, drainage pathways, and presence of anatomical variations and their relation to known sinus drainage pathways. A review of computed tomography scans of the paranasal sinuses of 100 patients was done; special attention was directed toward identifying bony anatomic variants and mucosal abnormalities.

**MSCT examination****1. Parameters**

After obtaining institutional review board approval, we retrospectively examined images from 192 consecutive unenhanced sinus CT examinations of patients referred because of symptoms of rhinosinusitis.

MDCT was performed using 16-row multi-slice CT scanner (TOSHIBA ingenuity 16-slice CT scanner). Both direct coronal and axial scanning was performed. The coronal scans expanded from the anterior wall of the frontal sinus to the posterior wall of the sphenoid sinus. In the axial scans, the beam was parallel to the hard palate, and the scans extended from the hard palate to the top of the frontal sinus. Slice thickness was 4 mm, and the table incrementation was 3 mm. 130 KV and 150 mA/sec were used. Scan time was 1.5 sec. Window widths were about 1300: 2000 and window levels about -80: -200. Both soft tissue and bone windows were gotten. No intravenous contrast was utilized. A high-resolution calculation

was utilized for upgrade of the fine hard points of interest of the osteomeatal complex.

**2. Image interpretation**

Films were assessed in a schedule, standardized mold to safeguard those little points of interest were not missed utilizing PACS (picture archiving and communicating system). The most things surveyed were as takes after: paranasal sinus groups, drainage pathways, lateral nasal wall, nasal septum and encompassing structures. The nearness of anatomical varieties that either compromised the sinus drainage pathways or not was evaluated.

To evaluate the seriousness of chronic rhinosinusitis, the illness was scored concurring to the criteria of Lund-Mackay score (Bhargava, et al., 2011). Full opacification, semi-opacification, and normal mucosa were scored as 2, 1, and 0, individually. Open osteomeatal complex (OMC) was scored as 0, and as 2 when closed. A few anatomical varieties and their impacts on the seriousness of sinus malady (sinuses with near connection or neighboring the analyzed anatomical variety) were compared measurably (e.g., rate of concha bullosa and the seriousness of maxillary sinus illness).

The anatomical varieties that were surveyed on endoscopy included nasal septal variations (deviation, spur), ethmoidal cell variations (hypertrophied ethmoid bulla, large agger nasi cells obstructing

**Statistical methods**

Data management and statistical analysis were done using SPSS version 25. (IBM, Armonk, New York, United States). Numerical data were summarized as means and standard deviations. Categorical data were summarized as numbers and percentages. Anatomical variations were compared according to

gender, age groups, and mucosal abnormalities in sinuses using the Chi-square or Fisher's exact test. All statistical tests were two-sided. P values less than 0.05 were considered significant

## Results

The mean age of the studied patients was 30 years with a standard deviation of 12

years. Regarding gender, about half of the patients were males (47%), and the other half were females (53%) (Table 1).

Most patients had no symptoms (67%). The most frequent symptom was difficulty breathing (11.0%), while the least frequent was mucosal thickening (1.0%). More than half of the patients (57.0%) had mucosal abnormalities in sinuses (Table 2).

**Table (1)** Demographic characteristics in the studied patients

<i>Demographics</i>		
Age (years)	Mean ±SD	30 ±12
Gender	Males n (%)	47 (47.0)
	Females n (%)	53 (53.0)

**Table (2)** Clinical findings in the studied patients

<i>Clinical findings</i>		
<b>Symptoms &amp; signs</b>	Difficulty Breathing	11 (11.0)
	Facial Pain	8 (8.0)
	Headache	3 (3.0)
	mucosal thickening	1 (1.0)
	polypoidal thickening	2 (2.0)
	Sinusitis	8 (8.0)
	No symptoms	67 (67.0)
<b>Mucosal Abnormalities in Sinuses</b>	Present	57 (57.0)

Data were presented as numbers (percentage)

### Anatomical variations according to gender:

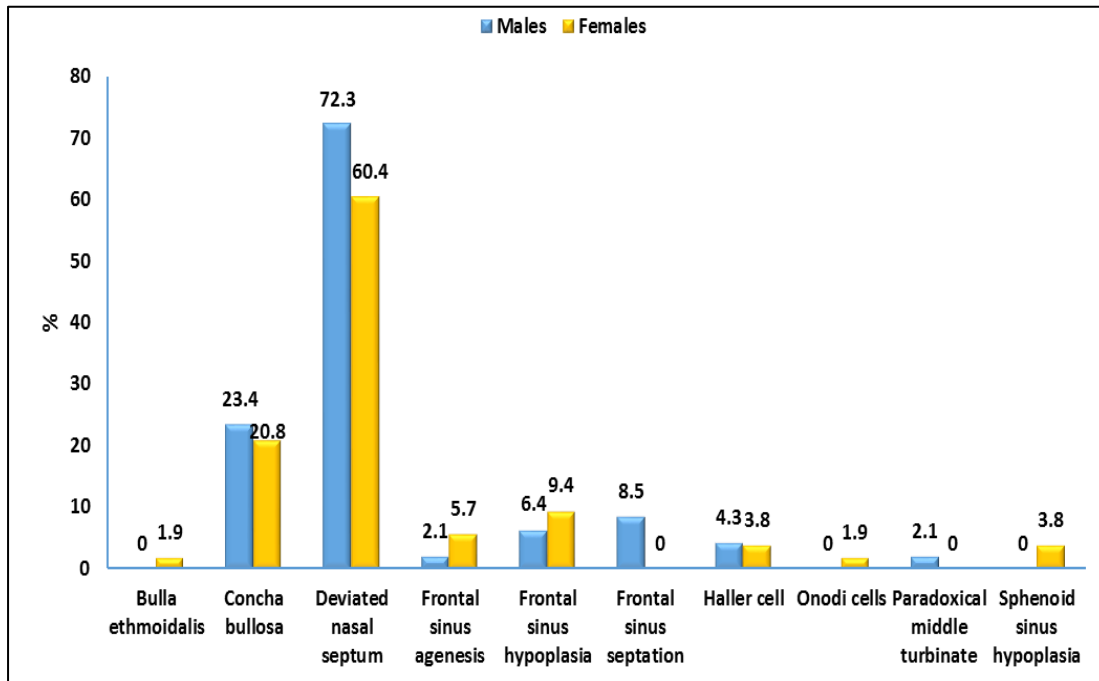
Frontal sinus septation was significantly higher in males (8.5%) than females (0.0%); P-value was 0.045. There were no significant differences between males and females regarding agger nasi cell, Bulla ethmoidalis (P-value = 1.0), Concha bullosa (P-value = 0.75), crista galli pneumatization, Deviated nasal septum (P-value = 0.208), Frontal sinus agenesis (P-

value = 0.62), Frontal sinus hypoplasia (P-value = 0.719), Haller cell (P-value = 1.0), Inferior turbinate pneumatization, Maxillary sinus hypoplasia, Maxillary sinus septation, Onodi cells (P-value = 1.0), Paradoxical middle turbinate (P-value = 0.470), Sphenoid sinus hypoplasia (P-value = 0.497), Sphenoid sinus septation, Superior turbinate pneumatization, Supraorbital cells, and Presence of at least

one abnormality (P-value = 0.203) (Figure 1).

#### Anatomical variations in different age groups

There was no significant difference between different age groups regarding the presence of at least one anatomical variation (P-value = 0.171) (Table 3).



**Figure (1)** Anatomical variations according to gender

Anatomical variations in the studied patients

Nasal septal deviation were the most common variations detected in (66%) of study population (Figure 2).

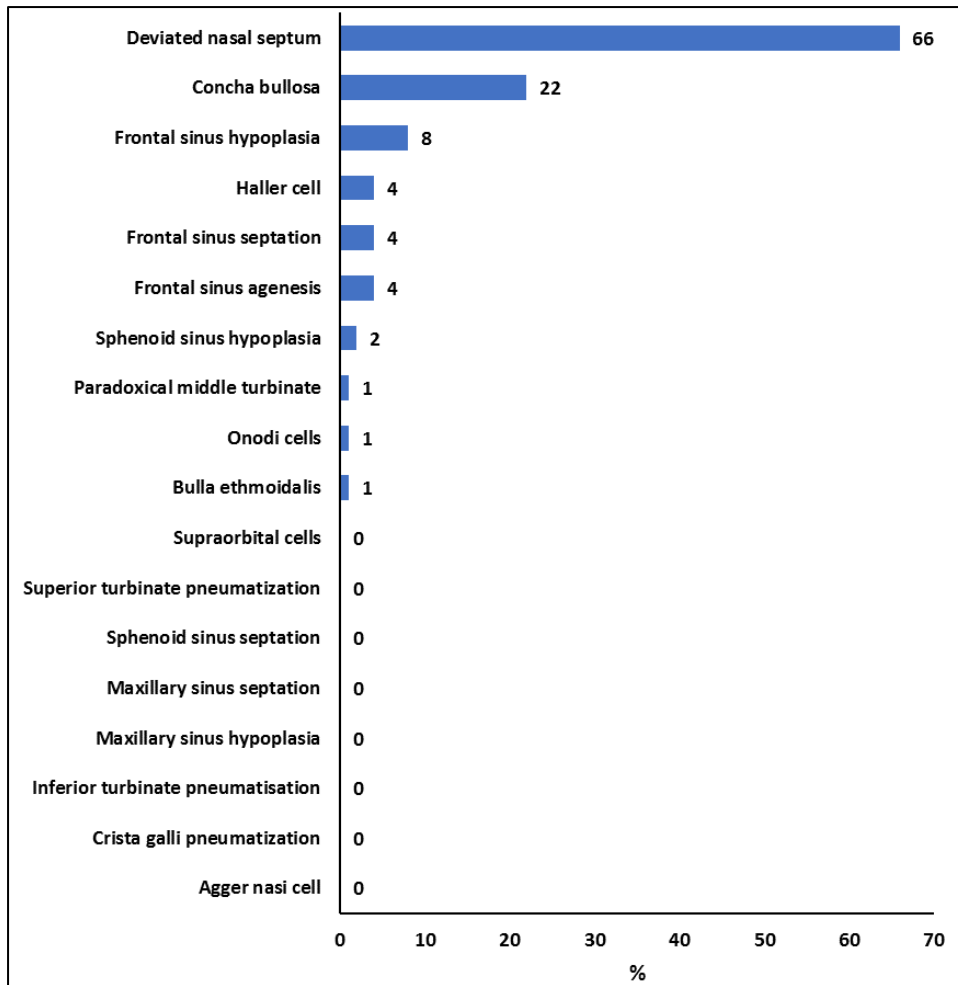
Anatomical variations according to mucosal abnormalities in sinuses

There was no significant difference between those with and without mucosal abnormalities in sinuses regarding the

presence of at least one anatomical variation (P-value = 0.130) (Table 4).

Distribution of mucosal abnormalities in different types of paranasal variants

Mucosal abnormalities were higher in patients with deviated nasal septum (43.5%) more than other types of paranasal variants, and even higher in patients who had more than one variant (41.3%) (Table 5).



**Figure (2)** Anatomical variations in the studied patients

**Table (3)** Anatomical variations according to age groups

	Age groups			P-value
	Up to 30 years	30 - 40 years	> 40 years	
<b>Presence of at least one anatomical variation</b>	43 (69.4)	14 (77.8)	18 (90.0)	0.171

Data were presented as numbers (percentage)

Chi-square test was used

**Table (4)** Anatomical variations according to mucosal abnormalities in sinuses

	Mucosal abnormalities in sinuses		
	Yes	No	P-value
<b>Presence of at least one anatomical variation</b>	46 (80.7)	29 (67.4)	0.130

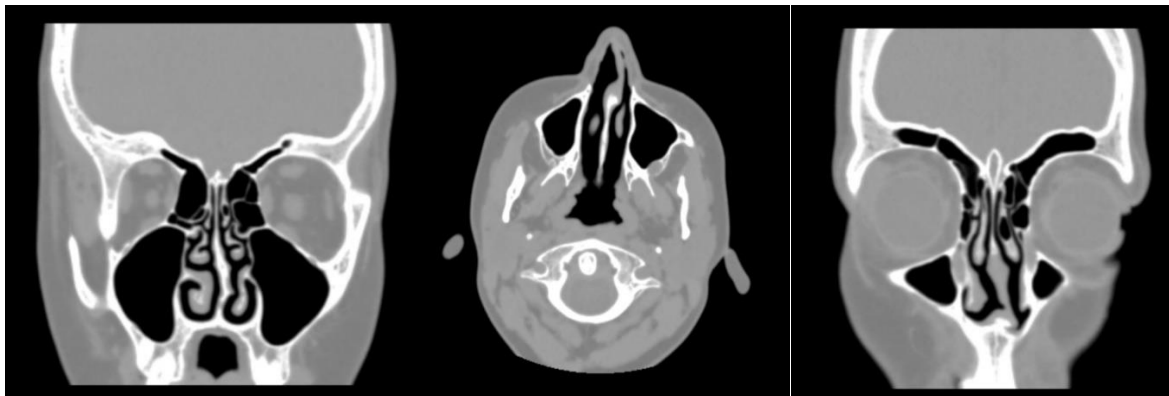
Data were presented as numbers (percentage)  
Chi-square test was used

**Table (5)** Distribution of mucosal abnormalities in different types of paranasal variants

<i>Paranasal Variants</i>	Mucosal abnormalities in sinuses n (%)
Deviated nasal septum	20 (43.5%)
Frontal sinus hypoplasia	3 (6.5%)
Concha bullosa	2 (4.3%)
Frontal sinus septation	1 (2.2%)
Frontal sinus agenesis	1 (2.2%)
More than one variant	19 (41.3%)

Percentage was calculated based on 46 patients who had at least one anatomical variation and mucosal abnormalities

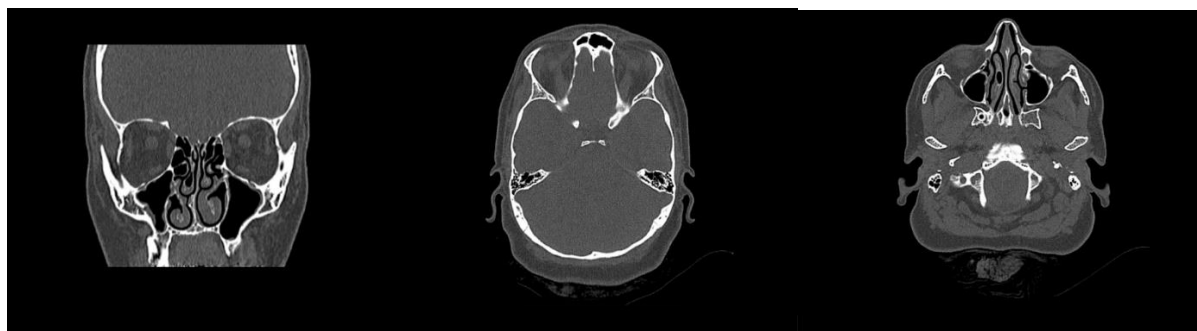**Case 1:** 13 years old male patient presented with difficulty in breathing. CT for PNS axial coronal and axial views (Bone Windows), bilateral middle turbinate paradox, left clear concha bullosa. Left side deviation of the nasal septum with bony nasal septum spur was detected (**Figure 3**).



**Figure 3:** 13 years old male patient with presented with difficulty in breathing. CT for PNS axial coronal and axial views (Bone Windows); Bilateral middle turbinate paradox, Left clear concha bullosa. Nasal septum deviation to left side with bony nasal septum spur.

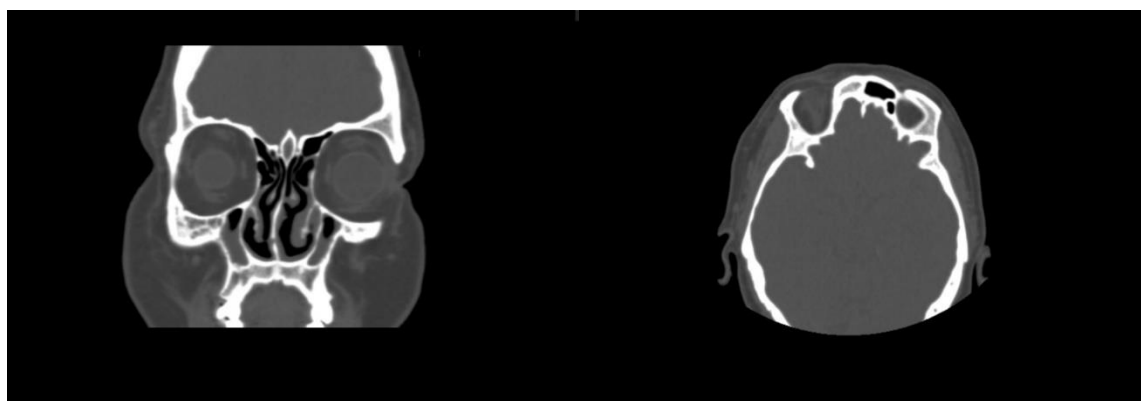
**Case 2:** 40 years old female patient. CT for PNS axial axial views (Bone Windows); Hypopneumatized right frontal sinus, well-developed other anterior and posterior groups of paranasal sinuses, shallow mucosal thickening of the floor of both maxillary antra, clear frontal and sphenoid sinuses as well as the ethmoidal air cells bilaterally. No air fluid level was seen,

both osteo-meatal units are patent, clear right concha bullosa, hypertrophied left inferior nasal turbinate, The nasal septum is deviated to the right side with clear naso-pharynx (**Figure 4**).



**Figure 4:** 40 years old female patient. CT for PNS axial axial views (Bone Windows); Hypopneumatized right frontal sinus, Well-developed other anterior and posterior groups of para-nasal sinuses, Shallow mucosal thickening of the floor of both maxillary antra, Clear frontal and sphenoid sinuses as well as the ethmoidal air cells bilaterally, No air fluid level seen, Patent both osteo-meatal units, Clear right concha bullosa, Hypertrophied left inferior nasal turbinate, The nasal septum is deviated to the right side, Clear naso-pharynx.

**Case 3:** 43 years old female patient. CT for PNS axial coronal an axial view (Bone Windows) showed non-pneumatized right frontal sinus, moderate circumferential mucosal wall thickening of both maxillary sinuses, minimal opacification of left sphenoidal as well as both ethmoidal sinuses. Normal appearance of other paranasal sinuses. Osteomeatal complexes were patent bilaterally. Mild deviation of the bony nasal septum to the right side was also detected (Figure 5)



**Figure 5:** 43 years old female patient. CT for PNS axial coronal an axial views (Bone Windows) Non-pneumatized right frontal sinus, Moderate circumferential mucosal wall thickening of both maxillary sinuses, Normal appearance of other paranasal sinuses. Patent ostiomeatal complexes bilaterally. Mild deviation of the bony nasal septum to the right side.

## Discussion

In the present study, the mean age of the studied patients was 30 years with a standard deviation of 12 years. Regarding gender, about half of the patients were males (47%), and 53% were females.

The mean age was slightly higher in many studies with also slightly male dominance. In a previous study (10), they included 240 patients with chronic rhinosinusitis 57.5% were males and 42.5% were females. Their



ages ranged from 20 to 61 years, with a mean age of 40.5 years. Also another study (11), stated that out of 852 patients evaluated on MDCT, 508 (59.6%) were males and 344 were females (40.4%) with a mean age of 40.3 years (age range, 14 to 78 years).

Most patients in the present study had no symptoms (67%). The most frequent symptom was difficulty breathing (11.0%), while the least frequent was mucosal thickening (1.0%). More than half of the patients (57.0%) had mucosal abnormalities in sinuses.

In contrast to our results, in a prior study (10), the most common clinical presentations were headache (52.5%), runny nose (35%), postnasal discharge (33.8%), and nasal obstruction (25%). Moreover, another study reported that the most common presenting symptom (12), was nasal obstruction (100%) which was present in all patients in this study. It was followed by nasal discharge/purulence/discholorated postnasal discharge (91%), cough (79%), headache and facial pain (73%), dental pain (64%), and facial congestion/fullness (63%). Less common symptoms were fatigue (16%), hyposmia (14%), halitosis (11%), ear pain/pressure/fullness (10%), and purulence on nasal cavity examination (5%).

In the present study, frontal sinus septation was significantly ( $p=0.045$ ) higher in males (8.5%) than females (0.0%). There were insignificant differences ( $p>0.05$ ) between males and females regarding agger nasi cell, bulla ethmoidalis, Concha bullosa, crista galli pneumatization, deviated nasal septum, frontal sinus agenesis, frontal sinus hypoplasia, Haller cell, Inferior turbinate pneumatization, Maxillary sinus hypoplasia, Maxillary sinus septation, Onodi cells, Paradoxical middle turbinate, Sphenoid sinus hypoplasia, Sphenoid sinus septation, Superior turbinate pneumatization,

Supraorbital cells, and presence of at least one abnormality. There was insignificant difference ( $p>0.05$ ) between different age groups in the present study regarding the presence of at least one anatomical variation. But, in comparison to other studies females were more affected (13, 14).

In our study, nasal septal deviation were the most common variants detected in (66%) patients. This result matched with results of many studies (15, 16).

The reported prevalence of septal variations in the literature ranges between 40% and 96.9% due to varying morphological features and the extent of deviation. A previous study (17), defined deviation as crooked nasal septum impinging on the adjacent structures, reported a prevalence of 40%. Other, less important septal variations include pneumatized nasal septum and nasal spur.

In our study, there was insignificant difference ( $p>0.05$ ) between those with and without mucosal abnormalities in sinuses regarding the presence of at least one anatomical variation. This came with different results in another study which showed that anatomic variations of paranasal sinus structures may predispose to chronic or recurrent sinusitis and to headaches (18). In the present study, higher percentage (43.5%) of mucosal abnormalities was found in patients with nasal septal deviation. This result conformed with the result of another study, who found that nasal septal deviation might be an important factor in causing nasal diseases and symptoms (19).

MDCT is helpful in evaluating the osteomeatal complex, soft tissue details and their relationship to bone and air containing sinuses. Coronal scans can detect the site and type of inflammation, and they optimally show the osteomeatal unit, the relationship between the brain and the ethmoid roof, and the relationship

between the orbits and the paranasal sinuses. Moreover, coronal images correlate with the surgical approach in FESS (20).

---

## Conclusion

Inspection of MSCT scans must be performed to identify anatomical variations involving the key area of the osteomeatal complex and frontal recess should be considered before surgical interventions.

---

## References

1. Souza SA, Souza MMA de, Idagawa M, Wolosker ÂMB, Ajzen SA. Análise por tomografia computadorizada do teto etmoidal: importante área de risco em cirurgia endoscópica nasal. *Radiol Bras*. 2008;41(3):143–7.
2. Al-Abri R, Bhargava D, Al-Bassam W, Al-Badaai Y, Sawhney S. Clinically Significant Anatomical Variants of the Paranasal Sinuses. *Oman Med J*. 2014 Mar; 29(2): 110–113. doi: 10.5001/omj.2014.27.
3. Hapugoda S, St-Amant M. et al. *Radiopaedia.org*. 2014. <https://radiopaedia.org/articles/paranasal-sinuses/revisions?lang=us>.
4. Kantarci M, Karasen RM, Alper F, et al. Remarkable anatomic variations in paranasal sinus region and their clinical importance. *Eur J Radiol* 2004; 50: 296-302
5. Kandukuri R, Phatak S. Evaluation of sinonasal diseases by computed tomography. *J Clin diagnostic Res JCDR*. 2016;10(11):TC09.
6. Cunqueiro A, Gomes WA, Lee P, Dym RJ, Scheinfeld MH. CT of the neck: image analysis and reporting in the emergency setting. *Radiographics*. 2019;39(6):1760–81.
7. Dewan K, Ray R, Nag D, Mullick MG, Mukhopadhyay S. Clinico-pathological evaluation of sinonasal neoplasm in a tertiary care hospital. *J Dent Med Sci*. 2013;6:20–6.
8. Onwuchekwa RC, Alazigha N. Computed tomography anatomy of the paranasal sinuses and anatomical variants of clinical relevants in Nigerian adults. *Egypt J Ear, Nose, Throat Allied Sci*. 2017;18(1):31–8.
9. Ling FTK, Kountakis SE. Rhinosinusitis Task Force symptoms versus the Sinonasal Outcomes Test in patients evaluated for chronic rhinosinusitis. *Am J Rhinol*. 2007;21(4):495–8.
10. Alsowey AM, Abdulmonaem G, Elsammak A, Fouad Y. Diagnostic performance of multidetector computed tomography (MDCT) in diagnosis of sinus variations. *Polish J Radiol*. 2017;82:713.
11. Shiekh Y, Wani AH, Khan AJ, Bhat MI. Anatomical Variations of Paranasal Sinuses- A MDCT Based Study. *Int Arch Intern Med*. 2019;6:300–6.
12. Zojaji R, Mirzadeh M, Naghibi S. Comparative evaluation of preoperative CT scan and intraoperative endoscopic sinus surgery findings in patients with chronic rhinosinusitis. 2008;
13. Yadav RR, Ansari MA, Humagain M, Mishra D. Assessment of anatomical variations of nose and paranasal sinuses in multidetector computed tomography. *J Inst Med* 2017; 39: 49-54.
14. Bolger EW, Butzin CA, Parsons DS. Paranasal sinus bony anatomic variations and mucosal abnormalities: CT analysis for endoscopic sinus surgery. *Laryngoscope* 1991; 101: 56-64.
15. Sharma BN, Pant OB, Lohani B, Khanal U. Computed Tomography in the Evaluation of Pathological Lesions of Paranasal Sinuses. *J Nepal Health Res Counc* 2015; 13: 116- 20.
16. Yadav RR, Ansari MA, Humagain M, Mishra D. Assessment of anatomical variations of nose and paranasal sinuses in multidetector computed tomography. *J Inst Med* 2017; 39: 49-54.
17. Luo X, Liang C, Xu K, Tang S, Ren X, Liu D. Influence of nasal septal deviation on incidence of bilateral sinusitis. *Lin Chuang er bi yan hou tou Jing wai ke za zhi= J Clin Otorhinolaryngol Head, Neck Surg*. 2012;26(17):777–80.
18. Rudmik L, Smith TL. Olfactory improvement after endoscopic sinus surgery. *Curr Opin Otolaryngol Head Neck Surg*. 2012;20(1):29.
19. Badhu B, Dulal S, Kumar S, Thakur S, Sood A, Das H. Epidemiology of chronic dacryocystitis and success rate of external dacryocystorhinostomy in Nepal. *Orbit* 2005;

24: 79-82.

20. Bhargava D, Bhargava K, Al-Abri A, Al-Bassam W, Al-Abri R. Non allergic rhinitis:

prevalence, clinical profile and knowledge gaps in literature. *Oman Med J.* 2011;26(6):416.

**To cite this article:** Medhat M. Reffat, Enas M. Sweed, Muntadher L. AbdulSahib. Role of MDCT in detection of paranasal variants and their surgical and clinical impact. *BMFJ* 2023; 40(Radiology):129-139.