

Targeting PPAR γ / Irisin pathway in the Potential Effect of Metformin on D-Galactose-Induced Hepatic Aging in Rats

Heba S. Youssef, Reham M. Ibrahim, Mahmoud M. Hassan, Marwa Hassan Muhammed, Alaa El-Deen A. El-talees

Department of Physiology,
Benha faculty of medicine,
Benha University, Egypt.

Correspondence to: Heba S. Youssef, Department of Physiology, Benha faculty of medicine, Benha University, Egypt.

Email:

salemheba4@gmail.com

Received: 26 May 2022

Accepted: 13 August 2022

Abstract:

Background: Aging-related changes in liver alter both hepatic structure and function, thus, increasing the mortality rate in susceptible old patients. Metformin provide health benefits to elderly individuals when ingested in appropriate amounts and it is one of the physiological triggers of Peroxisome Proliferator- Activated Receptor- Gamma (PPAR γ) and Irisin. **Aim:** This study aimed to investigate the effect of metformin on hepatic aging induced by D-galactose (D- gal) in rats, clarifying the role of PPAR γ / Irisin pathway in this process. **Methods:** 24 adult Wister albino male rats divided into 4 groups: group I (control group): rats received saline; ip, group II (D- gal group): rats received D- gal; ip, group III (Metformin group): rats received Metformin orally & group IV (Metformin + D- gal group): rats received D- gal with Metformin. At the end of experiment, the serum samples were taken for biochemical estimation of Alanine aminotransferase (ALT), Aspartate aminotransferase (AST), Albumin and hepatic tissue PPAR γ and Irisin protein levels.

Results: compared to control group, D- gal caused hepatic injury confirmed by a significant increase in ALT and AST with a significant decrease in Albumin. Metformin in group IV prevented these changes through increased hepatic PPAR γ and Irisin. **Conclusion:** Metformin showed a protective effect against the D- gal induced hepatic aging through induction of hepatic PPAR γ and Irisin.

Key words: Hepatic aging, D- gal, Metformin, PPAR γ , Irisin.

Abbreviations:

AGEs: advanced glycated end products; **ALT:** Alanine aminotransferase; **AST:** Aspartate aminotransferase; **D- gal:** D- galactose; **FNDC5:** fibronectin type III domain containing 5; **PPAR γ :** Peroxisome Proliferator- Activated Receptor- Gamma; **ROS:** reactive oxygen species; **TNF- α :** tumor necrosis factor- α .

Introduction:

Aging is a normal phenomenon that occur in all members of population. In that process, the ability to maintain homeostasis is lost gradually. Subsequently, human body becomes susceptible to stress and damage [1]. Aging is associated with a number of changes including hepatic malfunction and disintegration of its structure, including hepatic insulin resistance, reduction of hepatic flow and affection of liver cells including hepatocytes and liver endothelial sinusoidal cells thus, increasing the mortality rate in susceptible old patients [2]. Oxidative stress is one of the main pathogenesis of aging. The accumulated reactive oxygen species (ROS) attack essential cell constituents and also induce lipid peroxidation, damage the membranes of cells and organelles in liver- causing the swelling and necrosis of hepatocytes and ultimately result in liver injury [3].

Metformin is an orally administered drug used to lower blood glucose concentrations in patients with non-insulin-dependent diabetes mellitus. It is a hopeful drug in

aging [4]. However, its prophylactic role against hepatic aging still a matter of debate and controversy. So, we aimed to illustrate this issue.

Peroxisome Proliferator- Activated Receptor- Gamma (PPAR γ) is a nuclear receptor that expressed in white and brown adipose tissue, liver and many other organs [5]. Moreover, it exerts an anti-inflammatory and antioxidant effects. PPAR γ could enhance the up regulation of Irisin level [6].

Irisin is one of recently discovered hormone that produced by cleavage of the fibronectin type III domain containing 5 (FNDC5). It may act by increasing the expression of endothelial NO that plays an important role in vascular homeostasis and enhances liver sinusoidal endothelial cell function [7]. Metformin intervention could increase PPAR γ expression hence cleavage of FNDC5 and rising of Irisin.

Subsequently, this study was designed to investigate the potential protective effect of

Metformin on D- gal induced hepatic aging targeting PPAR γ / Irisin pathway as a suggested mechanism.

Material and methods:

Animals:

This is a prospective experimental study. This work was achieved using 24 adult male albino rats aged 6-8 weeks and weighted between 180 and 220 g. They were obtained from the animal research center in Faculty of Veterinary Medicine, Benha University. The experiment lasted 6 weeks from start of September 2020 to mid of October 2020 in Physiology Department, Faculty of Medicine, Benha University. All procedures are approved by ethical committee of Benha Faculty of Medicine (ethical approval number: BUFM12072020). The rats were fed a standard diet, with free access to food and water. They were placed at suitable room temperature. These conditions were continued for 10 days before the experiment, for acclimatization.

Drugs and chemicals used:

D- galactose (D- gal): provided as white powder extra pure >99% purchased from LOBA chemie Pvt.Ltd., Mumbai, India lot no: 59-23-4. **Metformin:** provided as tablets purchased from Merck/MinaPharm,

Heliopolis, Cairo, Egypt. **Aspartate aminotransferase (AST) estimation kits:** purchased from Spinreact Sant Esteve de Bas, Girona, Spain lot: MD41264. **Alanine aminotransferase (ALT) estimation kits:** purchased from Spinreact Sant Esteve de Bas, Girona, Spain lot: 1001170. **Albumin estimation kits:** purchased from Spinreact Sant Esteve de Bas, Girona, Spain lot: MX1001020. **PPAR- γ ELISA kits:** purchased from Abbexa LLC, Houston, TX, USA ; lot no: abx155996. **Irisin ELISA kits:** Mybiosource, Germany lot no: MBS843468.

Experimental design:

Male rats were divided into 4 groups, each containing 6 rats as follow:

Group (I): (Control group). Rats were injected by saline, intra-peritoneal and distilled water by oral gavage for 6 weeks.

Group (II): (D- gal group). Rats were injected intra peritoneally by D- gal (300 mg/kg/day for 5 days a week) dissolved in 3 ml saline for 6 weeks [3].

Group (III): (Metformin group). Metformin was given orally (300 mg/kg/ day) dissolved in 3ml distilled water daily for 6 weeks [8].

Group (IV): (Metformin + D- gal group). Metformin and D-gal were given the same

doses in the group III and group II, respectively

After the end of the experiment, the rats were anaesthetized with Na pentobarbital (40 mg/kg). The blood samples were taken for biochemical estimation of liver function. Also, hepatic samples were taken for biochemical PPAR γ and Irisin estimation.

Estimation of serum ALT, AST and Albumin:

Serum preparation:

Blood samples were left until clotting. Serum was separated by centrifugation at 3000 revolution per minute (rpm) for 15 min. After centrifugation, serum was pipetted out. Serum transferred to serum tubes (Eppendorf tubes) which were labeled and stored at -20° for biochemical assessment.

Estimation of liver function:

ALT and AST were determined depending on incubation of reagent with the enzyme to produce phenyl hydrazine which absorbs at 546 nm. The amount of phenyl hydrazine formed is directly proportional to the enzyme quantity [9]. Albumin bind with bromocresol green to produce a blue-green complex which absorbs at 628 nm. The

amount of complex formed is directly proportional to the enzyme quantity [10].

Tissue sampling:

The liver was immediately washed with normal saline and stored at -20° C for biochemical estimations of hepatic PPAR γ and Irisin using ELISA method.

Assessment of hepatic PPAR γ :

This ELISA kit used Sandwich-ELISA according to manufacture using instruction. The micro ELISA plate provided in this kit has been pre-coated with an antibody specific to Rat PPAR γ . Samples were added to the appropriate micro ELISA plate wells and bound by the specific antibody. Then a biotinylated detection antibody specific for Rat PPAR γ and HRP conjugate was added to each micro plate well successively and incubated. Free components are washed away. The substrate solution was added to each well. Only those wells that contain Rat PPAR γ , biotinylated detection antibody and HRP conjugate appeared blue in color. The enzyme-substrate reaction was terminated by the addition of a sulphuric acid solution and the color turns yellow. The optical density (OD) was measured spectrophotometrically at a wavelength of 450 nm +/- 2 nm. The OD value was proportional to the concentration

of Rat PPAR γ , calculated the concentration of Rat PPAR γ in the samples by comparing the OD of the samples to the standard curve [11].

Assessment of hepatic Irisin:

This assay is an ELISA assay for quantitative determination of Irisin. A polyclonal antibody recognizing native Irisin reacts with a series of predetermined recombinant Irisin standard proteins or samples under competition in the Irisin-coated plate. Their relative reactivity was plotted with that of the standard proteins as described before [12].

Statistical analysis:

The collected data were summarized in terms of mean \pm Standard Deviation (SD). Comparisons between the different study groups were carried out using the one-way analysis of variance (ANOVA; F value) followed by post hoc tests using the LSD method using the Statistical Package for Social Science (SPSS) program (IBM Corp. Released 2011. IBM SPSS Statistics for windows, Version 20.0. Armonk, NY: IBM Corp.). P-value < 0.05 was considered statistically significant.

Results:

Comparison between the study groups regarding ALT& AST (U/L) (Chart 1):

We can observe that, when rats were injected with D- gal in the **D- gal group** resulted in a significant increase ($P < 0.05$) in serum ALT and serum AST when compared with their corresponding in the **Control group**. Additionally, administration of Metformin alone to rats in the **Metformin group** resulted a non-significant change ($P > 0.05$) in serum ALT and serum AST when compared with their corresponding in the **Control group**. Likewise, by combined administration of metformin and D- gal in the **Metformin + D-gal group** resulted in a significant decrease ($P < 0.05$) in the serum ALT and serum AST when compared with their corresponding in the **D- gal group** while, there was a non-significant increase ($P > 0.05$) in their levels when compared with their corresponding in the **Control group** and the **Metformin group**.

Comparison between the study groups regarding Albumin(gm/dl) (Chart 2):

The **D- gal group** showed a significant decrease ($P < 0.05$) in serum albumin when compared with its corresponding in the **Control group**. Furthermore, in the **Metformin group**, there was a non-significant increase ($P > 0.05$) in serum

albumin when compared with its corresponding in the **Control group**. Additionally, in the **Metformin + D-gal group**, there was a significant increase ($P < 0.05$) in serum albumin when compared with its corresponding in the **D- gal group**. Also, there was a non-significant decrease ($P > 0.05$) in its level when compared with its corresponding in the **Control group** and the **Metformin group**.

Comparison between the study groups regarding hepatic PPAR γ and Irisin levels (Chart 3):

Regarding hepatic PPAR γ and Irisin, the **D-gal group** showed a significant decrease ($P < 0.05$) in hepatic PPAR γ and Irisin when

compared with their corresponding in the **Control group**. Additionally, **Metformin group** showed a non-significant change ($P > 0.05$) in hepatic PPAR γ and Irisin when compared with their corresponding in the **Control group**.

Interestingly, by combined administration of Metformin in the **Metformin + D- gal** group resulted in a significant increase ($P < 0.05$) in hepatic PPAR γ and Irisin when compared with their corresponding in **D- gal group**. But, there was a significant decrease ($P < 0.05$) when compared with their corresponding in the **Metformin group** and a nonsignificant decrease ($P > 0.05$) when compared with the **Control group**.

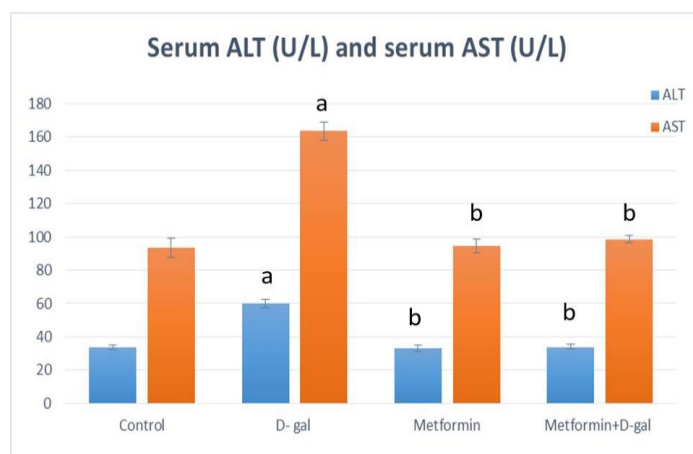


Chart (1): Mean & SD of serum ALT and AST (U/L) in the studied groups

Data are represented as mean \pm standard deviation (SD). $P < 0.05$ is significant tested by one-way analysis of variance (ANOVA) and post hoc multiple comparison LSD method.

^a $P < 0.05$ vs. control group ^b $P < 0.05$ vs D-gal group ^c $P < 0.05$ vs. Metformin group
D-gal: D- galactose; **ALT:** Alanine aminotransferase; **AST:** Aspartate aminotransferase.

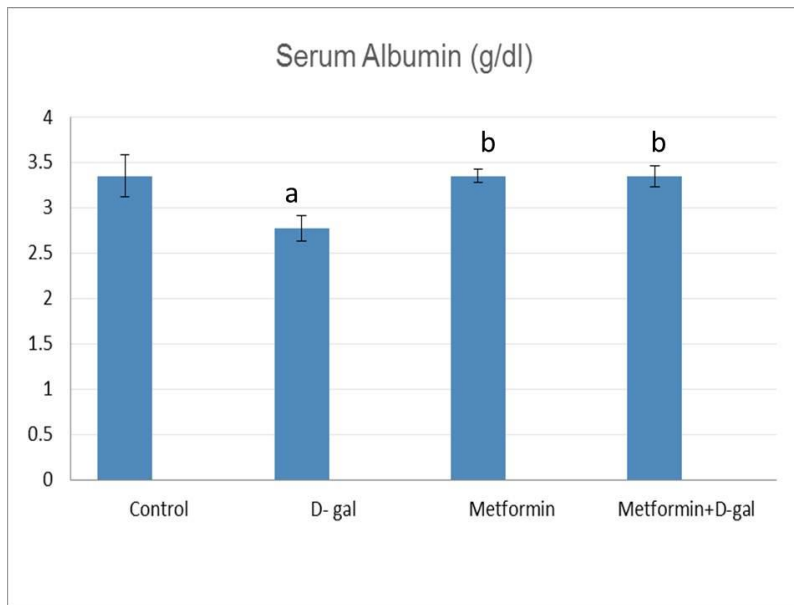


Chart (2): Mean & SD of serum albumin (gm/dl) in the studied groups

Data are represented as mean \pm standard deviation (SD). $P < 0.05$ is significant tested by one-way analysis of variance (ANOVA) and post hoc multiple comparison LSD method.

^a $P < 0.05$ vs. control group ^b $P < 0.05$ vs D-gal group ^c $P < 0.05$ vs. Metformin group.

D-gal: D- galactose; **ALT:** Alanine aminotransferase; **AST:** Aspartate aminotransferase.

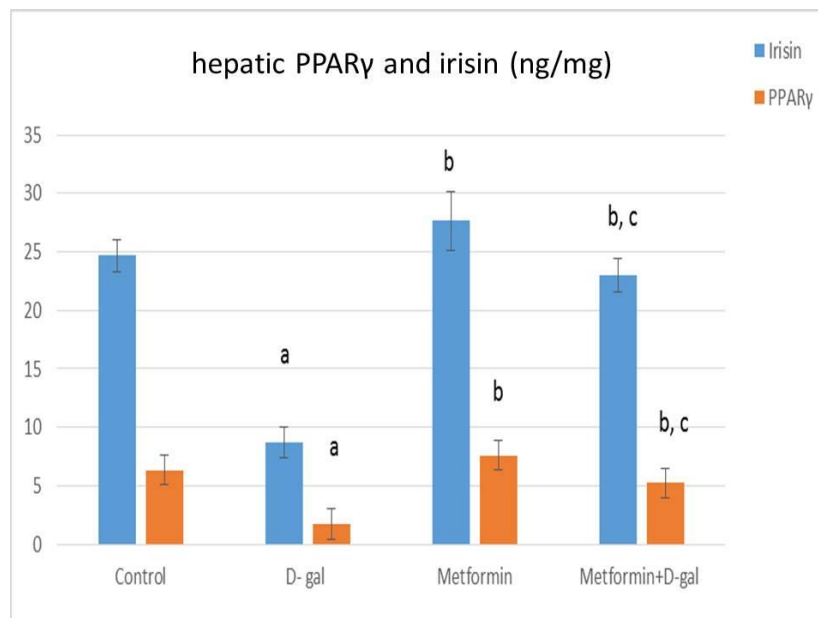


Chart (3): Mean & SD of hepatic PPAR γ and Irisin (ng/mg) in the studied groups

Data are represented as mean \pm standard deviation (SD). $P < 0.05$ is significant tested by one-way analysis of variance (ANOVA) and post hoc multiple comparison LSD method.

^a $P < 0.05$ vs. Control group ^b $P < 0.05$ vs D-gal group ^c $P < 0.05$ vs. Metformin group **D-gal:** D- galactose.

Discussion:

The liver is a complex metabolic organ that is essential for maintaining whole body homeostasis. It is important in energy regulation, metabolism, and molecular biosynthesis. Therefore, age-related changes in liver function contribute to systemic susceptibility to age-related diseases [13].

Chronic D- gal administration develops a valuable aging model that is accompanied by biochemical and histopathological changes in rats similar to the morphological and functional characteristics of the liver during natural aging [14]. It increases reactive oxygen species (ROS) which may subsequently cause oxidative stress, inflammation, mitochondrial dysfunction, and apoptosis. Additionally it decreases the level of nitric oxide therefore decreasing the hepatic flow [15]. Moreover, D- gal administration causes an increase in advanced glycated end products (AGEs) and upregulation of receptor of AGEs so, promotes D- gal action [16].

The results of the present work revealed that D- gal injection with respect to **Control group** resulted in a significant elevation in the level of liver enzymes (ALT and AST) and reduction of albumin level in the serum.

ALT, AST and albumin are major markers in monitoring the functional status of liver. The ALT activity is an important index to measure the degree of cell membrane damage. AST is an indicator of mitochondrial damage. The serum albumin is a marker of hepatic protein synthesis function [17] thus our finding confirmed the induction of hepatic aging.

These data was in agreement with previous studies [3, 18] which reported that D- gal induced hepatic aging attributed to a significant increase in the activities of AST, ALT and decline of albumin level.

This could be explained that D- gal can induce hepatic damage by increasing oxidative stress and AGEs in the liver [3]. Also, decrease level of NO that causes reduction of blood supply to liver cells [15] resulting in increasing the permeability, loss of membrane integrity of hepatocytes and/or necrosis causing excess cellular leakage of enzymes. Finally, it eventually causes liver dysfunction with hepatic protein affection [17].

Our research revealed that daily administration of Metformin alone, orally 300mg/kg for 6 weeks induced a non-significant change in level of serum ALT, AST and albumin in comparison with

Control group (Chart 1, 2). Our results were in agreement with previous studies [19, 20].

On studying the effect of Metformin on D-gal induced hepatic aging, we found that administration of Metformin in (**Metformin + D-gal group**) prevented the elevation of ALT, AST levels and decreased albumin level in serum (Chart 1,2).

These finding indicated the efficacy of Metformin in preserving the structural and functional integrity of the liver against the adverse effects of D-gal [21]. Metformin can reduce hepatic dysfunction through its membrane stabilization properties against ROS-mediated hepatocellular injury. Also, it inhibits hepatic expression of tumor necrosis factor- α (TNF- α) and TNF-inducible factors that promote hepatic injury and ATP depletion [8]. Furthermore, it promotes NO that increase hepatic flow through sinusoidal vasodilatation. All these factors lead to the improvement of the histopathological changes in liver diseases such as necrosis and decreased disruption of hepatocytes in liver [20].

To explore the possible other underlying prophylactic mechanisms of Metformin on D-gal induced hepatic aging, we investigated the hepatic level of PPAR γ and Irisin. The hepatic level of PPAR γ and Irisin was significantly decrease in (**D-gal group**)

when compared to **control group** . These findings are in the same vein with the previous report [15].

The decrease in hepatic tissue Irisin on D-gal administration might be due to decrease PPAR γ expression by the injured hepatic cell and hepatic stellate cells via ROS and inflammatory cytokines that resulted from long term D-gal administration [22]. The reduction in the expression of PPAR γ causes decrease in the proteolytic cleavage of FNDC5 hence decrease Irisin level so, it aggravates the hepatic injury produced by D-gal.

We found that administration of Metformin causes hepatic PPAR γ and Irisin levels we significantly increased in (**Metformin + D-gal**) when compared to (**D-gal group**). These results were consistent with that of the previous report [23]. This could be explained that Metformin increase PPAR γ expression [24] so, promotes proteolytic cleavage of FNDC5 hence Irisin release from skeletal muscle into blood and increases level of Irisin. Irisin enhances the upregulation of endothelial NO that is the major weapon of endothelial cells to fight vascular diseases through enhancement of sinusoidal vasodilatation which resulted in improvement of hepatic supply that diminished with aging. So, this leads to protection of liver from injury [7].

Conclusion:

In conclusion, we found that Metformin prevented the D- gal induced hepatic injury. This ameliorative effect could be explained by Metformin's stimulatory effect on PPAR γ /Irisin.

References:

1. **Hodgson, R., Kennedy, B. K., Masliah, E., Scearce-Levie, K., Tate, B., Venkateswaran, A., et al (2020).** Aging: therapeutics for a healthy future. *Neuroscience & Biobehavioral Reviews*, 108, 453-458.
2. **Hunt, N. J., Lockwood, G. P., Kang, S. W., Pulpitel, T., Clark, X., Mao, H., et al (2020).** The effects of metformin on age-related changes in the liver sinusoidal endothelial cell. *The Journals of Gerontology: Series A*, 75(2), 278-285.
3. **Saleh, D. O., Mansour, D. F., Hashad, I. M., & Bakeer, R. M. (2019).** Effects of sulforaphane on D-galactose-induced liver aging in rats: Role of keap-1/nrf-2 pathway. *European journal of pharmacology*, 855, 40-49.
4. **Novelle, M. G., Ali, A., Diéguez, C., Bernier, M., & de Cabo, R. (2016).** Metformin: a hopeful promise in aging research. *Cold Spring Harbor perspectives in medicine*, 6(3), a025932.
5. **Silva, A. R., Gonçalves-de-Albuquerque, C. F., Pérez, A. R., & de Frias Carvalho, V. (2019).** Immune-endocrine interactions related to a high risk of infections in chronic metabolic diseases: The role of PPAR gamma. *European journal of pharmacology*, 854, 272-281.
6. **Lanzi, C. R., Perdicaro, D. J., Tudela, J. G., Muscia, V., Fontana, A. R., Oteiza, P. I., et al (2020).** Grape pomace extract supplementation activates FNDC5/irisin in muscle and promotes white adipose browning in rats fed a high-fat diet. *Food & Function*, 11(2), 1537-1546.
7. **Hadi, A., Arab, A., Hajianfar, H., Talaei, B., Miraghajani, M., Babajafari, S., et al (2020).** The effect of fenugreek seed supplementation on serum irisin levels, blood pressure, and liver and kidney function in patients with type 2 diabetes mellitus: A parallel randomized clinical trial. *Complementary therapies in medicine*, 49, 102315.
8. **Brandt, A., Hernández-Arriaga, A., Kehm, R., Sánchez, V., Jin, C. J., Nier, A., et al (2019).** Metformin attenuates the onset of non-alcoholic fatty liver disease and affects intestinal microbiota and barrier in small intestine. *Scientific reports*, 9(1), 1-14.
9. **Reitman, S., & Frankel, S. (1957).** A colorimetric method for the determination of serum glutamic oxalacetic and glutamic pyruvic transaminases. *American journal of clinical pathology*, 28(1), 56-63.
10. **Doumas, B. T., Watson, W. A., & Biggs, H. G. (1971).** Albumin standards and the measurement of serum albumin with bromocresol green. *Clinica chimica acta*, 31(1), 87-96.
11. **Cho, M. C., Lee, H. S., Kim, J. H., Choe, Y. K., Hong, J. T., Paik, S. G., et al (2003).** A simple ELISA for screening ligands of peroxisome proliferator-activated receptor γ . *BMB Reports*, 36(2), 207-213.
12. **Halawa, M. R., Abdelsalam, M. M., Mostafa, B. M., & Ahmed, A. G. (2018).** Assessment of serum irisin level in thyroid disorder. *The Egyptian Journal of Internal Medicine*, 30(4), 197.
13. **Horst, A. K., Tiegs, G., & Diehl, L. (2019).** Contribution of macrophage efferocytosis to liver homeostasis and disease. *Frontiers in Immunology*, 10, 2670.
14. **Blat, A., Stepanenko, T., Bulat, K., Wajda, A., Dybas, J., Mohaissen, T., et al (2021).** Spectroscopic signature of red blood cells in a D-galactose-induced accelerated aging model. *International journal of molecular sciences*, 22(5), 2660.
15. **Azman, K. F., & Zakaria, R. (2019).** D-Galactose-induced accelerated aging model: an overview. *Biogerontology*, 1-20.
16. **Shwe, T., Pratchayasakul, W., Chattipakorn, N., & Chattipakorn, S. C. (2018).** Role of D-galactose-induced brain aging and its potential used for therapeutic interventions. *Experimental gerontology*, 101, 13-36.

17. **Abdulkhaleq, F. M., Alhussainy, T. M., Badr, M. M., Khalil, A. A. A., Gammoh, O., Ghanim, B. Y., & Qinna, N. A. (2018).** Antioxidative stress effects of vitamins C, E, and B12, and their combination can protect the liver against acetaminophen-induced hepatotoxicity in rats. *Drug design, development and therapy*, 12, 3525.
18. **Mohammadi, E., Mehri, S., Bostan, H. B., & Hosseinzadeh, H. (2018).** Protective effect of crocin against d-galactose-induced aging in mice. *Avicenna journal of phytomedicine*, 8(1), 14.
19. **Shavakhi, A., Minakari, M., Firouzian, H., Assali, R., Hekmatdoost, A., & Ferns, G. (2013).** Effect of a probiotic and metformin on liver aminotransferases in non-alcoholic steatohepatitis: a double blind randomized clinical trial. *International journal of preventive medicine*, 4(5), 531.
20. **Cahova, M., Palenickova, E., Dankova, H., Sticova, E., Burian, M., Drahota, Z., et al (2015).** Metformin prevents ischemia reperfusion-induced oxidative stress in the fatty liver by attenuation of reactive oxygen species formation. *American Journal of Physiology-Gastrointestinal and Liver Physiology*, 309(2), G100-G111.
21. **Beheshti, F., Hosseini, M., Arab, Z., Asghari, A., & Anaigoudari, A. (2020).** Ameliorative role of metformin on lipopolysaccharide-mediated liver malfunction through suppression of inflammation and oxidative stress in rats. *Toxin Reviews*, 1-9.
22. **Rahimi, V. B., Askari, V. R., & Mousavi, S. H. (2019).** Ellagic acid dose and time-dependently abrogates d-galactose-induced animal model of aging: Investigating the role of PPAR- γ . *Life sciences*, 232, 116595.
23. **Li, Y., Liu, L., Wang, B., Wang, J. U. N., & Chen, D. (2013).** Metformin in non-alcoholic fatty liver disease: A systematic review and meta-analysis. *Biomedical reports*, 1(1), 57-64.
24. **Pinyopornpanish, K., Leerapun, A., Pinyopornpanish, K., & Chattipakorn, N. (2021).** Effects of metformin on hepatic steatosis in adults with nonalcoholic fatty liver disease and diabetes: insights from the cellular to patient levels. *Gut and liver*, 15(6), 827.

To cite this article: Heba S.Youssef , Reham M. Ibrahim, Mahmoud M. Hassan, Marwa Hassan Muhammed, Alaa El-Deen A. El-talees. Targeting PPAR γ / Irisin pathway in the Potential Effect of Metformin on D-Galactose-Induced Hepatic Aging in Rats. BMFJ 2022;39 (academic issue):266-276.