

## Comparative Study of Endonasal Dacryocystorhinostomy with Silicone or Polypropylene Stents Using Mitomycin C

Ahmed F. Allam, Hossam M. Abd Elbaky, Abo Bakr A. Abd El Raouf, Abdel Hakim F. Ghallab, Ramy F. Tantawy, Alaa M. Abd El Samie

Department of Otorhinology,  
Benha faculty of medicine,  
Benha University, Egypt

**Correspondence to:** Ramy F. Tantawy, Department of otorhinology, Benha faculty of medicine, Benha University, Egypt.

**Email:**

ramyaboelata7@gmail.com

**Received:** 9 March 2022

**Accepted:** 13 August 2022

**Abstract**

**Background:** Endoscopic dacryocystorhinostomy (En-DCR) is a minimally invasive surgery used in the treatment of nasolacrimal duct obstruction and chronic dacryocystitis. It involves fistulization of the lacrimal sac into the nasal cavity. **Objective:** The aim was to compare the efficacy and safety of endoscopic dacryocystorhinostomy (En-DCR) with Silicone and polypropylene stents for treatment of primary nasolacrimal ductal obstructions with and without using of mitomycin C (MMC). **Patients and methods:** A prospective randomized clinical study involved forty patients with epiphora due to primary acquired nasolacrimal duct obstruction (PANLDO) attending to the outpatient clinic of departments of Otorhinolaryngology and Ophthalmology of Benha University Hospitals at the period from January 2017 to December

2019. Patients were allocated into two groups. Group (1) Included 20 patients treated by En-DCR with Silicone stent. Group (2) Included 20 patients treated by En-DCR with polypropylene (Prolene) stent. Each group was subdivided into two subgroups A & B each subgroup included 10 patients. In subgroup **A**, MMC was applied locally intraoperative while in subgroup **B** no MMC was used. All patients underwent preoperative evaluation in the ophthalmology and otolaryngology clinics with endoscopes, lacrimal system syringing and dacryocystography.

**Results:** The overall success rate of the En-DCR (as regarding the symptom relief and observed duct patency) was 95% and 80% in silicone and prolene groups, respectively. The efficacy of the procedures was slightly increased with use of MMC. Prolene was found to be related with higher incidence of complications. **Conclusion:** The results of our study suggest that efficacy, defined as anatomic and functional success, is higher for silicone than Prolene stents. Also the intraoperative use of MMC is safe and improves the success rate of En-DCR.

**Keywords:** Endoscopic, dacryocystorhinostomy, Prolene, Silicone, Mitomycin C.

## Introduction

Primary acquired nasolacrimal duct obstruction (PANDO) is the most common clinical syndrome of acquired nasolacrimal duct obstruction in adults. Patients may present **with** symptoms of chronic epiphora, conjunctivitis, and low-grade infections or with acute dacryocystitis. This clinical syndrome is most common in elderly white women (1).

The En-DCR is a minimally invasive surgery used in the treatment of nasolacrimal duct obstruction and chronic dacryocystitis. It involves fistulization of the lacrimal sac into the nasal cavity. In addition to being minimally invasive, it has advantages such that its short operation duration, little bleeding, not leaving an external scar, not causing injury of medial chenthal anatomy or lacrimal sac pump dysfunction (2,3).

Different types of stent materials have been used to prevent the obliteration of the surgically created rhinostomy site either in a selective or nonselective manner (4). A stent should be reliable, readily available, easily applicable, and preferably cheap. The efficacy of the previously reported materials

has not been validated in prospective controlled trials

Mitomycin-C is a systemic chemotherapeutic agent derived from *Streptomyces caespitosus* that inhibits the synthesis of DNA, cellular RNA, and protein by inhibiting the synthesis of collagen by fibroblasts (5).

So, we conducted this prospective randomized controlled trial to compare the clinical efficacy and outcomes of silicone and polypropylene for stenting in En-DCR with and without MMC.

## Patients and Methods

A hospital-based prospective interventional study involved forty patients with epiphora due to of primary acquired nasolacrimal duct obstruction (PANLDO) attending to the outpatient clinic of departments of Otorhinolaryngology and Ophthalmology of Benha University Hospitals at the period from January 2017 to December 2019. Patients were allocated into two groups. Group (1) Included 20 patients treated by En-DCR with Silicone stent. Group (2) Included 20 patients treated by En-DCR

with polypropylene (Prolene) stent. Each group was subdivided into two subgroups. Each subgroup included 10 patients. In subgroup A, local application of MMC was used while in subgroup B no MMC was used.

Patients older than 18 years of age were eligible. The indication for surgery was primary acquired NLDO with epiphora. Exclusion criteria were bleeding disorders and any history of ophthalmic (including previous DCR) or nasal surgery, patients with traumatic, neoplastic, mechanical (*i.e.*, foreign body, external compression), or presacal obstruction and nasolacrimal fistulization.

Initially, all patients underwent Ophthalmology and otolaryngology evaluation, including lacrimal system syringing and dacryocystography. Patients with a confirmed blockage of the lacrimal ductal system were included.

Endoscopic evaluation of the nose, paranasal sinuses, and nasopharynx was performed to rule out any concomitant nasal pathology that may have interfered with the surgery.

All operative and non-operative procedures were explained in full details to the patients, who signed informed consents and accepted to be involved in the study. In addition,

approval from the Ethical Committee of ENT Department, Benha University, was obtained.

### **Operative procedure**

All patients underwent En- DCR under general anaesthesia. A Bowman lacrimal probe is passed through the inferior canaliculus into the lacrimal sac (**Figure 1**). Using nasal endoscope attached to a camera, adrenaline 1:20000 is injected submucosally to the lateral nasal wall corresponding to the sac location just anterosuperior to the insertion of the middle turbinate. A curved incision is made by sickle knife at the lateral nasal wall mucosa including periostium, just anterior to the attachment of the middle turbinate. A suction Freer's elevator was used to lift the mucosal flap, keeping the mucosa between the middle turbinate and the lateral nasal wall intact. Approximately 1–1.5 cm of nasal mucosa is removed with through cut forceps.

The thin lacrimal bone is identified just posterior to the frontal process of the maxilla. It is fractured and removed by an elevator.

After removal of lacrimal bone, mild cutaneous pressure and moving of the probe will show motion of the exposed sac

internally. A Kerrison's forceps is used to remove the thin inferior portion of the frontal process of the maxilla.

Incision of the medial wall of the sac is performed with 11-blade and the mucosal opening enlarged with angled endoscopic forceps.

Once the ostium is formed, bicanalicular intubation with Silicone or polypropylene stents is placed (**figure 2**). The application of MMC to the nasal and lacrimal sac mucosal surfaces used a cotton tip applicator soaked in 0.5% solution of MMC applied under the nasal and lacrimal flaps for 10 minutes duration followed by copious irrigation with normal saline. Gentle nasal packing was done for all the patients. The patients were followed-up for period of 6 months for early post-operative and late complications.

Nasal packing is removed at the post-operative day-one visit. Systemic antibiotics are recommended for 7–10 days.

Each postoperative visit included debridement of crusting around ostium, lacrimal irrigation, and inspection of the surgical site with nasal endoscopy. Stents advocate removal after 6 to 8 weeks.

**Data management and statistical analysis** were done by using SPSS version 22 medical statistics software and Microsoft Excel v. 2013 (SPSS Inc., Chicago, Illinois, USA). Descriptive statistics were calculated in the form of mean  $\pm$  SD for quantitative data and frequency and distribution for qualitative data.

In the statistical comparison between the different groups, the significance of difference was tested by using analysis of variance test (*P* value) to compare mean of more than two groups of quantitative data or Fisher's exact test for intergroup comparison of categorical data ( $P < 0.05$  was considered statistically significant).

## Results

Demographic criteria of patients of Age and sex distribution were not statistically different among the groups.

As regard **Munk Scale for epiphora grading (figure 3)**, the overall improvement was 19 patients (95%) and 16 patients (80%) in silicone and prolene groups, respectively. A very good improvement (grade 0) was achieved in 14 patient (70%) and 11 patients (55%) of silicone and prolene groups, respectively. Good improvement (grade 1, 2) was achieved in 3 patients (15%) and 2

patients (10%) of silicone and prolene groups, respectively. Partial improvement (grade 3, 4) was observed in 2 patients 10% and 3 patients 15% of silicone and prolene groups, respectively. However, failure (grade 5) was observed in only 1 patient (5%) and 4 patients (20%) of silicone and prolene groups, respectively. They all showed statistically significant difference in comparison between the two groups ( $P < 0.05$ ) **Table 1.**

As regard to effect of MMC application on success rates of En-DCR in silicone group: there is very good improvement (grade 0) achieved in 8 patients (80%) and 6 patients (60%) of patients with and without MMC, respectively with statistically significant difference ( $P = 0.017$ ). Good improvement (grade 1, 2) was achieved in 2 patients (20%) of both with and without MMC application. Partial improvement (grade 3, 4) was observed in 1 patient (10%) of patients without MMC only. All patients (100%) had recovery by using MMC and 90% had recovery in patients operated without MMC application with statistically significant difference in comparison between with and without MMC ( $P > 0.05$ ) **table 2.**

Also, the effect of MMC application on success rates of En-DCR in prolene group: there is very good improvement (grade 0) achieved in 7 patients (70%) and 3 patients (30%) of patients with and without MMC, respectively with statistically significant difference ( $P = 0.023$ ). Good improvement (grade 1, 2) was achieved in 2 patients (20%) and 1 patient (10%) of both with and without MMC application, respectively ( $p = 0.034$ ). Partial improvement (grade 3, 4) was observed in 1 patient (10%) of patients without MMC only ( $p = 0.028$ ). The overall success was achieved in 9 patients (90%) and 7 patients (70%) of patients with and without MMC, respectively with statistically highly significant difference in comparison between with and without MMC ( $P = 0.001$ ). However, failure (grade 5) was observed in 1 patient (10%) and 3 patients (30%) in patients with and without MMC application, respectively, they showed a statistically significant difference ( $P = 0.037$ ) **table 3.**

As regard to postoperative complications in silicone group: Granulation was observed in 2 patients (20%) of patients without MMC. Complete tube closure was observed in 1 patient (10%) of patients without MMC and Fibrosis around the tube was observed in 2 patient (20%) of patients without MMC.

They all had statistically insignificant difference in comparison between patients with and without MMC ( $P > 0.05$ ) **table 4.**

**Finally** postoperative complications in prolene group: Granulations was observed in 1 patient (10%) and 4 patients (40%) of patients with and without MMC, respectively with statistically significant difference ( $P = 0.032$ ). Conjunctivitis, canalicular laceration, and infection were observed in 1 patient (10%) of both patients with and without MMC in each

complication with statistically insignificant difference ( $P > 0.05$ ).

Punctal slitting was observed in 1 patient (10%) of patients without MMC ( $P > 0.05$ ). Complete tube closure was observed in 3 patients (30%) of patients without MMC with statistically significant difference ( $P = 0.028$ ) and Fibrosis around the tube was observed in 4 patients (40%) of patients without MMC with statistically significant difference in comparison between patients with and without MMC ( $P = 0.007$ ) **table 5.**

**Table (1):** Success rates of En-DCR according to symptom resolution provided by patient among the stent type groups

Outcome	Group (1) Silicone		Group (2) Prolene		Test of significance	
	No.	%	No.	%	$\chi^2$ -test	P value
<b>Improvement</b>						
Very good (grade 0)	14	70.0	11	55	3.844	0.041*
Good (grade 1,2)	3	15.0	2	10.0	2.364	0.049*
Partial (grade 3,4)	2	10.0	3	15.0	-2.364	0.049*
<b>Overall improvement</b>	<b>19</b>	<b>95.0</b>	<b>16</b>	<b>80.0</b>	<b>5.968</b>	<b>0.007*</b>
Failure (grade 5)	1	5.0	4	20.0	-4.925	0.032*
<b>Total</b>	<b>20</b>	<b>100</b>	<b>20</b>	<b>100</b>		

**Table (2):** Effect of MMC application on success rate of the silicone group.

Outcome success	With MMC (n = 10)		Without MMC (n = 10)		Test of significance	
	No.	%	No.	%	$\chi^2$ -test	P value
Very good(grade 0)	8	80.0	6	60.0	4.283	0.017*
Good (grade 1,2)	2	20.0	2	20.0	0.000	1.000
Partial (grade 3,4)	0	0.00	1	10.0	-2.228	0.058
<b>Overall success</b>	<b>10</b>	<b>100</b>	<b>9</b>	<b>90.0</b>	<b>3.832</b>	<b>0.029*</b>
Failure (grade 5)	0	0.00	1	10.0	-2.228	0.058
<b>Total</b>	<b>10</b>	<b>100</b>	<b>10</b>	<b>100</b>		

$\chi^2$  = Chi square test, \*P <0.05 (significant).

**Table (3):** Effect of MMC application on success rate of the prolene group.

Outcome success	With MMC (n = 10)		Without MMC (n = 10)		Test of significance	
	No.	%	No.	%	$\chi^2$ -test	P value
Very good (grade 0)	7	70.0	3	30.0	4.024	0.023*
Good (grade 1,2)	2	20.0	1	10.0	3.172	0.034*
Partial (grade 3,4)	0	0.00	3	30.0	-4.948	0.028*
<b>Overall success</b>	<b>9</b>	<b>90.0</b>	<b>7</b>	<b>70.0</b>	<b>5.968</b>	<b>0.001*</b>
Failure (grade 5)	1	10.0	3	30.0	-4.364	0.037*
<b>Total</b>	<b>10</b>	<b>100</b>	<b>10</b>	<b>100</b>		

$\chi^2$  = Chi square test, \*P <0.05 (significant).

**Table (4):** Comparison of postoperative complications of the silicone group as regard to mitomycin-C application.

Complications	With MMC (n = 10)		Without (n = 20)		Statistical test of significance	
	No.	%	No.	%	$\chi^2$ -test	P value
Granulations	0	0.00	2	20.0	2.013	0.061
Conjunctivitis	1	10.0	1	10.0	0.000	1.000
Punctal slitting	0	0.00	0	0.00	N/A	N/A
Canalicular laceration	0	0.00	0	0.00	N/A	N/A
Infection	0	0.00	0	0.00	N/A	N/A
Complete tube closure	0	0.00	1	10.0	2.228	0.058
Fibrosis around the tube	0	0.00	2	20.0	2.013	0.061

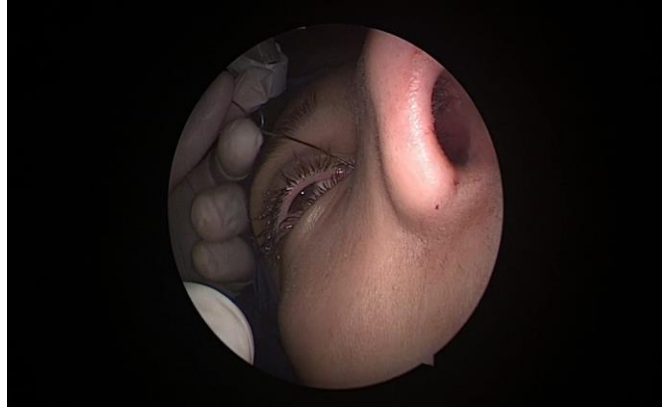$\chi^2$  = Chi square test, \*P <0.05 (significant).

**Table (5):** Comparison of postoperative complications of the prolene group as regard to mitomycin-C application.

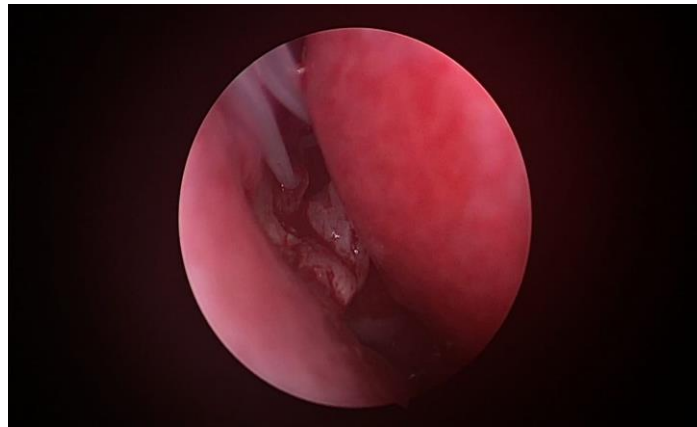
Complications	With MMC (n = 10)		Without (n = 20)		Statistical test of significance	
	No.	%	No.	%	$\chi^2$ -test	P value
Granulations	1	0.00	4	40.0	4.925	0.032*
Conjunctivitis	1	10.0	1	10.0	0.000	1.000
Punctal slitting	0	0.00	1	10.0	2.228	0.058
Canalicular laceration	1	10.0	1	10.0	0.000	1.000
Infection	1	10.0	1	10.0	0.000	1.000
Complete tube closure	0	0.00	3	30.0	4.948	0.028*
Fibrosis around the tube	0	0.00	4	40.0	5.156	0.007*

$\chi^2$  = Chi square test, \*P <0.05 (significant).





**Fig. 1:** placement of a Bowman lacrimal probe into the lacrimal sac through punctum.



**Fig. 2:** Elevated mucoperiosteal flap and silicon tube pass through lacrimal sac.

<i>Grade</i>	<i>Munk Scale</i>
0	No epiphora
1	Epiphora requiring dabbing less than twice a day
2	Epiphora requiring dabbing 2-4 times a day
3	Epiphora requiring dabbing 5-10 times a day
4	Epiphora requiring dabbing more than 10 times a day
5	Constant epiphora

**Fig.(3):** Munk Scale for epiphora grading

## Discussion

Closure of the rhinostomy opening was considered a major factor for surgical failure in external DCR (18). Endocanalicular stenting is believed to maintain the patency of the ostium during the post-operative period & healing process (6). Mitomycin-C (MMC) is currently in use as an adjuvant treatment to improve success rates in En-DCR. The procedure is well-recognized surgical techniques and is associated with very high success rates. MMC is a systemic chemotherapeutic agent derived from *Streptomyces caespitosus* that inhibits the synthesis of DNA, cellular RNA, and protein by inhibiting the synthesis of collagen by fibroblasts (11).

Although controversial, silicone stents are used to keep the neo-ostium open after the procedure and are thought to maintain the patency of the ostium by preventing circular stenosis of the neo-ostium in the post-operative healing period (19).

During the study done in 2015, it was noted that the failure of endoscopic DCR especially in cases where no stent was used, were because of granulations and scarring near stoma (6).

In the present study, we compared the clinical efficacy, safety and outcomes of silicone and polypropylene for stenting in En-DCR with and without MMC. Our study showed high success rate and low failure rate with group 1 (silicone stenting), with statistically significant difference in comparison between the two groups ( $P < 0.05$ ). These results coincide with that of others (10), who reported that the success rate with polypropylene stenting in endoscopic DCR procedures was 80% and success rate with silicone tube stenting was 90%, failure reported in one patient (10%) in both groups.

However, our results do not coincide with the study done in 2015 (8) which reported no significant differences between the use of silicone and Prolene stents in En-DCR. ( $p = 0.718$ )

The overall complication rate was significantly higher in group 2 (prolene stenting). However, orbital complications including orbital injury, Conjunctivitis, Punctal slitting and Canalicular laceration were insignificantly higher in prolene than silicon stenting. These result do not coincide with that study done in 2015 (8) where the efficacy of Silicone, Polypropylene, and T-

tube Stents in En-DCR were compared, and concluded that the overall complication rate was not significantly different among the stents ( $P = 0.20$ ). However, Prolene had significantly higher orbital complications than other stent materials ( $P = 0.003$ ).

While the use of MMC has been increasingly popular in DCR, there is a lack of consensus regarding multiple variables; namely the dosage, the route of delivery/application, the time of exposure and subsequently what role each of these variables plays in the final outcome of the surgery. Ever since the intraoperative use of MMC has been a part of DCR, various studies have put forth their data with varying concentrations of MMC (12).

In the present study there are significant improvement of success rates of En-DCR with the application of intraoperative MMC in both silicone and prolene groups. These results were in agreement with another meta-analysis study performed recently in 2020 (13) which indicated a slightly higher chance of success in En-DCR with silicone tube and intraoperative use of MMC. However, the analysis of the isolated studies revealed a significant difference favoring the use of MMC in just a study involving En-DCR.

Another meta-analysis done in 2014 (14) showed MMC can improve the results of DCR with or without stents. Also meta-analysis study of endoscopic DCRs comparing the clinical results with and without MMC concluded that in addition to being safe, (15) MMC helps reduce the closure rate of the osteotomy and enhance the success rate after both primary and revision En-DCR (15) in addition another study (16) reported in their meta-analysis of primary En-DCR with and without MMC that there was a significantly higher success rate in the MMC group in comparison with the control group. The meta-analysis also found that intraoperative MMC application seems to be a safe adjuvant and helps in maintaining the patency of the ostium.

However, these results do not coincide with that of the study done in (2006) (17) where it was concluded that intraoperative MMC application does not alter the long-term results in endoscopic DCR. They concluded that their result is not statistically significant ( $p > 0.2$ ) and that the intraoperative MMC application does not alter the long-term results in endoscopic DCR. they added that a properly and adequately performed surgery is more vital for successful result. In our study we used a different concentration

of MMC (0.5 mg/ml) and duration of application was 10 minutes. So the results of Ghosh et al (17) may be attributed the lower concentration and duration of application of MMC .

### Conclusion and recommendations

The efficacy, defined as anatomic and functional success, is higher for silicone than Prolene stents with minimal post-operative complications in silicon group. Also the intraoperative use of MMC is safe and improves the success rate of En-DCR significantly.

Although the silicone outcome considered better than prolene, polypropylene is cheaper and it is readily available in all operation theaters. They added that it is a good alternative to silicone stents.

We recommend more studies comparing other types of stent with En-DCR, In addition, we recommend doing these studies on larger scales and longer periods of follow-up.

### References

1. Owji N, Radaei M, Khademi B. The Relationship between Primary Acquired Nasolacrimal Duct Obstruction and Gastroesophageal Reflux. *Curr Eye Res.* 2018 Oct; 43(10): 1239-1243.

2. Weidenbecher M, Hosemann W, Buhr W. Endoscopic endonasal dacryocystorhinostomy: results in 56 patients. *Ann Otol Rhinol laryngol* 1994; 103: 363-7.
3. Hartakinen J, Grenman R, Puukka P, Seppa H. Prospective randomized comparison of external dacryocystorhinostomy and endonasal laser dacryocystorhinostomy. *Ophthalmology* 1998; 105: 1106-13.
4. Smirnov G, Tuomilehto H, Terasvirta M, Nuutinen J, Seppa J. Silicone tubing is not necessary after primary endoscopic dacryocystorhinostomy: a prospective randomized study. *American journal of rhinology*, 2008; 22(2), 214-217.
5. Cheng SM, Feng YF, Xu L, Li Y, Huang JH. Efficacy of mitomycin C in endoscopic dacryocystorhinostomy: A systematic review and meta-analysis. *PLoS One.* Okuyucu 2013; 8:e62737.
6. Ambani K, Suri N, Parmar H. Study of success rate in endoscopic dacryocystorhinostomy with and without stenting. *International Archives of Integrated Medicine*, Vol. 2, Issue 4, April, 2015.
7. Aslan S, Oksuz H, Okuyucu S, Akoglu E, Dagli S. Prolene: a novel, cheap, and effective material in dacryocystorhinostomy. *Acta Otolaryngol.* 2009 Jul;129(7):7559.
8. S, Gorur H, Oksuz H, Akoglu E. Endoscopic Dacryocystorhinostomy with Silicone, Polypropylene, and T-tube Stents; Randomized Controlled Trial of Efficacy and Safety. *American Journal of Rhinology & Allergy.* 2015;29(1):63-68.
9. Vizesi F, Jones C, Lotz N, Gianoutsos M, Walsh WR. Stress relaxation and creep:

- viscoelastic properties of common suture materials used for flexor tendon repair. The Journal of hand surgery, 2008; 33:2 , 241-246.
10. Viswanatha B, Vijayashree MS. Silicone stenting and polypropylene stenting in endoscopic dacryocystorhinostomy: A prospective comparative study. Res. Otolaryngol, 2015; 4, 49-53.
  11. Ugurbas SH, Zilelioglu G, Sargon MF, Anadolu Y, Akiner M, Aktürk T et al. Histopathologic effects of mitomycin-C on endoscopic transnasal dacryocystorhinostomy. Ophthalmic Surg Lasers. 1997; 28:300–4.
  12. Nair AG, Ali MJ. Mitomycin-C in dacryocystorhinostomy: From experimentation to implementation and the road ahead: A review. Indian J Ophthalmol. 2015 Apr; 63(4):335-9.
  13. Sousa T, Schellini SA, Meneghim R, Cataneo A. Intra-Operative Mitomycin-C as Adjuvant Therapy in External and Endonasal Dacryocystorhinostomy: Systematic Review and Meta-Analysis. Ophthalmology and therapy, 2020; 9:2, 305–319.
  14. Qian Z, Zhang Y, Fan X. Clinical outcomes of dacryocystorhinostomy with or without intraoperative use of mitomycin C: a systematic review and meta-analysis. J Ocul Pharmacol Ther 2014 30 615–24.
  15. Cheng SM, Feng YF, Xu L, Li Y, Huang JH. Efficacy of mitomycin C in endoscopic dacryocystorhinostomy: A systematic review and meta-analysis. PLoS One. 2013; 8:e62737.
  16. Feng YF, Yu JG, Shi JL, Huang JH, Sun YL, Zhao YE et al. A meta-analysis of primary external dacryocystorhinostomy with and without mitomycin C. Ophthalmic Epidemiol. 2012; 19:364–70.
  17. Ghosh, Soumitra & Roychoudhury, Amitabha & Roychaudhuri, B. Use of mitomycin C in endo-DCR. Indian journal of otolaryngology and head and neck surgery: official publication of the Association of Otolaryngologists of India. 2006; 58. 368-9. 10.1007.
  18. Pittore B, Tan N, Salis G, Brennan PA, Puxeddu R. Endoscopic transnasal dacryocystorhinostomy without stenting: results in 64 consecutive procedures. Acta otorhinolaryngologica italica 2010; 30:294-298
  19. Kakkar V, Chugh J, Sachdeva S, N Sharma, Ramesh. Endoscopic dacryocystorhinostomy with and without silicone stent. A Comparative Study. The Internet Journal of Otorhinolaryngology. 2008 (9) Number 1.

**To cite this article:** Ahmed F. Allam, Hossam M. Abd Elbaky, Abo Bakr A. Abd El Raouf, Abdel Hakim F. Ghallab, Ramy F. Tantawy, Alaa M. Abd El Samie. Comparative Study of Endonasal Dacryocystorhinostomy with Silicone or Polypropylene Stents Using Mitomycin C. BMFJ 2023;40(surgical issue):129-141.