

Outcome of Arthroscopic Patellar Denervation in Management of Patellofemoral Pain with Normal Patellar Alignment

Magdy M. Ahmad, Mamdouh M. El Karamany, Mohamed S. Singer, Waleed A. Omara

Department of Orthopedic Surgery, Benha faculty of medicine, Benha University, Egypt

Correspondence to: Waleed A. Omara, Department of Orthopedic Surgery, Benha faculty of medicine, Benha University, Egypt.

Email:

waleed.ali21@fmed.bu.edu.eg

Received: 1 June 2022

Accepted: 2 August 2022

Abstract

Background: Patellofemoral pain syndrome (PFPS) is anterior knee pain that is increased by ascending or descending stairs or prolonged sitting with bent knees in absence of significant structural changes. The current study aims to assess the outcome of arthroscopic denervation of the patella using a radiofrequency ablation device in the management of resistant patellofemoral pain in absence of malalignment and patellofemoral maltracking.

Methods: This prospective study was conducted in Orthopedic Surgery department at Benha University hospital on 25 patients with resistant patellofemoral pain syndrome. **Results:** one year Post-operatively, there was high statistically significant improvement in VAS on comparing preoperative ($p < 0.001$). There were no significant changes in pain VAS 6 months postoperatively and at 1year postoperatively ($p > 0.05$). Six

months Post-operatively, there was high statistically significant improvement in Kujala on comparing preoperative ($p < 0.001$). Also, one year Post-operatively, there was high statistically significant improvement in Kujala on comparing preoperative ($p < 0.001$). One year Post-operatively, there was high statistically significant improvement in Lysholm score on comparing preoperative ($p < 0.001$). There were no significant changes in Lysholm score 6 months postoperatively and at 1year postoperatively ($p > 0.05$). Complications were found in eleven cases in our study, nine cases complicated by quadriceps muscle atrophy, one case with DVT and one case had anterosuperomedial (ASM) portal synovial sinus. **Conclusion:** Arthroscopic patellar denervation is a simple procedure that yields good results, improved patient satisfaction, and leads to non-significant complications in the management of resistant patellofemoral pain syndrome.

Key words: Arthroscopic Patellar Denervation; Outcome; Patellofemoral Pain; Normal Patellar Alignment

Introduction

Patellofemoral pain syndrome (PFPS) is anterior knee pain that is increased by ascending or descending stairs or prolonged sitting with bent knees in absence of significant structural changes. It is common in females as well as young active adults ⁽¹⁾.

Anatomic factors such as increased pelvic width and resulting in excessive lateral thrust on the patella, and postural and sociological factors such as wearing high heels and sitting with legs adducted can influence the incidence and severity of this condition in women ⁽²⁾.

Conservative treatment is the first choice for dealing with unspecified patellofemoral pain. Traditionally, conservative management of patellofemoral pain involved pain-relieving techniques and standard quadriceps strengthening in non-weight-bearing positions. Only, if a careful long-term physical therapy program has failed, one might consider surgery ⁽³⁾.

Pain treatment by denervation is not a new concept. The objective would be to interrupt the neural pathways that transmit the pain message. It has been applied with good clinical results in trigeminal neuralgia and in some cases of intractable wrist pain ⁽⁴⁾. In advanced patellofemoral arthritis, patellofemoral

resurfacing is an option alone or concomitant with a total knee replacement. Many studies, however, showed better results with circumpatellar electrocautery denervation ⁽⁵⁾.

Based on this rich peripatellar distribution of pain receptors ⁽⁶⁾, the objective of this technique is to produce a simple thermal lesion to the peripatellar soft tissue in the region closest to the patella, to obliterate a considerable number of nociceptive receptors. Since *Vegas et al* published their series with good results, not much similar case series ⁽⁷⁾.

Arthroscopic patellofemoral denervation treatment can relieve and improve the symptoms and achieve the goal of treatment ⁽⁸⁾.

The current study aimed to assess the outcome of arthroscopic denervation of the patella using a radiofrequency ablation device in the management of resistant patellofemoral pain in the absence of malalignment or patellofemoral maltracking.

Patients and Methods

Patients

From January 2017 to December 2020, we performed a prospective observational study (Cohort Study) on the arthroscopic patellar denervation

technique to evaluate its early results. Twenty-five patients with resistant patellofemoral pain syndrome were included in our study and were performed at Benha university hospital.

Informed consent was obtained from the patients or their relatives if they are incapable of giving consent.

Inclusion criteria

- Age: 20-60 years
- Failed conservative treatment for at least 6 months

Exclusion criteria

Any patient with one or more of the following criteria was excluded from this study:

- Advanced knee or patellofemoral OA (Outerbridge grade 3 or 4).
- Lower limb malalignment
- Patellofemoral instability
- Associated knee meniscal or ligamentous injuries requiring repair

Preoperative assessment

Patients demographics

Patients' age, gender, BMI and side affected are all recorded.

History:

Detailed clinical history was taken for:

- History of trauma or patellar dislocation.
- Duration of symptoms and previous modalities of treatment including previous surgeries.

- Well-constructed physiotherapy protocol for at least 6 months.
- Any other complaints rather than anterior knee pain.
- All patients were assessed clinically by:
 - 1- Visual analog scale (VAS)
 - 2- Lysholm knee score
 - 3- Kujala Score (Anterior Knee Pain Scale)

Clinical examination

In our study, clinical examination is the main cornerstone in assessing the patient with the aid of radiological examination, not the opposite. So, we examine the whole lower limb carefully in a standardized manner and test for all patients including attention to the spine if the patient complaint suggests it.

Radiological assessment:

Standard knee plain X-ray views (AP standing, lateral & skyline) recording:

- Arthritic changes in tibiofemoral and patellofemoral joints.
- Anatomical tibiofemoral angle.
- Patellar height using Caton Deschamps index.

MRI of the knee for:

- Chondral, meniscal and ligaments injuries are noted
- Patellar tilt using patellofemoral angle (figure 1).

- Trochlear dysplasia using trochlear groove angle (figure 2).

Surgical technique

- All procedures were performed under spinal anesthesia as a day case surgery.
- A 4.5 mm 30° scope is used for cases.
- With the patient in a supine position, a tourniquet is applied for hemostasis and a lateral post is applied for extremity control. The knee is placed at the end of the operating table with the leg hanged free.
- The extremity is cleansed and draped in a sterile fashion (figure 3).
- The knee landmarks (patella, patellar tendon, and tibial platform) are identified.
- The anterolateral portal is made using a no. 11 scalpel with the blade upwards (figure 4).
- Anteromedial portal is opened under direct vision with scalpel no. 11.
- Knee diagnostic arthroscopy is performed using the standard
- The arthroscope is switched to the anteromedial portal while vapor is introduced from the anterolateral superomedial portal under direct vision with aid of spinal needle guidance

- Patellar malalignment using patellar subluxation distance.

anterolateral and anteromedial portals. Visualizing from the anterolateral portal we begin watching and probing structures of tibiofemoral articulation; ACL, PCL, menisci and articular cartilage.

- The arthroscope then gets switched under the patella to examine the patellofemoral joint. We watch patellar tracking through ROM and then palpate the articular surfaces of the patella and trochlea for chondromalacia (figure 5).
- All the intra-articular lesions identified are recorded in the operative notes.
- With the knee extended, we introduce an arthroscopic vapor from the anteromedial portal to begin cauterizing the tissues just medial to the patella, while on coagulation mode in an intermittent fashion to avoid elevating the irrigation solution temperature (figure 6).
portal to cauterize the tissues just lateral to the patella (figure 7).
- The arthroscope is returned to the anterolateral portal and we open (figure 8). We prefer it over the superolateral portal because the post

prevents adequate manipulation of the vaper.

- We finally cauterize the tissues just superior to the patella from the superomedial portal in the same manner (figure 9).
- At that time the soft tissue surrounding the patella is cauterized except for the patellar tendon attachment to avoid interrupting its blood supply causing osteonecrosis.
- We close the superomedial portal with a simple stitch and leave the standard portals without closure.
- Dressing the knee with an elastic bandage lightly without drains

Statistical analysis

Data were collected, coded then entered as a spreadsheet using Microsoft Excel 2016 for Windows, of the Microsoft Office bundle; 2016 of Microsoft Corporation, United States. Data were analyzed using IBM Statistical Package for Social Sciences software (SPSS), (IBM SPSS Statistics for Windows, Version 26.0. Armonk, NY: IBM Corp). The Kolmogorov-Smirnov test was used to verify the normality of distribution. Continuous data were expressed as mean \pm

standard deviation, median & IQR while categorical data as numbers and percentages. Paired student t-test; used for comparison between two related samples in normally distributed data. Wilcoxon rank test was used to assess the statistical significance of the difference of a non - parametric variable between two related samples A statistical value <0.05 was considered significant.

Results

Demographic data

1- Age:

The age of the studied patients ranged from 23 to 48 years with a mean age was 35.76 ± 8.0 years (**table 1**).

2- Gender:

There were 7 (28.0%) males and 18 (72.0%) females with a male to female ratio of 0.39:1 (**table 1**).

3- Body mass index (BMI):

BMI of the studied patients ranged from 17 to 28.4 Kg/m^2 with a mean of $23.7 \pm 3.11 \text{ Kg/m}^2$ (**table 1**)

4- Side:

Fourteen (56.0%) patients had lesion in right side while 11 (44%) in the left side (**table 1**).

Arthroscopic findings (table 2).

1-Chondromalacia:

Seventy-two per cent of cases had Chondromalacia grade 1 (G1) and 20% of cases had Chondromalacia

Follow up period:

The period of follow up ranged from 12 to 18 months with the meantime being 14.12 ± 2.03 months (**table 3**).

Complication:

Complications were found in

Visual analogue scale (VAS)

1- Preoperative:

Preoperative VAS ranged from 70 to 95 with a mean value of 81.64 ± 6.32 (**table 4**).

2- Postoperative at 6 months:

5.88 ± 19.16 (**table 4**).

➤ Comparison between pre-operative & post-operative VAS

Six months Post-operatively, there was high statistically **significant** improvement in pain VAS on

grade 2 (G2).

2-Others:

It was noticed that one case had flap tear of the medial meniscus (MM), one case had medial plica, one case had medial femoral condyle (MFC) chondromalacia grade (G1), one case had MFC chondromalacia grade (G2), one case had MM horizontal tear and one case had MFC ulcer.

eleven cases in our study, nine cases complicated by quadriceps muscle atrophy, one case with DVT and one case had anterosuperomedial (ASM) portal synovial sinus (**table 3**).

VAS score at 6 months-postoperative ranged from 0 to 97 with a mean value of 6.20 ± 19.0 (**table 4**).

3- Postoperative at one year:

VAS score at 1 year- postoperative ranged from 0 to 97 with a mean value of

comparing preoperative ($p < 0.001$). Also, one year Post-operatively, there was high statistically **significant** improvement in VAS on comparing preoperative ($p < 0.001$). There were no significant changes in pain VAS 6

months postoperatively and at 1 year postoperatively ($p>0.05$) (**table 4**).

Kujala score

1- Preoperative:

Preoperative Kujala ranged from 52 to 83 with a mean value of 61.24 ± 8.53 (**table 5**).

2- Postoperative at 6 months:

Kujala score at 6 months-postoperative ranged from 76 to 100 with a mean value of 95.72 ± 5.91 (**table 5**).

3- Postoperative at one year:

Kujala score at 1 year of postoperative ranged from 76 to 100 with a mean value of 95.88 ± 5.86

Lysholm score

1- Preoperative:

Preoperative Lysholm ranged from 60 to 82 with mean value of 65.96 ± 6.74 (**table 6**).

2- Postoperative at 6 months:

Lysholm score at 6 months-postoperative ranged from 80 to 99 with mean value of 95.72 ± 5.77 (**table 6**).

3- Postoperative at one year:

Lysholm score at 1 year- postoperative ranged from 76 to 100 with mean value of 95.36 ± 5.77 (**table 6**).

(**table 5**).

➤ Comparison between pre-operative & post-operative Kujala

Six months Post-operatively, there was high statistically **significant** improvement in Kujala on comparing preoperative ($p<0.001$). Also, one year Post-operatively, there was high statistically **significant** improvement in Kujala on comparing preoperative ($p<0.001$). There were no significant changes in Kujala score 6 months postoperatively and at 1 year postoperatively ($p>0.05$) (**table 5**).

➤ Comparison between pre-operative & post-operative Lysholm

Six months Post-operatively, there was high statistically **significant** improvement in Lysholm score on comparing preoperative ($p<0.001$). Also, one year Post-operatively, there was high statistically **significant** improvement in Lysholm score on comparing preoperative ($p<0.001$). There were no significant changes in Lysholm score 6 months postoperatively and at 1 year postoperatively ($p>0.05$) (**table 6**).

Post-operative follow-up X-ray at 1-year: (table 7)

1-Arthritic changes:

Radiographic evaluation at the final follow-up showed no arthritic changes.

2-Patellar malalignment:

Radiographic evaluation at the final follow-up showed no patellar malalignment.

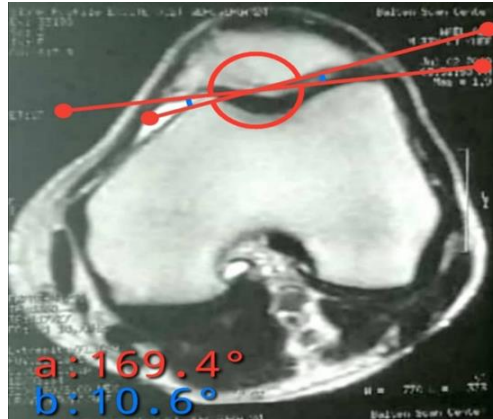


Figure 1: Coronal MRI of the left knee showing patellofemoral angle (blue b).

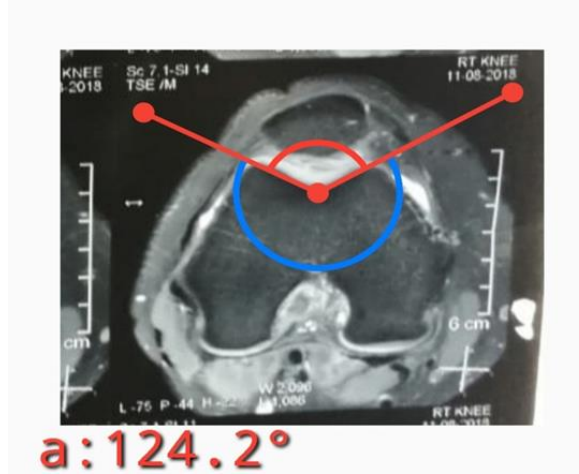


Figure 2: Coronal MRI showing Trochlear groove angle (red a).



Figure 3: Position of the knee after sterilization and draping.

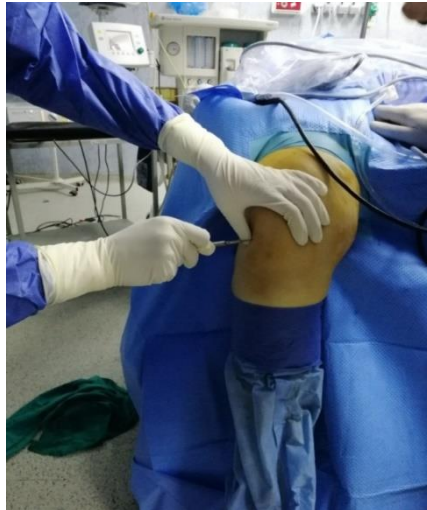

Figure 4: Beginning of the procedure with doing the anterolateral portal.

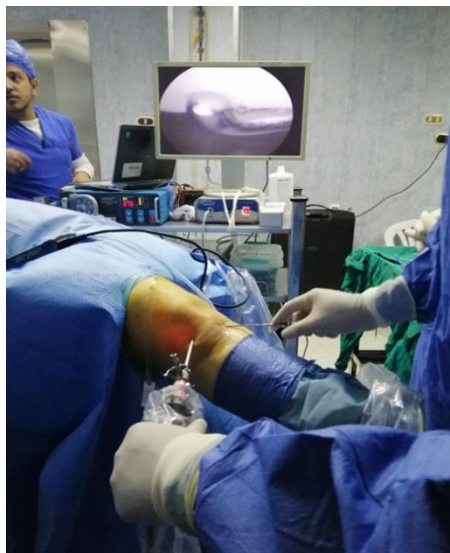

Figure 5: Probing the undersurface of patella revealing chondromalacia grade 1.

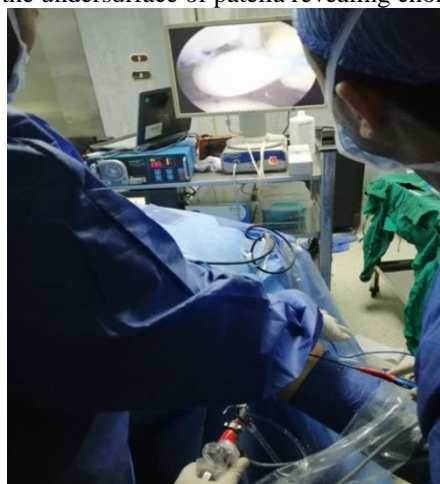

Figure 6: An arthroscopic vapor in the anteromedial portal of the right knee to cauterize the medial soft tissue with an assistant pushing the patella inferolateral.

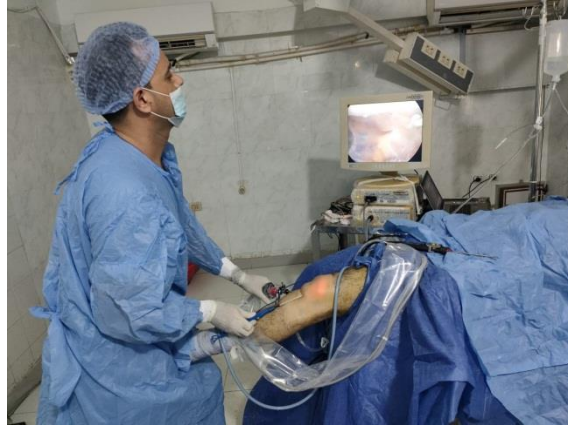

Figure 7: Switching scope to the anteromedial portal working from the lateral portal to cauterize the lateral soft tissue in the left knee.

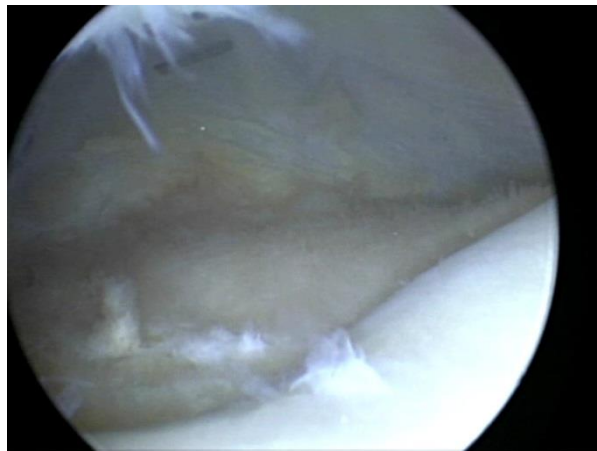


Figure 8: Spinal needle guides the superomedial portal to assure good access to the superior patella.

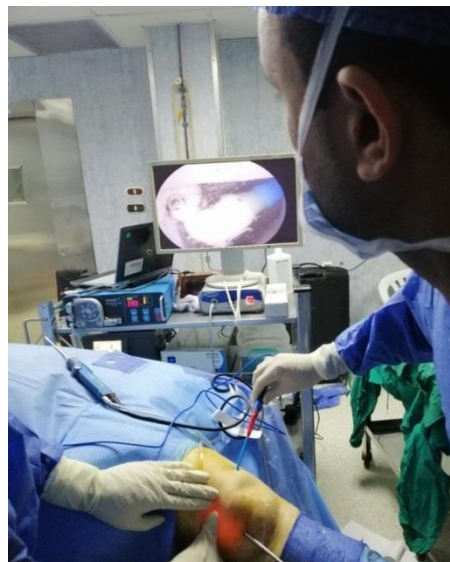

Figure 9: Cauterizing the superior soft tissue through the superomedial portal.

Table (1): Distribution of patients regarding demographic data

Demographic data	Studied patients (n = 25)	
	No.	%
Age (years):		
Range	23.0 – 48.0	
Mean± SD	35.76±8.0	
Median	37.0	
Gender:		
Male	7	28.0%
Female	18	72.0%
BMI (Kg/m²):		
Range	14.0 – 28.4	
Mean± SD	23.7±3.11	
Median	23.9	
Side:		
Right	14	56.0%
Left	11	44.0%

Table (2): Distribution of patients regarding arthroscopic findings

Arthroscopic findings	Studied patients (n = 25)	
	No.	%
Chondromalacia:		
No	2	8.0%
G1	18	72.0%
G2	5	20.0%
Others:		
No	19	76.0%
Flap tear MM	1	4.0%
Medial plica	1	4.0%
MFC chondromalacia G 1	1	4.0%
MFC chondromalacia G 2	1	4.0%
MM horizontal tear	1	4.0%
MFC ulcer	1	4.0%

Table (3): Distribution of patients regarding follow up period and complications

	Studied patients (n = 25)	
	No.	%
Follow up period (months)		
Range	12.0 – 18.0	
Mean± SD	14.12± 2.03	
Median	14.0	
Complications		
No	14	56.0%
ASM portal synovial sinus	1	4.0%
DVT	1	4.0%
Quadriiceps muscle atrophy	9	36.0%

Table (4): Comparison between pre-operative and post-operative VAS

	Preoperative	Postoperative (6months)	Postoperative (1 year)	Friedman's Two-Way Analysis of Variance	
				Test value	P-value
VAS Range	70.0 – 95.0	0.0 – 97.0	0.0 – 97.0		<0.001
Mean± SD	81.64± 6.32	6.20± 19.0	5.88± 19.16	35.04	P1<0.001
Median	80.0	2.0	1.0		P2<0.001 P3=0.707

p≤0.05 is considered statistically significant, p≤0.01 is considered high statistically significant, SD= standard deviation, P1: preoperative Vs 6months postoperative, P2: preoperative Vs 1 year postoperative, P3: 6months postoperative Vs 1 year postoperative

Table (5): Comparison between pre-operative and post-operative Kujala

	Preoperative	Postoperative (6months)	Postoperative (1 year)	Friedman's Two-Way Analysis of Variance	
				Test value	P-value
Kujala Range	52.0 – 83.0	76.0 – 100.0	76.0 – 100.0		<0.001
Mean± SD	61.24± 8.53	95.72± 5.91	95.88± 5.86	40.96	P1<0.001
Median	60.0	98.0	97.0		P2<0.001 P3=0.671

p≤0.05 is considered statistically significant, p≤0.01 is considered high statistically significant, SD= standard deviation, P1: preoperative Vs 6months postoperative, P2: preoperative Vs 1 year postoperative, P3: 6months postoperative Vs 1 year postoperative

Table (6): Comparison between pre-operative and post-operative Lysholm

	Preoperative	Postoperative (6months)	Postoperative (1 year)	Friedman's Two-Way Analysis of Variance	
				Test value	P-value
Range	60.0 – 82.0	80.0 – 99.0	76.0 – 100.0		<0.001
Mean± SD	65.96± 6.74	95.72± 5.77	95.36± 5.77	42.64	P1<0.001
Median	60.0	97.0	97.0		P2<0.001 P3=0.808

p≤0.05 is considered statistically significant, p≤0.01 is considered high statistically significant, SD = standard deviation, P1: preoperative Vs 6months postoperative, P2: preoperative Vs 1 year postoperative, P3: 6months postoperative Vs 1 year postoperative

Table (7): Distribution of patients regarding post-operative X-ray at 1-year

X-ray at 1-year	Studied patients (n = 25)	
	No.	%
Arthritic changes:		
No	25	100.0%
Yes	0	0.0%
Patellar malalignment:		
No	25	100.0%
Yes	0	0.0%

Discussion

As regards demographic data of the studied group, we found that the age ranged from 23 to 48 years with a mean age was 35.76 ± 8.0 years, there were 7 (28.0%) males and 18 (72.0%) females, with a mean of 23.7 ± 3.11 Kg/m², ranged from 17 to 28.4 Kg/m². Fourteen (56.0%) patients had a lesion in the right side while 11 (44%) in the left side.

An early study used for the first time, the arthroscopic denervation technique for the treatment of patients with patellofemoral pain, they enrolled ten patients with patellofemoral pain with no evident malalignment (8 women, 2 men; mean age 33 years) were treated by arthroscopic patellar denervation, involving a thermal lesion to the peripatellar soft tissue⁽⁹⁾.

Furthermore, another study evaluated the effect of arthroscopic patellar denervation in patients with combined tibiofemoral and patellofemoral OA after malalignment correction. They studied 45 patients [females/males, 27/18; age, 30–59 years (45.5 ± 8.50); mean body mass index, 25.15 ± 3.04 kg/m²] the cases were divided into 2 groups with and without denervation: group A included 22 patients who underwent open-wedge

high tibial osteotomy and arthroscopic denervation and group B included 23 patients who underwent open-wedge high tibial osteotomy without denervation⁽¹⁰⁾.

In the current study, we found that 72% of cases had chondromalacia grade 1 and 20% cases had chondromalacia grade 2, also it was noticed that one case had flap tear posterior horn medial meniscus, one case had medial plica, one case had MFC chondromalacia grade 1, one case had MFC chondromalacia grade 2, one case had MFC ulcer and one case had medial meniscus horizontal tear.

A study reported that the majority 20/32 of the studied group were grade 1 lesion and the rest of the cases (12/32) were of grade 0 (normal) according to the Outerbridge classification system. The study did not report the other tests like ours⁽¹¹⁾.

Another study found that there were 12 cases had MRI signs of patellar chondral damage. Twelve patients had arthroscopic findings of grade 1 to 3 patellar chondromalacia, whereas three patients had full-thickness cartilage defects (grade 4).⁽¹²⁾

As regards VAS score pre- and post-operative values, we found that preoperative VAS ranged from 70 to 95 with a mean value of 81.64 ± 6.32 . VAS score and at 6 months postoperative ranged from 0 to 6 with a mean value of 2.48 ± 1.78 . VAS score at 1 year postoperative ranged from 0 to 8 with a mean value of 1.72 ± 2.03 . So, we found that 6 months postoperatively, there was high statistically significant improvement in pain VAS on comparing preoperative ($p < 0.001$). Also, one year post-operatively, there was high statistically significant improvement in VAS compared to preoperative ($p < 0.001$). There were no significant changes in pain VAS 6 months postoperatively and at 1 year postoperatively ($p > 0.05$).

While the study by *Vega et al.* reported that arthroscopic patellar denervation decreases pain sensitivity in the anterior region of the knee and is effective in this patient population. Functional improvement was obtained in all cases. Six months after the procedure, all patients had resumed their normal daily activity and the younger patients were able to practice sports without difficulty⁽¹³⁾.

However, *Vega et al.*, reported that six months after surgery, according to assessment using the Grana scale (Grana

assessment of patellofemoral pain), 7 patients were in category A, 2 in category B and 1 in category C. Therefore, the clinical result was satisfactory in 9 patients and unsatisfactory in 1 patient (the oldest). All patients reported a marked improvement, they had all returned to their normal activities without any pain. Only the oldest patient, reported pain that did not limit his daily living activities. The 5 youngest patients sporadically practiced sports and did not suffer limitations or pain when doing so. On physical examination, there was no pain when patellar mobilization maneuvers were performed, except in the 2 oldest patients who still had some discomfort.⁽¹³⁾

In agreement with our results, the study done in 2020 reported that at the final follow-up, the postoperative pain VAS improved from 7.4 (range, 5–9) preoperatively to 2.3. There was a highly significant improvement in the VAS score ($p < .0001$)⁽¹¹⁾.

Our results were supported by the study that reported that Werner's anterior knee pain score improved from 29.56 (17–37) to 44.7 (32–50) at 6 months ($P < 0.05$). No significant improvement was seen in after 6 months. Excellent results were obtained in all patients except those who had excessive femoral anteversion

and/ or full-thickness cartilage defect of the patella (7 patients). Five patients with excessive femoral anteversion also had inward-looking patellae. The average Werner score of these 7 patients improved from 25.42 (17–32) to 37.42 (32–38) Kujala score also improved only moderately in these patients from 50.85 (45–62) to 79.8 (76–84). Two patients with the least improvement had a constellation of excessive femoral anteversion, inward-looking patellae, and grade 4 cartilage defect of the patella⁽¹²⁾.

As regards Kujala score among the studied patients, we found that preoperative Kujala ranged from 52 to 83 with a mean value of 61.24 ± 8.53 , at 6 months- postoperative ranged from 76 to 100 with a mean value of 95.72 ± 5.91 and at 1 year- postoperative ranged from 76 to 100 with a mean value of 95.88 ± 5.86 . Comparison between pre-operative & post-operative VAS revealed that 6 months postoperatively, there was high statistically significant improvement in Kujala on comparing preoperative ($p < 0.001$). Also, one year post-operatively, there was high statistically significant improvement in Kujala on comparing preoperative ($p < 0.001$). There were no significant changes in Kujala score 6 months postoperatively and at 1 year postoperatively ($p > 0.05$).

Our results are supported by the study of *Vega et al* who have analyzed a subgroup of 13 patients with a maximum follow-up of 5 years that has chondromalacia grade 1 to 2 according to the Outerbridge classification. The Kujala score improved from a mean of 72 (52–84) preoperatively to 97 (76–100) after a 2-year follow-up and 94 (69–100) after a 5-year follow-up.⁽¹³⁾

In agreement with our results, the study done 2020 reported that at the final follow-up the Kujala score improved significantly from 70.75 (range, 62–81) to 88.5 (range, 81–96) ($P < 0.0001$). There were no significant changes in Kujala score 6 months postoperatively and at the final follow-up ($P > 0.05$)⁽¹¹⁾.

Also, our results were supported by *Jain et al.*, who reported that the Kujala score was improved from 70.4 (45–84) preoperatively to 93.3 (75–100) at 6 months ($P < 0.05$)⁽¹²⁾.

In agreement with our results the study by performed in 2020 reported that at the final follow-up the postoperative Lysholm score improved from 63.5 (range, 56–71) to 90.5 (range, 86–95). There was a highly significant improvement in the Lysholm score ($p < 0.0001$). There were no significant changes in Lysholm scores 6 months postoperatively and at the final follow-up ($p > 0.05$).⁽¹¹⁾

Conclusion

Arthroscopic patellar denervation is a simple procedure that yields good results, improved patient satisfaction, and leads to non-significant complications in the management of resistant patellofemoral pain syndrome.

References

1. J.Fulkerson, E. Arendt, Anterior knee pain in females. *Clin Orthop*.vol.372,PP.69-73,2000.
2. B.Goldberg, Chronic anterior knee pain in the adolescent. *Pediatr Ann*.vol.20,pp.186-193,1991.
3. E.Rodriguez-Merchan, Evidence-based conservative management of the patellofemoral syndrome. *Arch Bone Jt Surg*.vol.2(1),pp.4-6,2014.
4. J.Pirola, W.Le, J.Yao, Effect of electrothermal treatment on nerve tissue within the triangular fibrocartilage complex, scapholunate, and lunotriquetral interosseous ligaments.*Arthroscopy*.vol.32(5),pp.773-8,2016.
5. MA.Altaya, C.Ertürka, N.Altayb, R.Akmese, U.Isikana, Patellar denervation in total knee arthroplasty without patellar resurfacing: A prospective, randomized controlled study. *Orthopaedics & Traumatology: Surgery & Research*.vol.98,pp.421-5,2012.
6. D.Witonski, M.Wagrowska-Danielewicz, Distribution of substance-P nerve fibres in the knee joint in patients with anterior knee pain syndrome. *Knee Surg Sports Traumatol Arthrosc*.vol.7,pp.177– 83,1999.
7. J.Vega, J.Marimón, P.Golanó. Patellofemoral pain. Treatment by arthroscopic patellar denervation. *Rev Ortop Traumatol*.vol.52,pp.290-294,2008.
8. J.Tao, P.Chen, J.Chen, L.Xie, L.Liu, Y.Yang, HM.Guo, Arthroscopic patellofemoral denervation in the treatment of severe patellofemoral arthritis. *Biomed Res*.vol.29(4),pp.732–735,2018
9. J.Vega, P.Golano, L.Pérez-Carro, Electrosurgical arthroscopic patellar denervation. *Arthroscopy*.vol.22(9),pp. e1-1028.e3,2006.
- 10.MK.Said, HG.Said, H.Elkady, MK.Said, IK.Ramadan, MA.EL-Radi, Does arthroscopic patellar denervation with high tibial osteotomy improve anterior knee pain? *Journal of Experimental Orthopaedics*.vol.8(1),pp.1-4,2021.
- 11.MS.Singer, AM.Halawa, The outcome of arthroscopic radiofrequency denervation of the patella in the management of resistant patellofemoral pain syndrome. *The Egyptian Orthopaedic Journal*.vol.55(3),pp.127,2020.
- 12.JK.Jain, MC.Bansal, R.Upadhyay, A.Sharma, A.Chandra, SP.Siddharath , Arthroscopic patellar denervation for patellofemoral (anterior knee pain) in young patients: Indications and outcome. *Saudi Journal of Sports Medicine*.vol.19(3),pp.92,2019.
- 13.J.Vega, P.Golanó, V.Sanchis-Alfonso, Arthroscopic patellar denervation for anterior knee pain. In *anterior knee pain and patellar instability*. Springer, London,pp.373-378,2011.

to cite this article: Magdy M. Ahmad, Mamdouh M. El Karamany, Mohamed S. Singer, Waleed A. Omara Outcome of Arthroscopic Patellar Denervation in management of Patellofemoral Pain with Normal Patellar Alignment. *BMFJ* 2023;40(surgical issue):96-111.

